



TESTICULAR ATROPHY IN COLUMBIAN BLACK-TAILED DEER IN CALIFORNIA

Authors: DeMARTINI, JAMES C., and CONNOLLY, GUY E.

Source: Journal of Wildlife Diseases, 11(1) : 101-106

Published By: Wildlife Disease Association

URL: <https://doi.org/10.7589/0090-3558-11.1.101>

BioOne Complete (complete.BioOne.org) is a full-text database of 200 subscribed and open-access titles in the biological, ecological, and environmental sciences published by nonprofit societies, associations, museums, institutions, and presses.

Your use of this PDF, the BioOne Complete website, and all posted and associated content indicates your acceptance of BioOne's Terms of Use, available at www.bioone.org/terms-of-use.

Usage of BioOne Complete content is strictly limited to personal, educational, and non - commercial use. Commercial inquiries or rights and permissions requests should be directed to the individual publisher as copyright holder.

BioOne sees sustainable scholarly publishing as an inherently collaborative enterprise connecting authors, nonprofit publishers, academic institutions, research libraries, and research funders in the common goal of maximizing access to critical research.

TESTICULAR ATROPHY IN COLUMBIAN BLACK-TAILED DEER IN CALIFORNIA

JAMES C. DeMARTINI, Wild Animal Disease Center and Department of Pathology, College of Veterinary Medicine and Biomedical Sciences, Colorado State University, Fort Collins, Colorado, 80523, U.S.A.

GUY E. CONNOLLY, Hopland Field Station, University of California, Hopland, California, 95449, U.S.A.

Abstract: During an 18-year period, 4.1% (34/831) of male deer (*Odocoileus hemionus columbianus*) killed on a field station during the autumn hunting season had velvet-covered, often misshapen antlers, and at least two deer had testicular atrophy (gonads from most deer were not available for examination). Testes from six similarly affected deer and several normal deer were compared histologically. Lesions ranged from hypocellularity of the seminiferous tubules and relative hyperplasia or degeneration of interstitial cells to complete connective tissue replacement of the testicular parenchyma. Chronic vascular changes were present in several testes. The etiology and pathogenesis of the lesions were not determined.

INTRODUCTION

Testicular atrophy, usually associated with antler anomalies, has been described in white-tailed deer in Texas^{8,9,10} and in a mule deer in Colorado.⁵ The antler anomalies consist of abnormal conformation and retention of the velvet, a specialized skin which covers the antlers during their growth. The velvet is normally desquamated by the autumn period of heightened sexual activity. The relationship between antler growth, development, and shedding and testosterone levels has been described.¹²

The testicular lesions have been characterized as tubular atrophy with aspermatogenesis and a decrease⁷ or hyperplasia⁹ of interstitial cells. Focal eosinophilia and plasma cell infiltration were reported in one case, although the etiology of the condition was not discovered.⁸

Three cases of testicular hypoplasia were characterized by lack of development of seminiferous epithelium and prominence of interstitial cells.⁵ Abnormalities of the antlers were not present in these cases.

MATERIALS AND METHODS

Cases included in this report were all part of the resident deer population on the 1200 ha University of California field station at Hopland in the north coastal region of California. Between 1955 and 1973, records were kept of the numbers and condition of bucks taken each autumn during the hunting season. Testes from two bucks killed by hunters and four other bucks with velvet-covered, misshapen antlers were examined grossly and fixed in buffered neutral formalin or formol-Zenker's solution, sectioned at 6 μ m, and stained with hematoxylin and eosin, Periodic acid-Schiff's (PAS), oil-red-O, or Perl's iron techniques. One animal was necropsied. For comparative purposes, testes were also collected from immature and adult normal bucks during various seasons of the year.

Clinical History

Between 1955 and 1973, 34/831 (4.1%) of the bucks killed in August and September of each year by hunters on the Hopland field station had velvet-

covered antlers, which were often misshapen with spurious points. Velvet is normally shed from the antlers during late July or early August in this area. The mean number of affected animals each year was 1.8 (range 0-4) while the mean number of bucks taken on the station each year was 47 (range 17-63). Five captive bucks on the field station developed the same condition, and several of these were known to have been normal until 2 to 4 years of age, when the syndrome first appeared. Most of the affected animals lacked secondary sex characteristics, such as a thick neck, and one deer had prominent teat development. Generally, the deer were normal in weight and body condition, although one had an abscess of a jaw and another had otitis externa.

The owner of a ranch about 11 km from the field station reported that only

two "stags" (deer with misshapen velvet-covered antlers) were seen during the 30 years prior to 1967, when a large wildfire occurred on the ranch. Between 1968 and 1972, about one third to one-half of the bucks killed each year (about 20) had been "stags". The fire had been controlled by aerial tankers using retardants (Firetrole 100, Arizona Agrochemical Corporation, P.O. Box 2191, Phoenix, Arizona 85001; and Phos-check 202, Monsanto Company, 6670 East Flotilla Street, Los Angeles, California 90022). Following the fire, 152 ha were seeded with a mixture of harding grass, milo, pubescent wheat grass, blando bromegrass, and perennial ryegrass at 1.8 kg/ha. To control brush, the area was sprayed by air at 47 l/ha the following spring with a mixture of 4.4 kg of 2,4-D, 2.2 kg of 2,4,5-T, and 1.9 l of diesel oil diluted with water to 19 l.

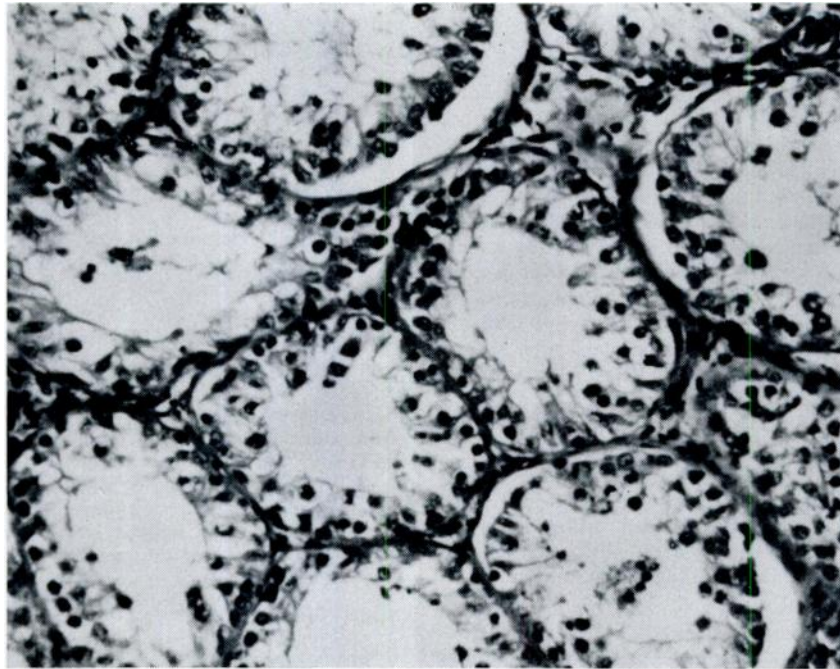


FIGURE 1. Testis from normal deer taken during the spring period of sexual inactivity. Seminiferous tubules are small and relatively hypocellular. H&E, X250.

Gross Findings

Compared with testes removed from normal bucks killed at the same time of the year (20-35 g each), testes from all velvet-antlered deer were bilaterally markedly diminished in weight (2-6 g each). The testicular parenchyma of these animals was much reduced in size in relation to the epididymis. The parenchyma of affected testes was quite firm and yellow-brown on cut surface.

Completed necropsy examination of one velvet-antlered buck failed to reveal additional significant gross or microscopic lesions in organs other than the gonads.

Histopathology

The most prominent histological feature of atrophic testes was the decrease in size and number of seminiferous tubules with loss of spermatogonia and

spermatocytes. Tubules were of variable size, often containing only sertoli cells and were usually surrounded by thickened PAS-positive basement membranes. Occasionally, tubules contained calcified debris. In two animals there was complete connective tissue replacement of the testicular parenchyma with no remnants of tubules or interstitial cells. A testis of another animal had an organizing infarct. Very few inflammatory cells were present in most testes, although occasional mononuclear cells contained PAS-positive brown granular pigment (lipofuscin) and rare macrophages containing iron-positive golden granular pigment (hemosiderin) were observed.

The epididymes of the atrophic testes were inevitably aspermic. The lumens of the tubules were usually shrunken, and there was often peritubular smooth muscle hyperplasia. A focal area of lymphocyte infiltration with germinal center formation was found in one testis.

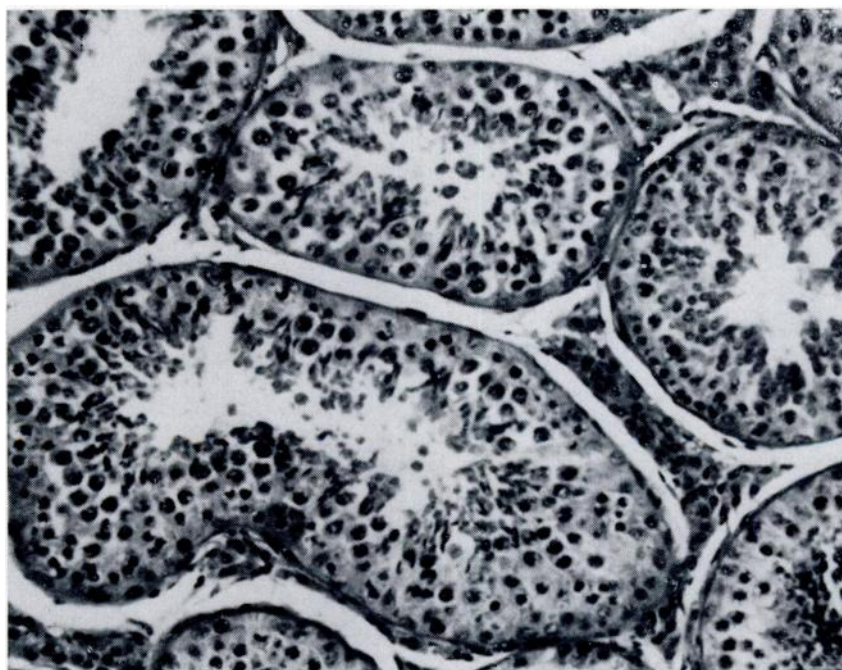


FIGURE 2. Testis from normal deer taken during the fall "rut". Seminiferous tubules are enlarged, and there is active spermatogenesis. H&E, X250.

Interstitial cells were numerous in testes of two deer, few in one deer, and absent in three deer. Where present, they had foamy cytoplasm (Figure 3) which contained oil red O-positive droplets. In order to determine whether the hyperplasia in the two deer was relative or absolute, the numbers of interstitial cells in 70 high power fields (HPF) were determined in atrophic and normal testes. The average number in atrophic testes was 50 interstitial cells/HPF, whereas in normal testes the average was 13 cells/HPF. Since the weight, and presumably the volume, of atrophic testes was only one-fifth to one-tenth of normal testes, the hyperplasia was judged to be relative.

In the testicular parenchyma of three animals, there were occasional arterioles with intimal thickening and endothelial cell proliferation (Figure 4). Rare ves-

sels had a perivascular mononuclear cell infiltration. Arteriolar walls were markedly thickened in the testes of one buck. Such lesions were not found in arterioles of the pampiniform plexus of any of the animals.

DISCUSSION

In studies of the antler cycle in white-tailed deer, Wislocki showed that rising testosterone levels during the summer months correlated with cessation of antler growth and shedding of velvet and that these events did not occur in experimentally castrated deer.¹² Antler abnormalities similar to castrated deer and the lack of masculinization during the rut suggest deficiency or inhibition of testosterone activity in the deer of this study. This correlates with absolute or

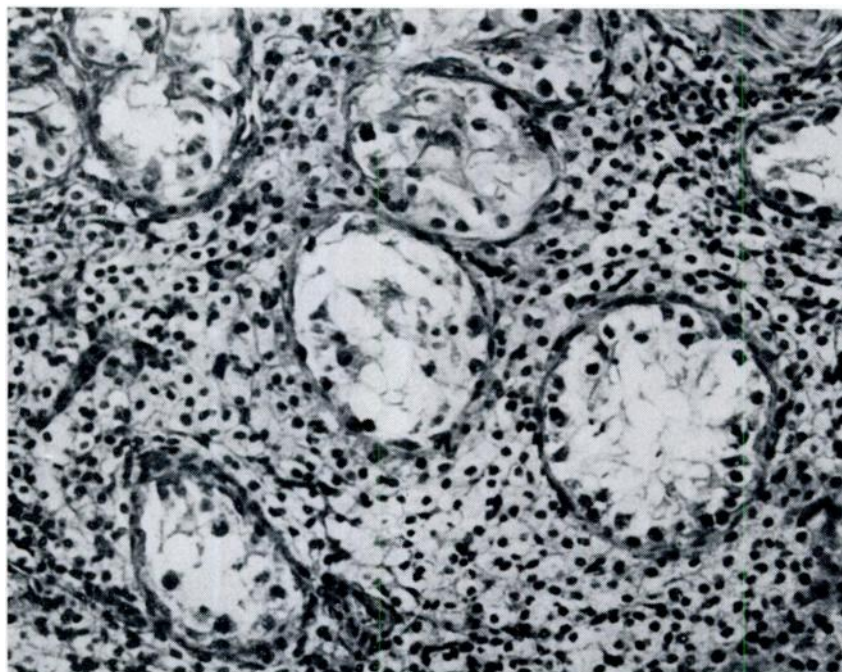


FIGURE 3. Testis from deer with testicular atrophy taken during the fall "rut". Seminiferous tubules are small and hypocellular with only Sertoli cells remaining. Interstitial cells are vacuolated and relatively hyperplastic. H&E, X250.

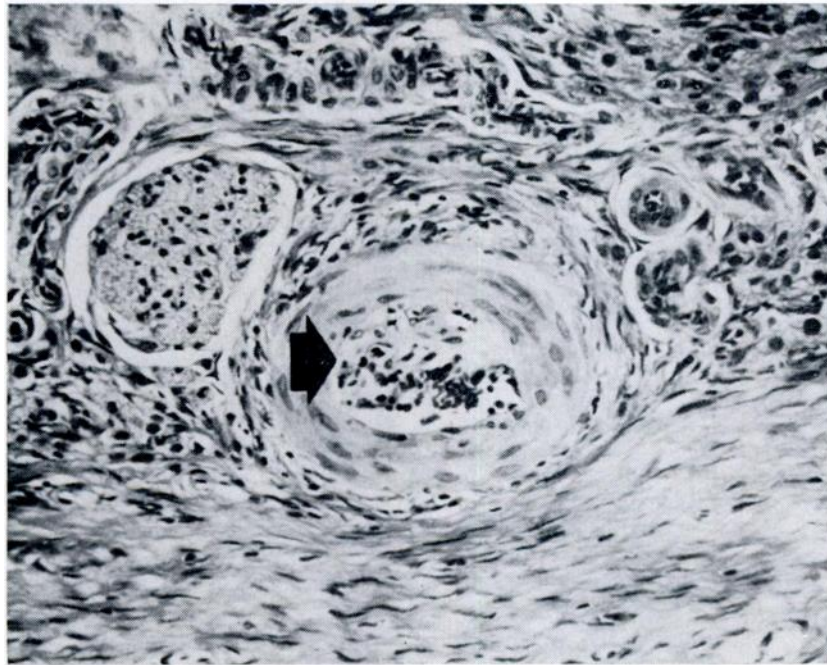


FIGURE 4. Arteriole from atrophic testis showing inflammation and proliferative changes in the tunica intima (arrow). H&E, X250.

relative diminution in interstitial cell numbers. When present, the cells were markedly vacuolated, perhaps due to inhibition of secretory activity.

Although the etiology and pathogenesis of these lesions remain obscure, there are several general possibilities if a common mechanism can be inferred. That the testicular atrophy might have resulted from an unknown toxicity, vascular obstruction, or congenital hypoplasia rather than an infectious process is suggested by the lack of a consistent inflammatory cell infiltrate. However, viral or bacterial causes cannot be excluded, considering the chronicity of the lesions when observed.

The apparent increase in the incidence of testicular atrophy following a wildfire, as described in this report, might suggest that ingestion of estrogenic or gonadotoxic plants or chemicals used in fire or brush suppression could be involved in

the etiology of the lesions. Estrogenic substances, however, have been shown to cause velvet shedding, not retention, in deer.⁴ This leaves open the possibility of other plant or chemical (diesel oil, 2,4-D, 2,4-5-T) toxicities.

Alternatively, the testicular lesions could have a vascular basis. Atrophy of seminiferous tubular epithelium and interstitial cells progressing to connective tissue replacement has been described in rats following various degrees of experimental occlusion of the spermatic artery.⁷ A high incidence of arterial elephoriosis has been reported in Columbian black-tailed deer in California¹¹ and the vascular lesions caused by *Eleophora schneideri* in elk have been described.¹ Whether the testicular infarct in one case was a primary event or secondary to torsion following atrophy is unknown, but the latter seems more likely.

The testicular lesions described herein appear to be very similar histologically to those described in Klinefelter's syndrome in man and genital hypoplasia of white-tailed deer.⁵ However, there were no gross penile abnormalities as noted in

the latter, and many animals of the present group were observed to have normally developed antlers early in life. This possibility can be excluded only by chromosomal studies of affected animals.

Acknowledgement

We are grateful to W. M. Longhurst, Division of Agricultural Sciences, Hopland Field Station, University of California, Davis, and to K. Benirschke, Department of Reproductive Medicine, University of California, San Diego, for their assistance and suggestions during this study.

LITERATURE CITED

1. ADCOCK, J. L. and C. P. HIBLER. 1969. Vascular and neuro-ophthalmic pathology of elaeophorosis in elk. *Path. Vet.* 6: 185-213.
2. CLARK, F. C. 1961. Malformed antlers of deer. *Calif. Fish and Game* 2: 119-123.
3. FERGUSON-SMITH, M. A., B. LENNOX, W. S. MACK and J. S. S. STEWART. 1957. Klinefelter's syndrome. Frequency and testicular morphology in relation to nuclear sex. *Lancet* 2: 167-169.
4. GOSS, R. J. 1968. Inhibition of growth and shedding of antlers by sex hormones. *Nature* 220: 83-85.
5. MARBURGER, R. G., R. M. ROBINSON and J. W. THOMAS. 1967. Genital hypoplasia of white-tailed deer. *J. Mammal.* 48: 674-676.
6. MURPHY, B. D. and R. E. CLUGSTON. 1971. Bilateral testicular degeneration in a wild mule deer. *J. Wildl. Dis.* 7: 67-69.
7. OETTLE, A. G. and R. G. HARRISON. 1953. The histological changes produced in the rat testis by temporary and permanent occlusion of the testicular artery. *J. Path. Bact.* 64: 273-296.
8. ROBINSON, R. M., J. W. THOMAS and R. G. MARBURGER. 1967. Abnormal antler shedding associated with hypogonadism in central Texas deer. *Southwest. Vet.* 20: 93-98.
9. TAYLOR, D. O. N., J. W. THOMAS and R. G. MARBURGER. 1964. Abnormal antler growth associated with hypogonadism in white-tailed deer in Texas. *Amer. J. Vet. Res.* 25: 179-185.
10. THOMAS, J. W., R. M. ROBINSON and R. G. MARBURGER. 1964. Hypogonadism in white-tailed deer of the central mineral region in Texas. *Trans. N. Amer. Wildlife Conf.* 29: 225-236.
11. WEINMANN, C. J., J. R. ANDERSON, W. M. LONGHURST and G. CONNOLLY. 1973. Filarial worms of Columbian black-tailed deer in California. *J. Wildl. Dis.* 9: 213-220.
12. WISLOCKI, G. B., J. C. AUB and C. M. WALDO. 1947. The effects of gonadectomy and the administration of testosterone proportionate on the growth of antlers in male and female deer. *Endocrinology* 40: 202-224.

Received for publication 17 June 1974