

AVIAN POX IN FLORIDA SANDHILL CRANES 1

Authors: SIMPSON, CHARLES F., FORRESTER, DONALD J., and NESBITT, STEPHEN A.

Source: Journal of Wildlife Diseases, 11(1) : 112-115

Published By: Wildlife Disease Association

URL: <https://doi.org/10.7589/0090-3558-11.1.112>

BioOne Complete (complete.BioOne.org) is a full-text database of 200 subscribed and open-access titles in the biological, ecological, and environmental sciences published by nonprofit societies, associations, museums, institutions, and presses.

Your use of this PDF, the BioOne Complete website, and all posted and associated content indicates your acceptance of BioOne's Terms of Use, available at www.bioone.org/terms-of-use.

Usage of BioOne Complete content is strictly limited to personal, educational, and non - commercial use. Commercial inquiries or rights and permissions requests should be directed to the individual publisher as copyright holder.

BioOne sees sustainable scholarly publishing as an inherently collaborative enterprise connecting authors, nonprofit publishers, academic institutions, research libraries, and research funders in the common goal of maximizing access to critical research.

AVIAN POX IN FLORIDA SANDHILL CRANES¹

CHARLES F. SIMPSON,² DONALD J. FORRESTER,² and STEPHEN A. NESBITT³

Abstract: Cutaneous elevations were present on the feet, legs and heads of four Florida sandhill cranes, *Grus canadensis pratensis*, (one free-living, three pen-reared birds). As a result of examination of the elevations by light- and electron microscopy, it was determined that the lesions were caused by poxvirus. This is the first record of pox in cranes in North America.

INTRODUCTION

Avian pox is a common disease of domesticated poultry,³ and also has been reported to occur in approximately 60 species of wild birds representing some 20 families.⁵ Apparently the disease has not been diagnosed in wild anseriformes, although domestic ducks and geese have been found to be susceptible.⁵ No reports were found concerning pox in sandhill cranes.

The present paper is a report of the occurrence of cutaneous pox in four Florida sandhill cranes, *Grus canadensis pratensis*, a subspecies which recently has been classified as "threatened".¹

MATERIALS AND METHODS

Four apparently healthy Florida sandhill cranes with elevated lesions on the unfeathered portions of the body were examined. One specimen was an adult bird which had been live-trapped in May, 1973, by personnel of the Florida Game and Fresh Water Fish Commission on Paynes Prairie, Alachua County, Florida. The other three subadult cranes (16 months of age) were shipped to Florida after being hatched and pen-reared at Patuxent Wildlife Research Center, Laurel, Maryland. These three cranes had been maintained in captivity in Gaines-

ville, Florida, for 9 months prior to the development of skin lesions in July, 1974.

Each of three cranes, (two penned, one free-living) had two to six similar lesions on the head, legs or feet. The fourth crane had approximately 30 such lesions. Lesions varied in size, and were prominent, white-yellow, rough-surfaced elevations.

Cutaneous elevations were removed from the birds by use of a sharp razor blade. A portion from each skin elevation was fixed in 10% neutral formalin, embedded in paraffin, cut at 6 μ m, and stained with hematoxylin and eosin for examination with the light microscope. Another portion from each elevation was fixed in 3.5% glutaraldehyde, post-fixed in OsO₄, and embedded in Araldite for examination with a Philips EM200 electron microscope, following staining of thin sections on grids with uranyl acetate and lead citrate.⁷

RESULTS

In all histologic sections of cutaneous elevations there was hypertrophy and hyperplasia of the surface epithelial cells, with prominent, eosinophilic cytoplasmic inclusion bodies (Fig. 1). The presence of such inclusions usually caused the

¹ Supported in part by Research Grant No. 1270 from the Florida Game and Fresh Water Fish Commission. This is a contribution of the Federal Aid to Wildlife Restoration Program, Florida Pittman-Robertson Project W-41, Florida Agricultural Experiment Stations Journal Series No. 5551.

² College of Veterinary Medicine, University of Florida, Gainesville, Florida 32611 USA.

³ Game and Fresh Water Fish Commission, Wildlife Research Projects Office, Gainesville, Florida 32601 USA.

nucleus to be displaced to the periphery of the cell, or there was pyknosis, karyorrhexis and karyolysis. There was also ulceration of the surface epithelium and invasion of such lesions by inflammatory cells, particularly heterophils.

As observed by electron microscopy, infected cells contained pathognomonic evidence of infection with poxvirus. Immature viral particles and also inclusions existed in the cytoplasm of single cells. Immature viral particles were granular, free in the cytoplasm and were completely or incompletely surrounded by an electron opaque membrane (Fig. 2). Some immature particles contained an eccentric nucleoid.

Inclusions were of various sizes. In some inclusions, the major portion of the body consisted of a homogeneous, electron translucent matrix which appeared to be lipid, and the periphery was composed of mature virions and rodlets (Fig. 2). In other inclusions (Fig. 3), most of the body consisted of intertwined rodlets embedded in an electron translucent matrix, and the periphery consisted of an admixture of rodlets and mature virions. Mature virions were

ovoid and contained a dumbbell shaped nucleoid. (Fig. 4 A).

Other structures seen in the cytoplasm of pox infected cells were filaments (Fig. 4 B). These structures were elongated, had transverse periodicity and were arranged in loose bundles of three to six units.

DISCUSSION

The demonstration by light microscopy of intracytoplasmic inclusion bodies in the epidermis of Florida sandhill cranes, and the ultrastructural observation of filaments and immature viral particles free in the cytoplasm and mature virions in intracytoplasmic inclusions are considered diagnostic of skin infections caused by avian poxvirus,^{2,5} and other poxviruses.⁶ The present report of cutaneous pox in Florida sandhill cranes tends to substantiate the opinion of others⁴ that pox infections of wild birds may be mild and self limiting, unless there is heavy infection of the eyelids. In the present study, pox infections had no detrimental effect on the general health of the birds.

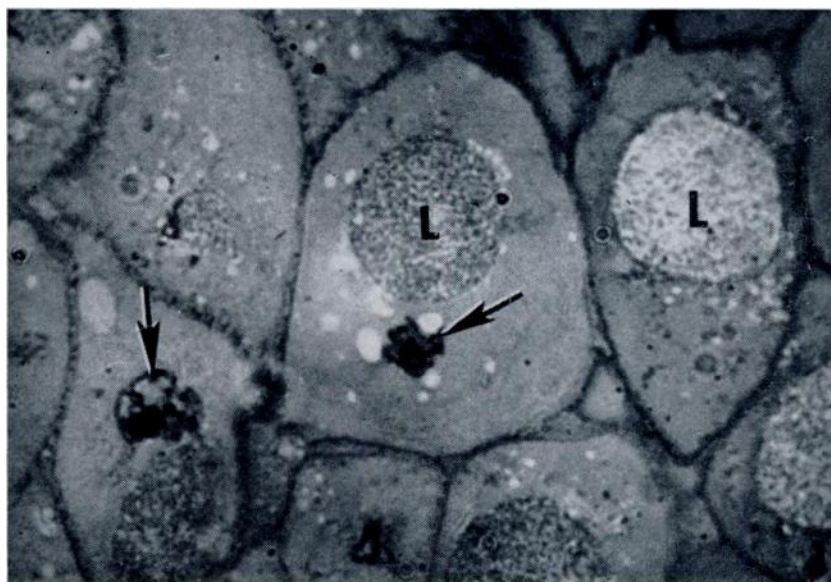


FIGURE 1. Intracytoplasmic inclusions (L) are present in hypertrophic epithelial cells of the epidermis. Note pyknosis (arrows). Hematoxylin and eosin stain. X1,600.

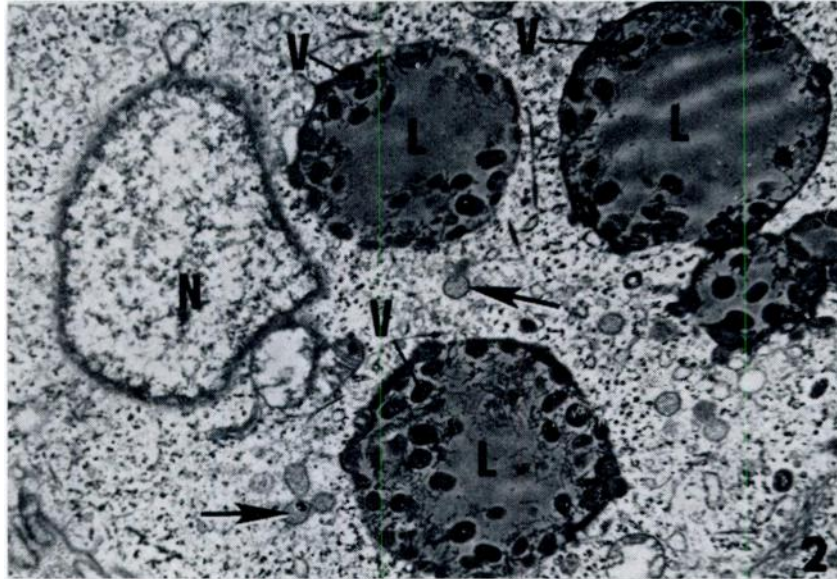


FIGURE 2. Three inclusions with central zones of electron translucent matrix (L) contain mature virions (V) at the periphery. The cytoplasm of the cell contains immature viral particles (arrows), and the nucleus (N) is pale and relatively devoid of structure. X20,000.

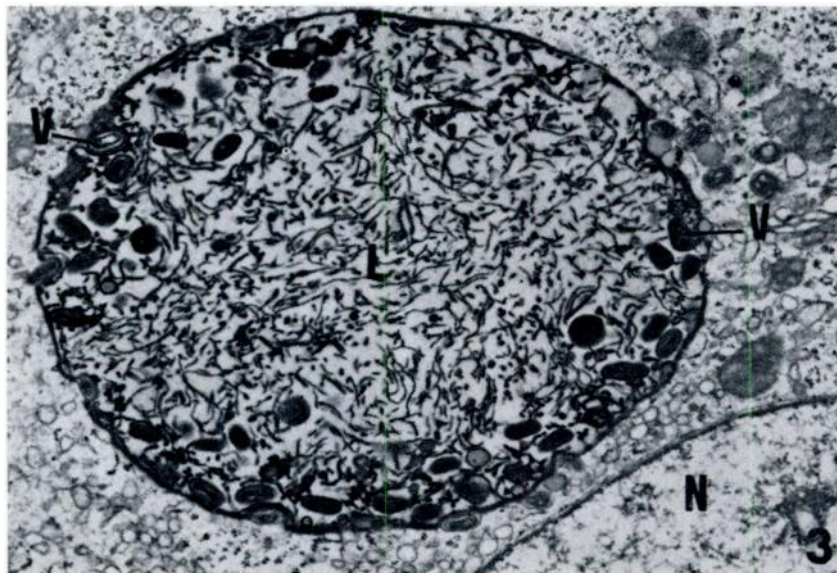


FIGURE 3. The central portion of an inclusion, located close to the nucleus (N), contains intertwined rodlets embedded in an electron translucent matrix (L) and mature virions (V) at the periphery. X25,000.

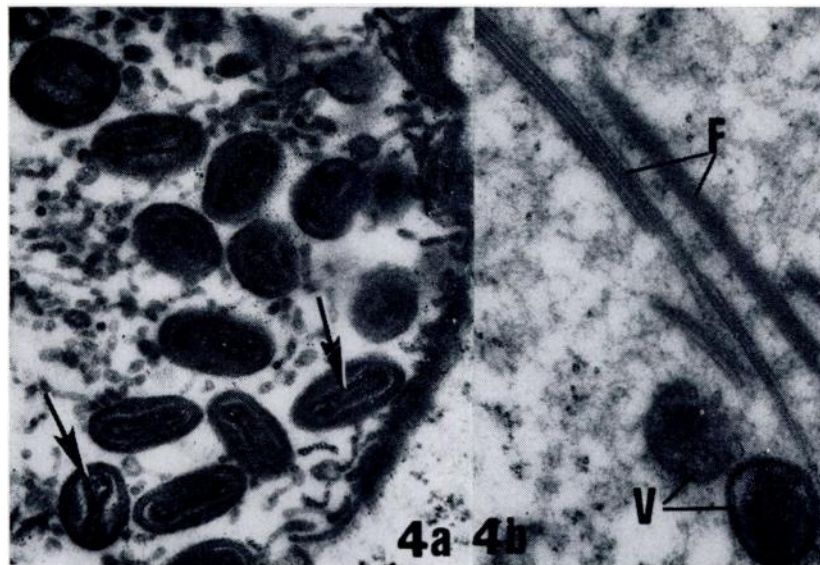


FIGURE 4A. Mature virions in inclusions are ovoid and contain a dumbbell shaped nucleoid (arrows). X65,000.

FIGURE 4B. Filaments (F) with periodicity and immature virions (V) are free in the cytoplasm of an epithelial cell. X65,000.

Acknowledgements

The technical assistance of J. W. Carlisle and W. J. Weber is acknowledged.

LITERATURE CITED

1. ANONYMOUS. 1973. Threatened wildlife of the United States. Office of Endangered Species and International Activities. U.S. Department Interior Research Publication. 114: 289 pp.
2. CHEVILLE, N. F. 1966. Cytoplasmic changes in fowlpox (turkey origin) inclusion body formation. *Am. J. Path.* 49: 723-737.
3. CUNNINGHAM, C. H. 1972. Avian pox, pp. 707-724 in *Diseases of Poultry*, 6th edition, ed. by M. S. Hofstad, Iowa State University Press, Ames, Iowa.
4. KARSTAD, L. 1971. Pox, pp. 34-41 in *Infectious and Parasitic Diseases of Wild Birds*, ed. by Davis, J.W., *et al.*, Iowa State University Press, Ames, Iowa.
5. KIRMSE, P. 1967. Pox in wild birds: An annotated bibliography. *Wildl. Dis.*, 10: 1-10.
6. MORGAN, C., S. A. ELLISON, H. M. ROSE and D. H. MOORE. 1954. Structure and Development of viruses observed in the electron microscope. *J. Exp. Med.*, 100: 301-310.
7. REYNOLDS, E. S. 1963. The use of lead citrate at high pH as an electron opaque stain in electron microscopy. *J. Cell. Biol.*, 17: 208-212.
8. SIMPSON, C. F. 1969. Fowlpox inclusion body formation in skin epithelium of chicks. *Avian Dis.*, 13: 89-100.

Received for publication 9 September 1974