

## **ARTHROPATHY IN WHITE-TAILED DEER AND A MOOSE**

Authors: WOBESER, G., and RUNGE, W.

Source: Journal of Wildlife Diseases, 11(1) : 116-121

Published By: Wildlife Disease Association

URL: <https://doi.org/10.7589/0090-3558-11.1.116>

---

BioOne Complete ([complete.BioOne.org](https://complete.BioOne.org)) is a full-text database of 200 subscribed and open-access titles in the biological, ecological, and environmental sciences published by nonprofit societies, associations, museums, institutions, and presses.

Your use of this PDF, the BioOne Complete website, and all posted and associated content indicates your acceptance of BioOne's Terms of Use, available at [www.bioone.org/terms-of-use](https://www.bioone.org/terms-of-use).

Usage of BioOne Complete content is strictly limited to personal, educational, and non - commercial use. Commercial inquiries or rights and permissions requests should be directed to the individual publisher as copyright holder.

---

BioOne sees sustainable scholarly publishing as an inherently collaborative enterprise connecting authors, nonprofit publishers, academic institutions, research libraries, and research funders in the common goal of maximizing access to critical research.

## ARTHROPATHY IN WHITE-TAILED DEER AND A MOOSE

G. WOBESER, Department of Veterinary Pathology, Western College of Veterinary Medicine, University of Saskatchewan, Saskatoon, Saskatchewan, Canada.

W. RUNGE, Department of Tourism and Renewable Resources, Province of Saskatchewan, Saskatoon, Saskatchewan, Canada.

**Abstract:** Degenerative lesions were found in the skeletal system of 20 of 128 white-tailed deer (*Odocoileus virginianus*) examined. Similar changes were found in an aged male moose (*Alces alces*). Arthropathy involving the stifle joint was present in 60% (15/25) of male deer 4 years of age or older, and in 16.7% (4/25) of females in the same age range. Vertebral osteophytes were not found in any of 62 female deer, nor in male deer less than 6 years of age, but were present in 50% (7/14) of males 6 years of age or older. The possible etiology and significance of the conditions are discussed.

### INTRODUCTION

Degenerative articular disease is a common disorder of man and domestic animals, and has been recognized in species as diverse as laboratory rodents and fossil reptiles.<sup>6</sup> The process may be a normal consequence of aging, and as such usually progresses at a rate allowing functional compensation<sup>4</sup>; however, the lesions must be regarded as pathologic. The prevalence and distribution of this type of disease may vary between species,<sup>2</sup> and between the sexes or genetic strains within a single species.<sup>8</sup>

There appears to be little information available on the occurrence of arthropathy among wild animals; therefore the following data are presented in the hope that they may be useful in the comparative study of degenerative disease.

### MATERIALS AND METHODS

During the months of February to April 1974, 128 white-tailed deer (*Odocoileus virginianus*) were necropsied as part of a study of mortality among Saskatchewan deer during an unusually severe winter. In most cases the animals had been found dead, but in a few cases, weak animals were collected. Many of

the carcasses were frozen when submitted to the laboratory. Lesions found in other than the skeletal system will not be considered here. The sex and weight of the animals were determined, and the age was estimated on the basis of tooth eruption and wear.<sup>7</sup> Age was expressed to the nearest complete year, so that deer born in the spring of 1973 were classed as one year of age. A necropsy was performed and the skeletal system was examined for macroscopic lesions. The spinal column of most adult deer was sectioned longitudinally and examined. The single moose (*Alces alces*) examined was an aged male, found dead in Duck Mountain Provincial Park. The animal was emaciated, with severe dental attrition and periodontitis.

### RESULTS

#### White-Tailed Deer:

Degenerative changes were found in the skeletal system of 20 of the 128 deer examined. The most frequently occurring lesion (19 deer) was arthropathy involving the distal femur and proximal tibia (stifle joint). The lesion was characterized by focal areas of roughness with a "matted" appearance on the articular

cartilage. In some cases clefts or irregularities extended across the articular surface (Figure 1). In one animal (male, 10 years of age) there was bilateral eburnation of the articular cartilage on the medial condyle of both the femur and tibia. The exposed bone appeared to be sclerotic and was grooved in the direction of motion (Figure 2). This animal had large osteophytes located at the margin of the articular cartilage on both the femur and tibia (Figure 3). Arthropathy involving the stifle joint was more common in males than in females,

and was present in 60% (15/25) of males 4 or more years of age (Tables 1 and 2).

Degenerative changes involving the vertebral column were detected in seven male deer (Table 1). The lesions consisted of osteophyte formation on the ventral aspect of the vertebral bodies (Figure 4). Usually these osteophytes were less than 1 cm in length; however, in one animal there was ankylosing spondylosis between the vertebral bodies of T<sub>5</sub> and T<sub>6</sub> (Figure 5). The highest frequency of vertebral body osteophytes

TABLE 1. Prevalence of arthropathy in the stifle joint and vertebral column of 66 male white-tailed deer.

Age (years)	Number examined	Number (percentage) with lesion	
		Stifle	Vertebrae
1	30	0	0
2	7	0	0
3	4	0	0
4	4	2(50)	0
5	7	4(57)	0
6	8	4(50)	3(37.5)
7	2	1(50)	0
8	1	1(100)	1(100)
9	2	2(100)	2(100)
10	1	1(100)	1(100)

TABLE 2. Prevalence of arthropathy in the stifle and coxo-femoral joint of 62 female white-tailed deer.

Age (years)	Number examined	Number (percentage) with lesion	
		Stifle	Coxo-femoral
1	25	0	0
2	11	0	0
3	2	0	0
4	10	1(10)	0
5	5	1(20)	0
6	2	0	0
7	1	1(100)	0
8	4	0	0
9	1	0	1(100)
10	1	1(100)	1(100)

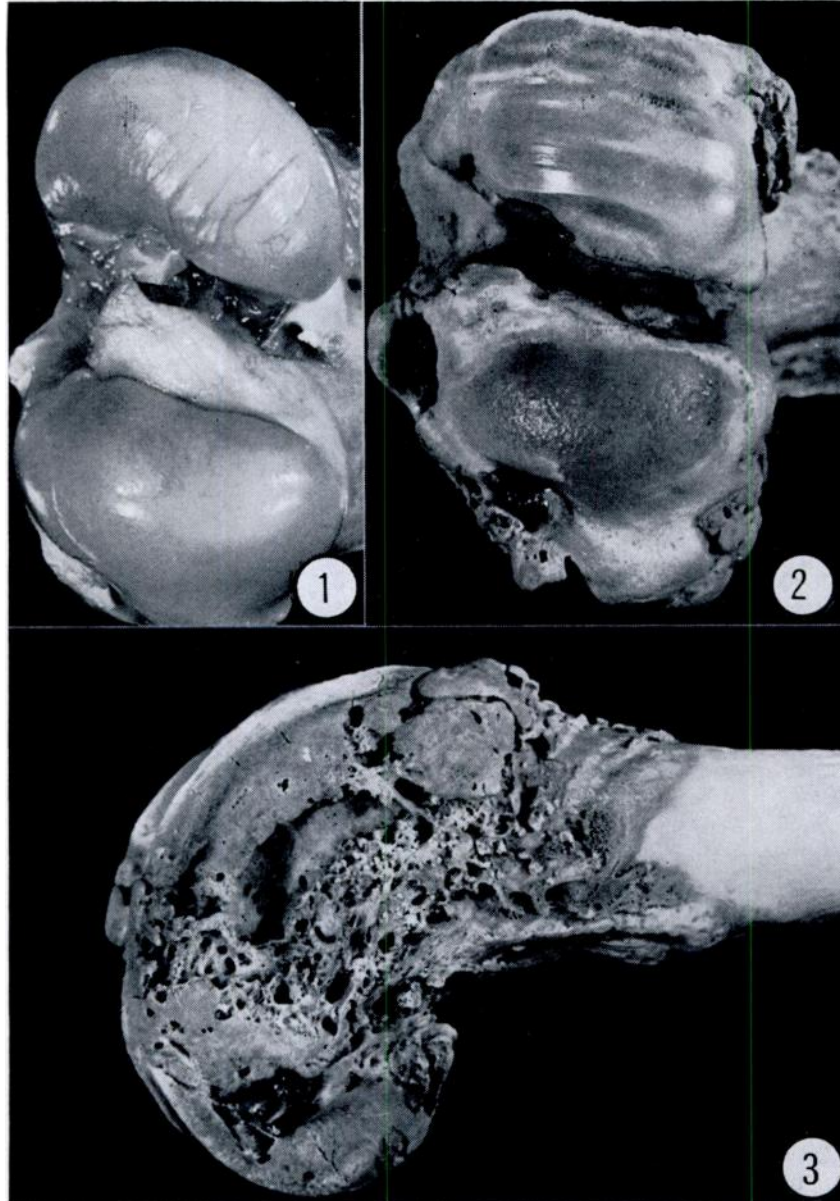


FIGURE 1. Distal femur of male white-tailed deer. Linear clefts in articular cartilage of medial condyle.

FIGURE 2. Distal femur of 10 year old male white-tailed deer, partially macerated. Eburnation of articular cartilage of medial condyle with sclerosis of bone and grooving in direction of motion.

FIGURE 3. Lateral view of same femur as Figure 2. Large osteophytes are present about the margins of the articular surface.

occurred in the anterior thoracic, thoracolumbar and lumbo-sacral regions while T<sub>10</sub> and the mid-lumbar vertebrae were free of osteophytes (Figure 6). Osteophytes occurred on T<sub>2</sub> and T<sub>4</sub> in younger animals and were more generalized in older animals. Intervertebral discs in association with those vertebrae having osteophytes were often degenerate or missing.

Focal degeneration of the articular cartilage on the anterior aspect of the femoral head, and the opposing area of the acetabulum was recognized in two female deer (Table 2).

#### Moose:

Degenerative changes were observed in the cartilage on the anterior aspect of the femoral head, and on both articular surfaces of the atlanto-occipital joint. Vertebral body osteophytes were present on the anterior margins of vertebrae T<sub>4</sub> to T<sub>8</sub> and T<sub>11</sub>, and on the posterior margin of vertebrae T<sub>3</sub> to T<sub>11</sub> and L<sub>6</sub>. Intervertebral discs were absent in the intervertebral spaces from T<sub>3-4</sub> to T<sub>9-10</sub>. The largest osteophytes (1-2 cm) were located on the posterior aspect of T<sub>8</sub>, T<sub>9</sub> and T<sub>10</sub> and occupied a lateral position on the vertebral body.

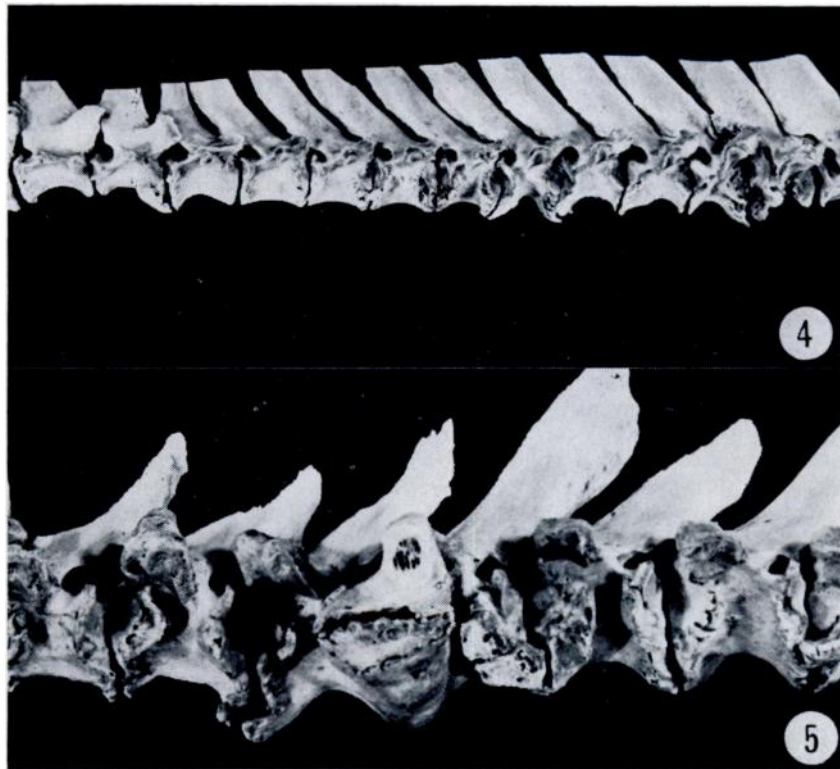

FIGURE 4. Lateral view of macerated vertebral column (thoracic) of 9 year old male deer. Osteophytes are present on the lateral and ventral margins of many vertebral bodies.

FIGURE 5. Lateral view of macerated vertebral column of 10 year old deer. Osteophytes are present on all vertebrae and the bodies of T<sub>5</sub> and T<sub>6</sub> are fused.

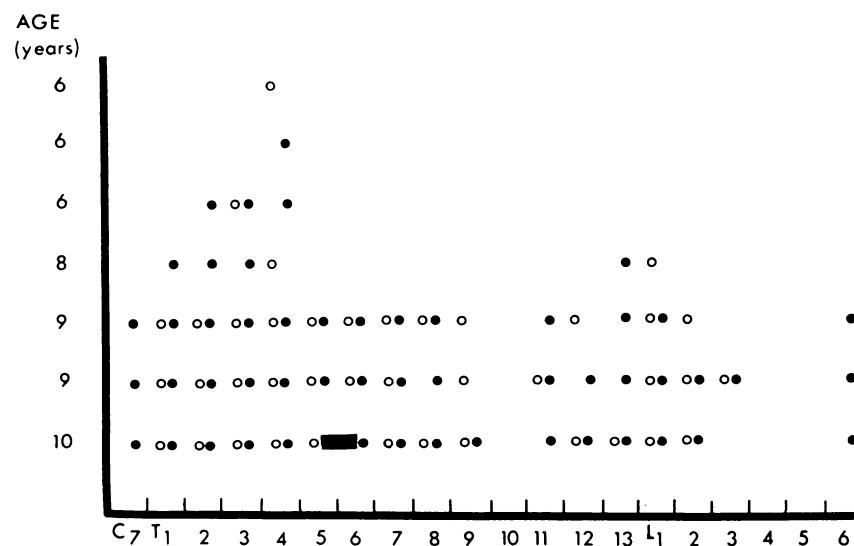


FIGURE 6. Distribution and prevalence of osteophytes on the vertebral column of seven male white-tailed deer. Open circles indicate osteophyte on anterior margin, closed circles on posterior margin of vertebral body. The solid bar represents spondylosis.

#### DISCUSSION

Degenerative changes in joints have been variously called "degenerative arthritis", "osteoarthritis", "degenerative joint disease", "arthrosis", "degenerative arthrosis", and "osteoarthrosis". Similarly, degenerative changes in the vertebral column characterized by vertebral body osteophyte formation have been termed "ankylosing spondylitis", "spondylosis deformans" and "vertebral osteophytosis" plus others. We prefer to use the general term arthropathy to imply a degenerative change in a joint, as suggested by others<sup>4,6</sup> and to reserve the term "spondylosis" for the situation in which there is ankylosis of an intervertebral joint.

Despite the common occurrence of arthropathy in man and animals, the etiology and pathogenesis of the various forms are poorly understood, although numerous factors have been considered.<sup>5,6,9</sup> A disproportionate prevalence of arthropathy among males has been reported in species as diverse as laboratory

mice<sup>8</sup>; humans and domestic cattle.<sup>10</sup> Thomson<sup>10</sup> found only a single osteophyte on one vertebral body of 1 of 156 cows, 5 years or more of age, examined. In contrast the same author found that "Ventral vertebral osteophytes are rare in bulls under 5 years of age, but are exceedingly common in bulls 6 years of age or older"<sup>10</sup>. In the present study, vertebral osteophytes were not found in any of 62 female deer, nor in male deer less than 6 years of age, but were present in 50% (7/14) of males 6 years of age or older, and were present in the four animals judged to be 8 years of age or older.

The highest frequency of vertebral osteophytes in domestic bulls occurred at T<sub>3</sub> and L<sub>1</sub>, with the least at T<sub>1</sub>, T<sub>8</sub>, and L<sub>3</sub>.<sup>10</sup> The highest frequency in deer occurred at T<sub>2</sub>, T<sub>3</sub>, T<sub>4</sub>, followed by T<sub>13</sub> and L<sub>1</sub>. Osteophytes were not found on T<sub>10</sub>, L<sub>3</sub> or L<sub>4</sub>. The only comparable data for deer are those of Fox,<sup>2</sup> who examined the vertebral columns of a male sambar deer (*Rusa unicolor*), and a male red deer (*Cervus elaphus*). These were captive

animals which had been on exhibit for 237 and 86 months, respectively. Osteophytes ("hypertrophic spondylitis") were present on T<sub>1</sub>, T<sub>2</sub>, T<sub>11</sub> and T<sub>12</sub> in the red deer, and T<sub>8</sub> to T<sub>13</sub> and L<sub>1</sub> to L<sub>1</sub> in the sambar deer.

Thomson<sup>10</sup> suggested that the thrust of the bull during service was an important factor in the etiology of vertebral lesions, and Jubb and Kennedy<sup>4</sup> state that ankylosing spondylosis is an occupational hazard of bulls kept in bull studs. Krook *et al.*<sup>5</sup> have suggested that excessive dietary calcium and calcitonin excess may be important in the etiology of these lesions in bulls. The etiology of the vertebral lesions in male deer is unknown, but it seems unlikely that dietary excess of calcium would be involved.

Stifle joint lesions were found in 60% (15/25) of male deer 4 years of age or older, and in only 16.7% (4/25) of females in the same range (Table 1, 2) indicating a similar relationship to sex.

An interesting "experiment of nature" was present among this group of deer. One of the animals judged to be 6 years old appeared to be a male, but had anomalous, velvet-covered, cauliflower-like bony masses in place of antlers, and no testicular tissue was found on either gross or histological examination of the scrotal and inguinal canal area. No degenerative lesions were found in either the stifle joint or vertebral column of this animal, although such lesions were common among male deer of this age (Table 1).

The significance of arthropathy in deer is unknown, and would be impossible to assess without clinical examination of the affected animals; however, it is likely that an animal with severe lesions such as those shown in Figures 2, 3 and 5, would suffer some inconvenience, and extreme cases of arthropathy could be a factor contributing to the elimination of old male cervids from the population.

#### Acknowledgements

The authors gratefully acknowledge the assistance of all Resource Field Staff of the Department of Tourism and Renewable Resources who collected and submitted the specimens which made this study possible.

#### LITERATURE CITED

1. BOLAND, E. W. 1966. Ankylosing spondylitis. In: *Arthritis and Allied Conditions*. Ed. by J. L. Hollander. Lea and Febiger, Philadelphia, p. 633-655.
2. FOX, H. 1939. Chronic arthritis in wild mammals. *Trans. Amer. Phil. Soc.* 31: 73-124.
3. JOHNSON, L. C. 1959. Kinetics of osteoarthritis. *Lab. Invest.* 8: 1223-1241.
4. JUBB, K. V. F. and P. C. KENNEDY. 1970. *Pathology of Domestic Animals*, 2nd ed. Academic Press, New York.
5. KROOK, L., L. LUTWAK and K. McENTEE. 1969. Dietary calcium, ultimobranchial tumors and osteopetrosis in the bull. Syndrome of calcitonin excess? *Amer. J. Clin. Nutr.* 22: 115-118.
6. OLSSON, S. 1971. Degenerative joint disease (osteoarthritis): a review with special reference to the dog. *J. Small Animal Pract.* 12: 333-342.
7. RYEL, L. A., L. D. FRY and R. C. VAN ETTEN. 1961. Validity of age determination in Michigan deer. *Papers Mich. Acad. Sci.* 47: 289-316.
8. SOKOLOFF, L. 1959. Osteoarthritis in laboratory animals. *Lab. Invest.* 8: 1209-1217.
9. SOKOLOFF, L. 1966. The pathology and pathogenesis of osteoarthritis. In: *Arthritis and Allied Conditions*, Ed. by J. L. Hollander. Lea and Febiger, Philadelphia, p. 849-869.
10. THOMSON, R. G. 1969. Vertebral body osteophytes in bulls. *Path. Vet.* 6 (supp). 1-46.

Received for publication 6 September 1974