

A TESTICULAR LEIOMYOMA IN A LARGEMOUTH BASS, *Micropterus salmoides*

Authors: HERMAN, R. L., and LANDOLT, M.

Source: Journal of Wildlife Diseases, 11(1) : 128-129

Published By: Wildlife Disease Association

URL: <https://doi.org/10.7589/0090-3558-11.1.128>

BioOne Complete (complete.BioOne.org) is a full-text database of 200 subscribed and open-access titles in the biological, ecological, and environmental sciences published by nonprofit societies, associations, museums, institutions, and presses.

Your use of this PDF, the BioOne Complete website, and all posted and associated content indicates your acceptance of BioOne's Terms of Use, available at www.bioone.org/terms-of-use.

Usage of BioOne Complete content is strictly limited to personal, educational, and non - commercial use. Commercial inquiries or rights and permissions requests should be directed to the individual publisher as copyright holder.

BioOne sees sustainable scholarly publishing as an inherently collaborative enterprise connecting authors, nonprofit publishers, academic institutions, research libraries, and research funders in the common goal of maximizing access to critical research.

A TESTICULAR LEIOMYOMA IN A LARGEMOUTH BASS, *Micropterus salmoides*

R. L. HERMAN and M. LANDOLT, U.S. Fish and Wildlife Service, Eastern Fish Disease Laboratory, Route #1, Box 17A, Kearneysville, West Virginia, 25430, U.S.A.

INTRODUCTION

Reported cases of leiomyoma in fishes are rare. The latest review of fish tumors lists only seven reports of leiomyoma, most from the gastro-intestinal tract.³ Although a definitive diagnosis is not given, Budd and Schroder² described testicular tumors of high prevalence in yellow perch (*Perca flavescens*); the gross appearance of the tumor is very similar to the one we found in a largemouth bass. This case appears to be the first report of a leiomyoma in this species and organ.

CASE REPORT

An emaciated, moribund, male largemouth bass, approximately 40.6 cm in length, was removed from a brood pond at the Leetown National Fish Hatchery. Based on past history, it was suspected of being a victim of bass tapeworm. Fungus was present on some areas of the gills and adhesions were noted between all of the abdominal organs. The kidneys, spleen, and liver were pale and had small, white spots. A white, firm tumor (3 x 2 x 2 cm) protruded from the posterior half of the right testis. Tissue bulged from the cut surface and appeared fibrous (Fig. 1).

Histologic examination revealed the adhesions to be due to a massive inflammatory reaction in the mesenteries but without obvious cause. The white spots in the kidneys, spleen, and liver were encysted trematodes or poorly organized granulomas, some associated with gram-positive, non-acid fast bacteria.

The tumor cells were elongate with a strong tendency to orient parallel in interlacing bands (Fig. 2). The nuclei were elongate with well rounded ends.

They were evenly distributed through the bands with no evidence of "windrowing" characteristic of neurilemoma. Only small amounts of collagen fibers were demonstrated by Van Gieson's and Mallory's triple stain.¹ The lesion appeared to be restricted to the connective tissues between the semeniferous tubules. Mitotic figures were lacking and no evidence of invasion of adjacent tissue was noted, although some loss of tubules due to compression had occurred. The testis capsule (tunica albuginea) was intact over the lesion.

The cell morphology, banding and growth patterns, and staining characteristics of the lesion indicate a leiomyoma

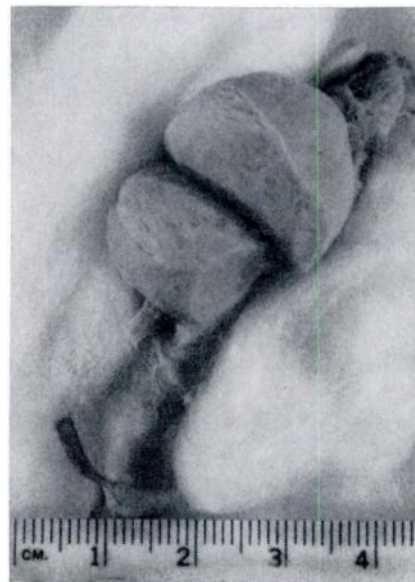

FIGURE 1. Testicular tumor from largemouth bass showing fibrous, swollen cut surface.

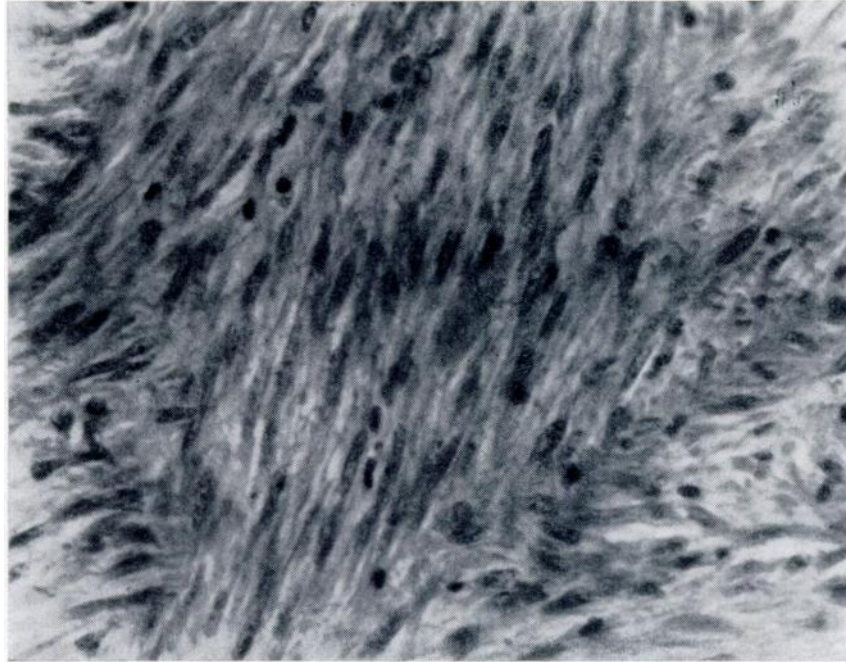


FIGURE 2. Banding of parallel tumor cells showing elongate nuclei with rounded ends typical of smooth muscle. H. and E. 800 X.

developing from smooth muscle in the interstitial tissue of the testis. Mature sperm were loose in the semeniferous tubules and it is probable that the neoplasm did not greatly interfere with

semen production of this fish.

Study material is on deposit with the Registry of Tumors of Lower Animals (RTLA 917) at the Smithsonian Institution, Washington, D.C. 20560.

LITERATURE CITED

1. ARMED FORCES INSTITUTE OF PATHOLOGY. 1960. *Manual of Histologic and Special Staining Technics*. 2nd ed. McGraw-Hill Book Co., New York, N.Y. 207 pp.
2. BUDD, J. and J. D. SCHRODER. 1969. Testicular tumors of yellow perch, *Perca flavescens* (Mitchill). *Bull. Wildl. Dis. Ass.* 5: 315-318.
3. MAWDESLEY-THOMAS, L. E. 1972. Some tumours of fish. Pages 191-283 in L. E. Mawdesley-Thomas, *Diseases of Fish*. Symposia of the Zoological Society of London No. 30.

Received for publication 15 August 1974