



## RENAL FIBROSARCOMA IN THE NORTHERN FUR SEAL

Author: BROWN, RICHARD J.

Source: Journal of Wildlife Diseases, 11(1) : 23-25

Published By: Wildlife Disease Association

URL: <https://doi.org/10.7589/0090-3558-11.1.23>

---

BioOne Complete ([complete.BioOne.org](https://complete.BioOne.org)) is a full-text database of 200 subscribed and open-access titles in the biological, ecological, and environmental sciences published by nonprofit societies, associations, museums, institutions, and presses.

Your use of this PDF, the BioOne Complete website, and all posted and associated content indicates your acceptance of BioOne's Terms of Use, available at [www.bioone.org/terms-of-use](https://www.bioone.org/terms-of-use).

Usage of BioOne Complete content is strictly limited to personal, educational, and non - commercial use. Commercial inquiries or rights and permissions requests should be directed to the individual publisher as copyright holder.

---

BioOne sees sustainable scholarly publishing as an inherently collaborative enterprise connecting authors, nonprofit publishers, academic institutions, research libraries, and research funders in the common goal of maximizing access to critical research.

## RENAL FIBROSARCOMA IN THE NORTHERN FUR SEAL

RICHARD J. BROWN, Comparative Pathology Department, Naval Aerospace Medical Research Laboratory, Pensacola, Florida 32512, USA\*

ALVIN W. SMITH, Research Animal Division, Naval Biomedical Research Laboratory, Oakland, California 94625, USA

MARK C. KEYES, Marine Mammal Division, National Marine Fisheries Service, Seattle, Washington 98115, USA.

*Abstract:* A 2-week-old northern fur seal female pup (*Callorhinus ursinus*) found dead in the Pribilof Islands had an irregular mass at the anterior pole of the right kidney. Histopathological examination revealed a fibrosarcoma.

### CASE REPORT

Diseases of marine mammals, including neoplasia, have not been extensively studied. There are only a few reports of neoplasms in seals.<sup>1,2,3</sup>

This report is concerned with fibrosarcoma found at the anterior pole of the right kidney of a 2-week-old female northern fur seal. This animal was one of 35 northern fur seal neonates found dead on the breeding and parturition grounds of the Pribilof Islands in the summer of 1973. These islands are located approximately 320 km north of the Aleutian chain in the Bering sea, 1130 km west of Anchorage, Alaska.

### RESULTS

Gross examination revealed an irregular nodular mass at the anterior end of the kidney. The tumor did not protrude nor extend to a noticeable degree above the contour of the kidney. On cut section the mass was grayish white and measured 0.8cm x 0.4cm. No other lesions were found in the animal.

Microscopic examination of sections

cut after routine formalin fixation and paraffin embedding revealed a highly cellular mass with islands of cells invading the kidney parenchyma (Fig. 1). The cells were for the most part spindle-shaped and arranged in whorls, eddies and rosettes (Fig. 2). Pre-existing kidney tubules were surrounded by spindle cells which were arranged in a concentric pattern. Hyperchromatic nuclei and mitotic figures were abundant in some areas but sparse in others.

### DISCUSSION

The pattern of the spindle cells was suggestive of a hemangiopericytoma. However this was discounted after reviewing a reticulum stain. Based on the whorls and bundles of immature fibroblasts and numerous mitotic figures, we feel this tumor represents a renal fibrosarcoma.

The fibrosarcoma is occasionally found in the urogenital system of the dog, mare and ox.<sup>4</sup>

The authors are unable to find previous reports of a fibrosarcoma in the kidney of marine animals.

\* Present address: Pathology Department, U.S. Naval Medical Research Unit No. 2, Box 14, APO San Francisco 96263, USA.

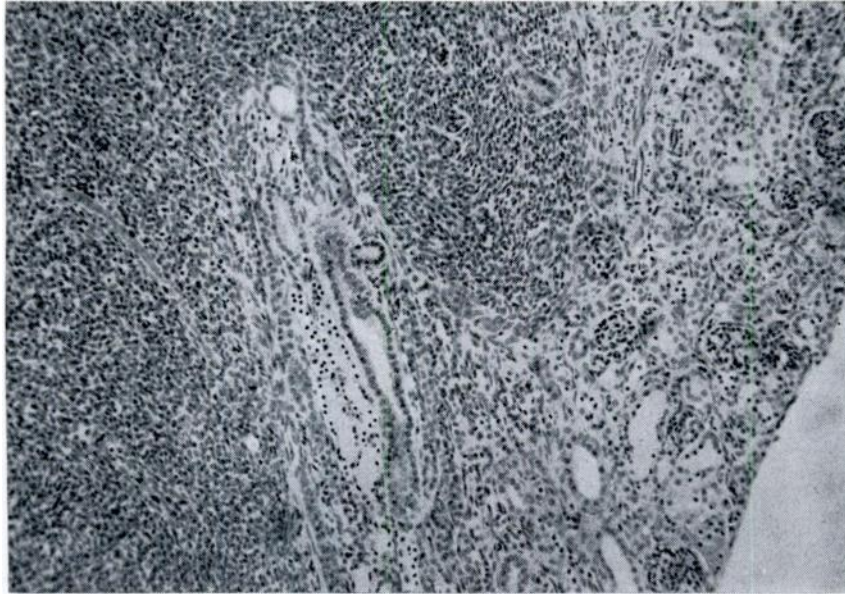


FIGURE 1. Islands of neoplastic cells invading the renal parenchyma, fur seal, H & E 40X.

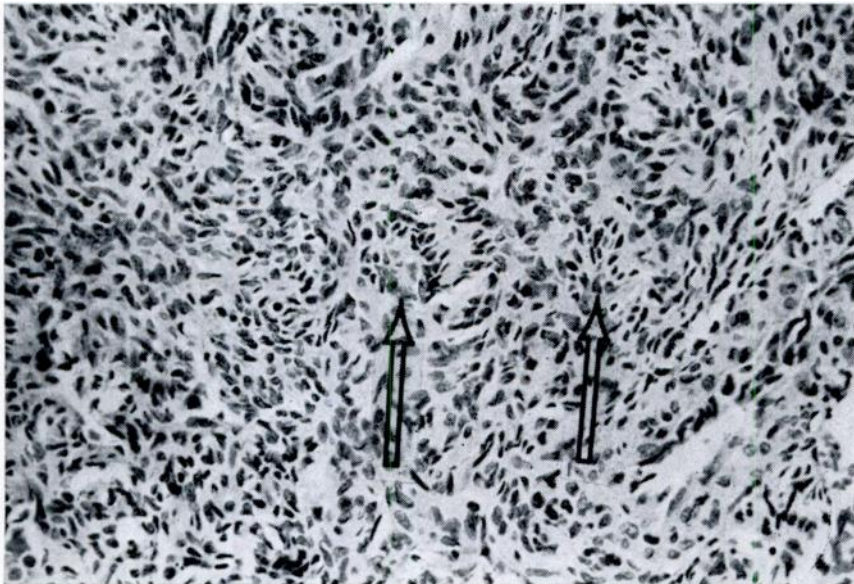


FIGURE 2. Rosettes (arrows) are seen among spindle cells with hyperchromatic nuclei, kidney, northern fur seal, H & E 250X.

---

**LITERATURE CITED**

1. GRINER, L. A. 1971. Malignant leukemia in two harbor seals (*Phoca vitulina geronimensis*). Am. J. vet. Res. 32: 827-830.
2. MAWDESLEY-THOMAS, L. E. 1971. An ovarian tumor in a southern elephant seal (*Miraunga leonina*). Vet. Pathol. 8: 9-15.
3. MAWDESLEY-THOMAS, L. E. and W. N. BONNER. 1971. Uterine tumors in a gray seal (*Halichoerus grypus*). J. Pathol. 103: 205-208.
4. MOULTON, J. E. 1961. *Tumors in Domestic Animals*. Univ. of Calif. Press, Berkeley, pp. 26-27.

*Received for publication 26 March 1974*

---