



DEBILITATING OSSIFYING FIBROMAS OF A WHITE-TAILED DEER ASSOCIATED WITH EAR TAGGING 1

Author: ROSCOE, DOUGLAS E.

Source: Journal of Wildlife Diseases, 11(1) : 62-65

Published By: Wildlife Disease Association

URL: <https://doi.org/10.7589/0090-3558-11.1.62>

BioOne Complete (complete.BioOne.org) is a full-text database of 200 subscribed and open-access titles in the biological, ecological, and environmental sciences published by nonprofit societies, associations, museums, institutions, and presses.

Your use of this PDF, the BioOne Complete website, and all posted and associated content indicates your acceptance of BioOne's Terms of Use, available at www.bioone.org/terms-of-use.

Usage of BioOne Complete content is strictly limited to personal, educational, and non - commercial use. Commercial inquiries or rights and permissions requests should be directed to the individual publisher as copyright holder.

BioOne sees sustainable scholarly publishing as an inherently collaborative enterprise connecting authors, nonprofit publishers, academic institutions, research libraries, and research funders in the common goal of maximizing access to critical research.

DEBILITATING OSSIFYING FIBROMAS OF A WHITE-TAILED DEER ASSOCIATED WITH EAR TAGGING^[1]

DOUGLAS E. ROSCOE, N.Y.S.D.E.C., Wildlife Research Laboratory, Delmar, New York 12054, USA.

LAURENCE R. VEIKLEY, MAURICE MILLS JR. and LOUIS HINDS III, U.S. Fish and Wildlife Service, Great Swamp N.W.R., Basking Ridge, New Jersey 07920, USA.

Abstract: A 2.3 kg partially ossified fibroma developed apparently within a 4½ month period near a tag inserted in the right ear of a 5½ year old white-tailed doe (*Odocoileus virginianus*). This growth caused an abnormal head carriage, disturbed feeding and resulted in emaciation. Secondary partially ossified fibromas developed at the left ear tag and in the right external acoustic meatus. The latter fibroma penetrated the tympanic membrane. The puncture wounds in the ears associated with the aluminum tags probably provided sites for virus infection and subsequent fibromatosis.

INTRODUCTION

Numerous authors have reported the occurrence of benign neoplasms on the skin of white-tailed deer identifying them variously as neurofibromas, fibromas and fibrosarcomas.^{2,9,13} Friend⁶ reported a low prevalence (1.4% or less) of spontaneous fibromatosis in white-tailed deer from New York. Shope *et al.*¹¹ demonstrated that fibromas of white-tailed deer are transmissible via abrasions and are probably caused by a host specific virus. Fay⁵ pointed out that fibromas do not usually kill deer except when they interfere with organ functions. This paper reports the occurrence of debilitating partially ossified fibromas associated with ear tags in a white-tailed deer.

CASE REPORT

History

A female white-tailed deer was captured with a projectile syringe loaded

with succinylcholine chloride in the course of a deer management study on January 1, 1973 at the Great Swamp National Wildlife Refuge, New Jersey. Aluminum ear tags were pierced through each pinna approximately 9 cm distal to the intertragic notch and 3 cm in front from the anterior border. No lesions or abnormalities of the ears were noted at the time of tagging. A lettered expandable collar was placed on the neck for field identification. The animal weighed 63 kg. In July 1973 the doe was seen again, accompanied by twin fawns. She was again sighted on August 25 of the same year and appeared normal and healthy. On September 10, 1973 a mass of about 6 cm in diameter was observed on the deer's right ear. By December the growth had become so heavy that it caused the deer to cant its head to the right nearly 90 degrees from vertical. On January 15, 1974 the deer was easily captured by a refuge official, killed and submitted for necropsy.

[1] The authors wish to acknowledge the assistance of David E. Janes and Peter Heere of the U.S. Fish and Wildlife Service, Great Swamp N.W.R., Basking Ridge, N.J.

Gross Examination

The 5½ year old doe was emaciated (43.6kg) with depleted subcutaneous, pericardial and perirenal fat reserves. The mean kidney fat index¹⁰ was 13.5%, and the femur marrow was red and gelatinous, containing 36% fat.¹² The rumen contained 84% deciduous leaves and woody twigs. The remaining 16% was rose hips and grass. Two *Taenia hydatigena* cysticerci were found in the abdominal mesenteries. The doe had been bred in the 2nd week of November, as determined from crown-rump measurements of a male and a female fetus recovered from the uterus.^{1,4} No gross abnormalities or lesions were noted in the fetuses or in any of the internal organs of the doe. A darkly pigmented growth on the right ear measured 25 cm x 15 cm and weighed 2.3 kg (Fig. 1). It

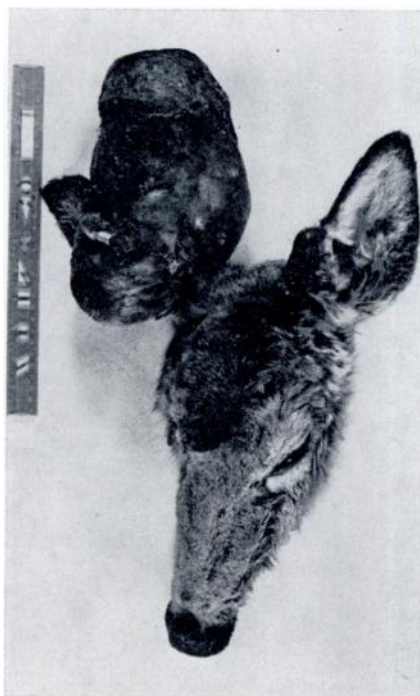

FIGURE 1. Partially ossified fibromas of a white-tailed doe. Note ear tags being enveloped by the fibromas.

was encrusted with clotted blood from multiple contusions and abrasions, presumably sustained when the mass struck trees and brush. Attempts to section the growth with a knife were unsuccessful, since the stroma was ossified. The 1 cm thick outer cortex of the mass was not ossified and resembled the soft fibroma described and illustrated by Fyvie.⁷ The fibroma was divided by the auricular cartilage into two lobes. A stalk of fibrous tissue connected the two lobes via the hole made by the ear tag. The expanding growth had torn the tag from the ear and enveloped it. A small partially ossified fibroma originating from the ventral surface of the right external acoustic meatus completely blocked the canal and perforated the tympanic membrane. Two additional growths on the left pinna measuring approximately 5 cm each and also originating at the ear tag, were partially ossified, bilobed and connected by a fibrous stalk passing through the puncture wound inflicted by the tag. Auricular cartilage did not appear to be incorporated in the growths, since the neoplasms could be moved back and forth on the underlying cartilage.

Histopathology

Samples from all of the ear growths were decalcified in 20% formic acid and hydrated. Ten micron frozen sections were stained with Harris' hematoxylin and eosin Y. Stellate, angulated and spindle shaped fibroblasts with dark staining polymorphic nuclei in a matrix of swirling collagen strands comprised the unossified cortex of the neoplasm. Neutrophils, eosinophils and macrophages infiltrated some areas of cellular necrosis on the interface of the ossified and unossified regions of the tumor. The stroma of the growth was composed primarily of bone, with well-developed haversian systems and trabeculae (Fig. 2). Neutrophils and eosinophils were deposited along the endothelial linings of veins coursing through the ossified stroma. No chondrocytes were involved in the growths.

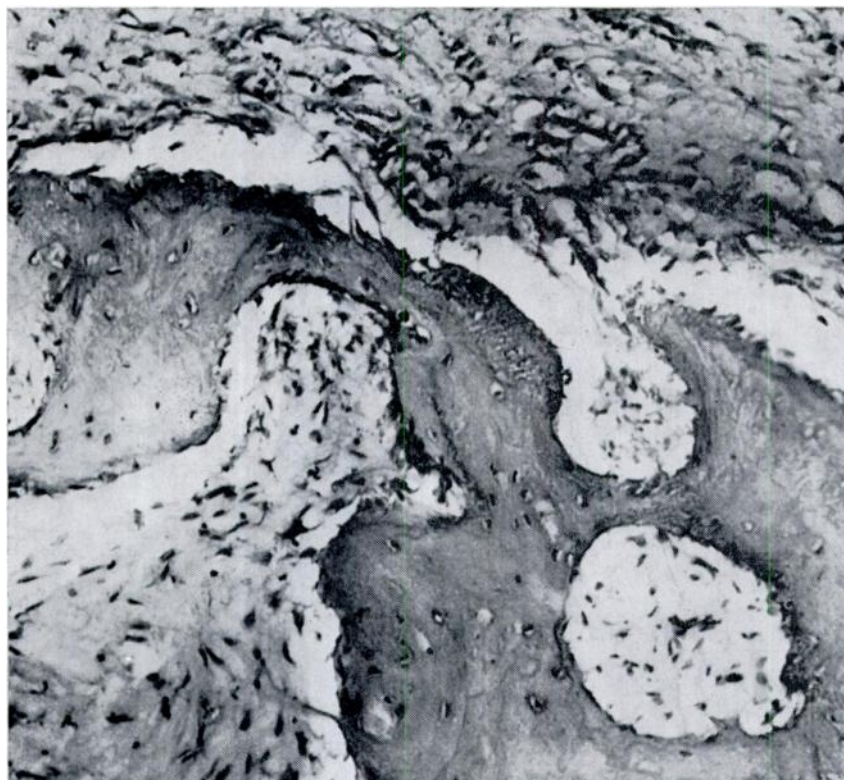


FIGURE 2. The Haversian systems and trabecular bone at the interface of the ossified and unossified regions of the fibroma. H & E stain. 200X.

DISCUSSION

The unusual tilt of the doe's head was obviously a disability when feeding and probably contributed to the poor physical condition of the animal, weighing nearly 20 kg less than on the same month the previous year. The loss of hearing in the right ear would probably increase vulnerability to predation.

The histopathology of the growths examined is that of a fibroma undergoing heterotopic ossification. Ham⁸ describes heterotopic ossification as being the result of some inductive stimulus, such as calcium being deposited in necrotic tissue, stimulating undifferentiated mesenchymal cells to divide and form osteo-

blasts. This explanation for ossification seems applicable to this case, since focal necrosis of the tumor was evident and osteoblasts were active. These neoplasms differed from infectious cutaneous fibromas of New Jersey white-tailed deer described by Shope *et al.*¹¹ in that they had areas of tissue necrosis, ossification and no apparent epithelial thickening. Although no attempts were made to transmit the tumor experimentally, it seems reasonable to assume that the smaller neoplasms of the left ear and right external acoustic meatus were the result of spontaneous fibroma virus inoculations from the large traumatized right ear fibroma, which apparently developed within a 4½ month period.

Friend^a suggested that wounds incurred during rut fights and rubbing may provide sites for infection and may account for the proportionately higher incidence of fibromatosis in bucks. Papillomas of cattle and horses sometimes occur around eartags and may be spread by tattooing implements.³

The wounds caused and kept open by the ear tags in the present case probably provided sites at which fibroma virus infection took place from vegetation, blood

sucking arthropods or other deer. A less likely alternative, since no growths were observed until 9 months after tagging, is that the tags and tagging pliers may have been contaminated from previous contact with other deer. In any event, it would be advisable when conducting deer tagging programs to sterilize equipment and disinfect the ear in order to minimize this potential source of fibroma virus transmission.

LITERATURE CITED

1. ARMSTRONG, R. A. 1950. Fetal development of northern white-tailed deer (*Odocoileus virginianus borealis* Miller). *Am. Midland Nat.* 43: 650-666.
2. BERRY, E. C. 1925. Fibroma in a virginia deer. *J. Mammal.* 6: 130.
3. BLOOD, D. C. and J. A. HENDERSON 1968. *Veterinary Medicine* Williams and Wilkins Co., Baltimore, Md.: 538-539.
4. CHEATUM, E. L. and G. H. MORTON. 1946. Breeding season of white-tailed deer in New York. *J. Wildl. Mgmt* 10: 249-263.
5. FAY, L. D. 1962. Neoplastic diseases of white-tailed deer. *Proc. 1st Nat. White-tailed Deer Disease Symp.*, University of Georgia, Athens, Georgia: 132-137.
6. FRIEND, M. 1967. Skin tumors in New York deer. *Bull. Wildl. Dis. Ass.* 3: 102-104.
7. FYVIE, A. 1969. *Manual of Common Parasites, Diseases and Anomalies of Wildlife in Ontario*. Dept. of Lands and Forests, Ontario, Canada: 21-24.
8. HAM, A. W. 1969. *Histology*. J. B. Lippincott Co., Philadelphia, Pa.: 397.
9. HOOVER, E. E. 1937. Neurofibromatosis in white-tailed deer. *J. Mammal.* 18: 104-105.
10. RINEY, T. 1955. Evaluating condition of free-ranging red deer, (*Cervus elaphus*) with special reference to New Zealand. *New Zealand J. Sci. and Technology Section B*, 36: 429-463.
11. SHOPE, R. E., R. MANGOLD, L. G. MacNAMARA and K. R. DUMBELL. 1958. An infectious cutaneous fibroma of the white-tailed deer (*Odocoileus virginianus*). *J. exp. Med.* 108: 797-802.
12. VERME, L. J. and J. C. HOLLAND. 1973. Reagent-dry assay of marrow fat in white-tailed deer. *J. Wildl. Mgmt* 37: 103-105.
13. WADSWORTH, J. R. 1954. Fibrosarcomas in a deer. *J. Am. vet. med. Ass.* 124: 194.

Received for publication 16 July 1974