

A FOURTH PAIR OF MANDIBULAR MOLARS IN A WHITE-TAILED DEER

Authors: ABLER, W. A., and SCANLON, P. F.

Source: Journal of Wildlife Diseases, 11(1) : 76-78

Published By: Wildlife Disease Association

URL: <https://doi.org/10.7589/0090-3558-11.1.76>

BioOne Complete (complete.BioOne.org) is a full-text database of 200 subscribed and open-access titles in the biological, ecological, and environmental sciences published by nonprofit societies, associations, museums, institutions, and presses.

Your use of this PDF, the BioOne Complete website, and all posted and associated content indicates your acceptance of BioOne's Terms of Use, available at www.bioone.org/terms-of-use.

Usage of BioOne Complete content is strictly limited to personal, educational, and non - commercial use. Commercial inquiries or rights and permissions requests should be directed to the individual publisher as copyright holder.

BioOne sees sustainable scholarly publishing as an inherently collaborative enterprise connecting authors, nonprofit publishers, academic institutions, research libraries, and research funders in the common goal of maximizing access to critical research.

A FOURTH PAIR OF MANDIBULAR MOLARS IN A WHITE-TAILED DEER

W. A. ABLER and P. F. SCANLON, Department of Fisheries and Wildlife Science,
Virginia Polytechnic Institute and State University, Blacksburg, Virginia 24061, USA.

Abstract: A fourth pair of mandibular molars in a white-tailed deer (*Odocoileus virginianus*) was located posterior to the third pair. There was a distinct gap between the third and fourth molars on both left and right sides.

Wear on mandibular molars and premolars is utilized as an aging technique for deer, and extremely large numbers of mandibles have been examined. Most reports of dental anomalies in deer have been based on such examinations. The normal dentition within the genus *Odocoileus* is considered to be: incisors 0/1, 0/2, 0/3; canines 0/1; premolars 0/0, 2/2, 3/3, 4/4; molars 1/1, 2/2, 3/3.⁸ A wide range of anomalies have been reported,^{1,4} and the presence of a fourth pair of mandibular molars in white-tailed deer has been reported.^{2,6,7}

In the present case four pairs of molars were found in mandibles recovered from an adult male white-tailed deer killed at the Radford Army Ammunition Plant, Radford Virginia (Fig. 1). The fourth pair of molars was posterior to the m3 pair with a distinct gap between the third and fourth molars. The maxillae were not recovered; however, we considered that a fourth pair of maxillary molars was not present as there was no wear on the upper surface of the fourth mandibular molars (Fig. 1 and 2) though there was slight wear on the anterior surfaces of both. There were two cusps on the right fourth molar and three cusps on the left fourth molar. The fourth molars did not resemble normal m3 molars as was the case with animals

described by Verme⁸ and by Free *et al.*¹ They were fully erupted and had sharp buccal and lingual crests. Verme⁸ notes that there was normal wear of the regular dentition in the four animals which he studied. In the present animal the other molars were worn irregularly so that it was not possible to accurately estimate the age of the deer by the method of Severinghaus.⁶ The first molars were well worn (indicative of wear seen on a 6.5 year-old deer) while there was considerably less wear on m2 and m3. The lingual crests on m2 and m3 were sharp and the extent of wear resembled that on a 4.5 year-old deer.

Judging by the lack of reports of fourth molars, despite the frequency of examination of mandibular dentition in deer and by the comments of Verme,⁸ the presence of four pairs of mandibular molars is an extremely rare occurrence among white-tailed deer. Verme⁸ considered that, since the four animals with four molars which he examined were from the same locality and were recovered over a short period of time, the condition might be hereditary. The animal dealt with in this report is from a confined herd but too few deer (only 12) from this herd have been examined to comment on the frequency of the condition in the population.

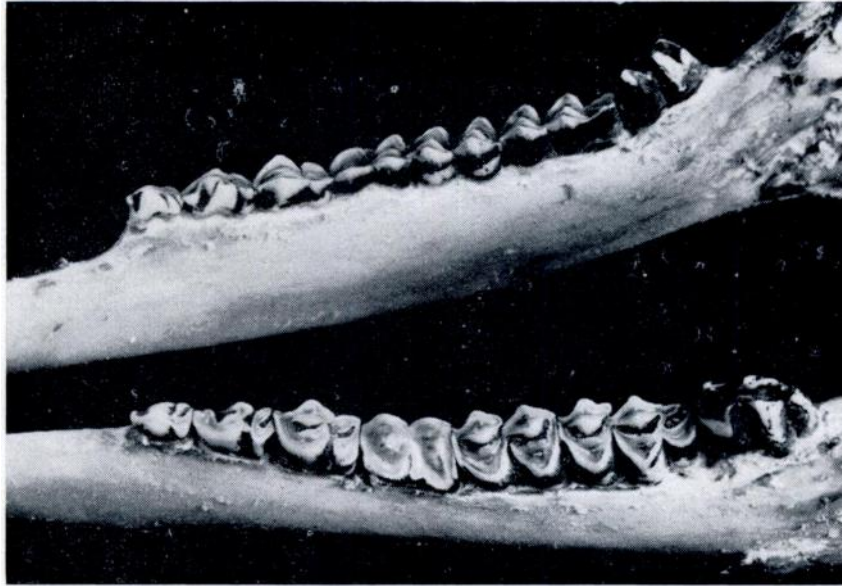


FIGURE 1. Mandible of white-tailed deer with a fourth pair of molars. Fourth molar on left has three cusps while fourth molar on right has two cusps.

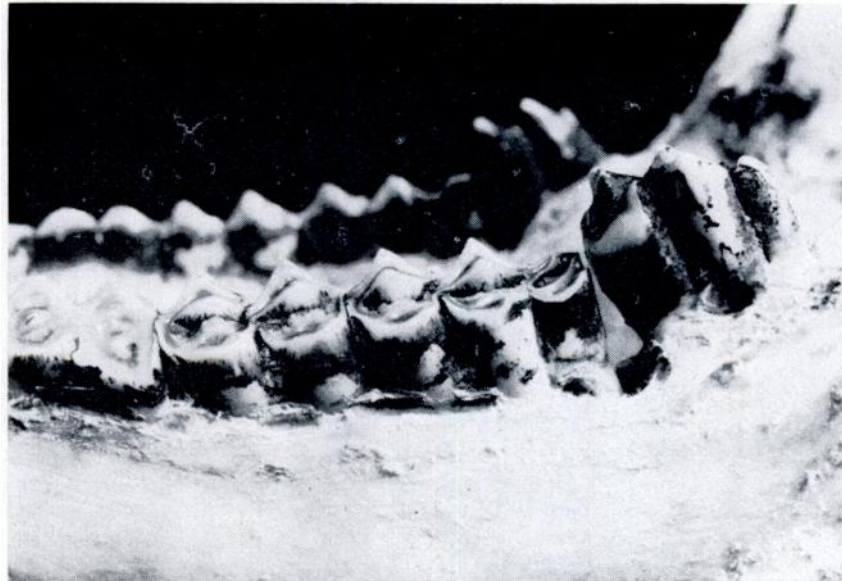


FIGURE 2. Buccal view of the left mandible. Note the distinct gap between the third and fourth molars, the slight wear on the anterior surface of the fourth molar and the well worn condition of the first molar relative to m2 and m3.

LITERATURE CITED

1. FREE, S. L., A. S. BERGSTROM and J. E. TANCK. 1972. Mandibular and dental anomalies of white-tailed deer. *New York Fish Game J.*, 19: 32-46.
2. MECH, L. D., L. D. FRENZEL, JR., P. D. KARNS and D. W. KUEHN. 1970. Mandibular dental anomalies in white-tailed deer from Minnesota. *J. Mammal.*, 51: 804-806.
3. RINEY, T. 1951. Standard terminology for deer teeth. *J. Wildl. Mgmt* 15: 99-101.
4. RYEL, L. A. 1963. The occurrence of certain anomalies in Michigan white-tailed deer. *J. Mammal.*, 44: 79-98.
5. SEVERINGHAUS, C. W. 1949. Tooth development and wear as criteria of age in white-tailed deer. *J. Wildl. Mgmt* 13: 195-216.
6. VERME, L. J. 1968. Possible hereditary defects in Michigan white-tailed deer. *J. Mammal.*, 49: 148.
7. VERME, L. J. and J. J. OZOGA. 1966. A white-tailed deer jaw with fourth molars. *Jack-Pine Warbler*. 44: 148. (Not seen: Cited by VERME, 1968 and FREE *et al.* 1972).

Received for publication 11 August 1974
