



INCLUSION BODY DISEASE IN A GREAT HORNED OWL 1

Authors: SILEO, L., CARLSON, H. C., and CRUMLEY, S. C.

Source: Journal of Wildlife Diseases, 11(1) : 92-96

Published By: Wildlife Disease Association

URL: <https://doi.org/10.7589/0090-3558-11.1.92>

BioOne Complete (complete.BioOne.org) is a full-text database of 200 subscribed and open-access titles in the biological, ecological, and environmental sciences published by nonprofit societies, associations, museums, institutions, and presses.

Your use of this PDF, the BioOne Complete website, and all posted and associated content indicates your acceptance of BioOne's Terms of Use, available at www.bioone.org/terms-of-use.

Usage of BioOne Complete content is strictly limited to personal, educational, and non - commercial use. Commercial inquiries or rights and permissions requests should be directed to the individual publisher as copyright holder.

BioOne sees sustainable scholarly publishing as an inherently collaborative enterprise connecting authors, nonprofit publishers, academic institutions, research libraries, and research funders in the common goal of maximizing access to critical research.

INCLUSION BODY DISEASE IN A GREAT HORNED OWL¹

L. SILEO, H. C. CARLSON and S. C. CRUMLEY²

Abstract: The carcass of a great horned owl (*Bubo virginianus*), which had been found moribund in southern Ontario, was presented for necropsy. Throughout the liver and spleen were numerous white foci 1-2 mm in diameter; also noted were white plaques in the mucosae of the pharyngeal papillae and intestine. Results of light and electron microscopic studies and experimental transmission to two captive great horned owls suggested that this was a herpesvirus disease similar and possibly identical to the owl disease reported by other workers in Wisconsin and Australia.

INTRODUCTION

A disease characterized by intranuclear inclusion bodies and of probable viral etiology was reported in a North American owl (*Bubo virginianus*) in 1932.^{3,4} Since that time a similar disease has been reported from prairie falcons (*Falco mexicanus*) and peregrine falcons (*F. peregrinus*) in North America as well as eagle owls (*Bubo bubo*) in Europe, but it has not been reported again from North American owls.^{1,2,5,6} It has been called inclusion body disease by Maré and Graham and *Hepatosplenitis infectiosa strigum* by Burtscher and Schumacher.^{2,5}

CASE HISTORY

On March 22, 1972, a conservation officer saw a great horned owl collapse in mid-flight. The officer captured, examined and released the owl which flew a short distance and again fell to the ground. The owl was recaptured and taken to a park of the Ontario Waterfowl Research Foundation. The owl died the next day and was submitted for examination on March 24th.

MATERIALS AND METHODS

At necropsy, representative portions of oral mucosae, esophagus, proventriculus, intestine, liver, spleen, kidney, heart, lung, brain, thyroid, ovary and tibial marrow, were fixed in 10% buffered formalin, sectioned at 5 μ m and stained with hematoxylin and eosin (H & E). Specimens of liver, spleen and bone marrow were fixed in glutaraldehyde and post-fixed in osmium tetroxide and embedded in epon. Thin sections were cut on an ultramicrotome and stained with uranyl acetate and lead citrate for electron microscopic examination. Sheep blood agar and MacConkey's agar plates were inoculated with liver, spleen, and intestinal tissue and incubated aerobically overnight at 37 C. The remaining hepatic and splenic tissue was stored at -56 C.

Subsequently, two captive great horned owls were inoculated into the pectoralis major muscles with 0.5 ml of a supernatant prepared by grinding 2 g of frozen liver tissue in 3 ml of sterile saline which was then centrifuged at 1000 rpm for 10 min.

Primary cell cultures of duck embryo fibroblasts (DEF) were inoculated with the supernatant of a centrifuged suspension of ground hepatic and splenic tissues

¹ This work was partially supported by the Ontario Ministry of Natural Resources and the Ontario Ministry of Agriculture and Food.

² Department of Pathology, Ontario Veterinary College, University of Guelph, Guelph, Ontario, Canada N1G 2W1.

from one of the experimentally infected owls. Infected DEF cells showing distinct cytopathic effects (CPE) were scraped from the flask surface and collected along with the medium. The suspension was frozen (-70°C) and thawed 3 times and centrifuged at $5140 \times g$ for 10 min. The supernatant fluid was then ultracentrifuged at $78,480 \times g$ for 2 h, the pellet collected and resuspended in an equal weight of distilled water and stained with phosphotungstic acid (PTA), pH 6.0 on a 1:1 volume basis. It was then placed on a carbon coated formvar 300 mesh grid for electron microscopic examination.

RESULTS

The owl was an adult female, weighed 1.34 kg and had fat present in normal fat depots. Gross pathological examination

revealed 3-4 mm raised, yellow areas on the base of the pharyngeal papillae; and 1-4 mm raised, yellow plaques with hemorrhagic borders on the mucosae of the esophagus, proventriculus, duodenum, and one cecum. There were ecchymotic hemorrhages on the thoracic air sacs and on the peri- and epicardium. The liver was studded with well-demarcated white foci 1-3 mm in diameter, some of which were depressed below and others raised above the surface. Similar lesions were present throughout the spleen.

Escherichia coli was the only bacterium isolated from the liver, spleen and intestine. No significant lesions were noted in brain, lung, heart, or thyroid. Light microscopic examination of the plaques on oral and intestinal mucosae revealed areas of ulceration associated with necrosis of deeper submucosal and muscular tissue. The lesions in parenchy-

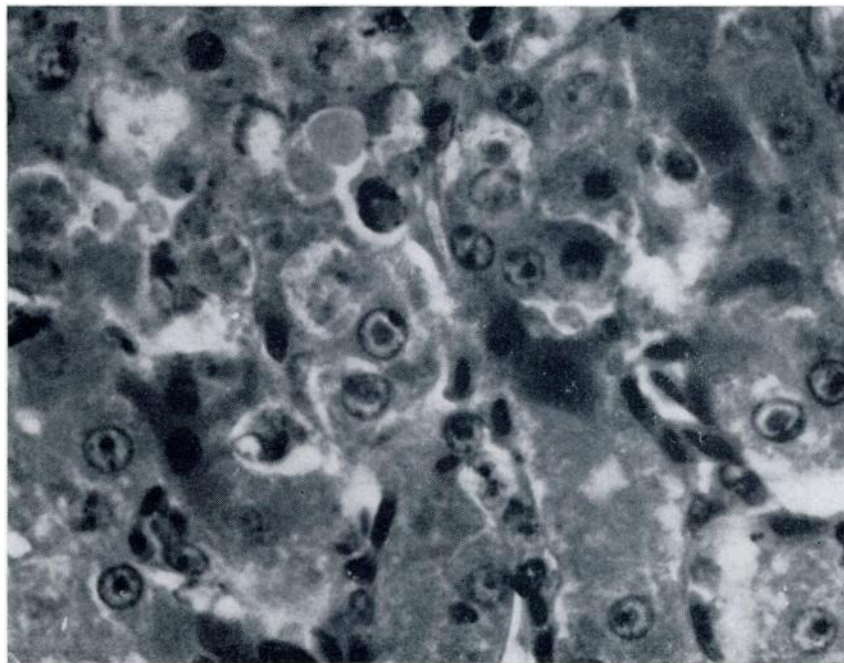


FIGURE 1. Liver of experimental owl with inclusion body disease. Note intranuclear inclusion bodies and necrotic hepatocytes in upper left hand quadrant. H and E, approx. X 400.

matous organs (liver, spleen, and tibial marrow) consisted of foci of caseous necrosis. Eosinophilic intranuclear inclusion bodies were present in either epithelial or reticulo-endothelial cells around the periphery of the lesions. Cellular inflammatory response to these lesions was not pronounced.

The first experimentally inoculated owl died 12 days after inoculation; the second owl was moribund 8 days after inoculation and was killed. Except that the first experimental owl developed a concomitant systemic mycotic infection, probably aspergillosis, necropsy and histological findings in both of these owls were very similar to the field case (Figure 1).

Electron microscopic examination of liver, spleen, and tibial marrow of the field case revealed numerous intranuc-

lear viral particles. The second experimentally inoculated owl was most suitable for electron microscopic study. Numerous viral particles identical to those in the field case were found in hepatocyte nuclei (Figure 2) and in spleen and tibial marrow. Viral cores, empty capsids and complete particles were present in hepatocyte nuclei and in unidentified nuclei in the spleen and marrow. The complete particles were approximately 85 nm in diameter. Masses of chromatin were centrally and peripherally located. Budding particles were numerous and in some cases were clearly bound by a membrane and were located in an evagination of the outer layer of the nuclear membrane (Figure 3). Enveloped particles were approximately 120-130 nm in diameter.

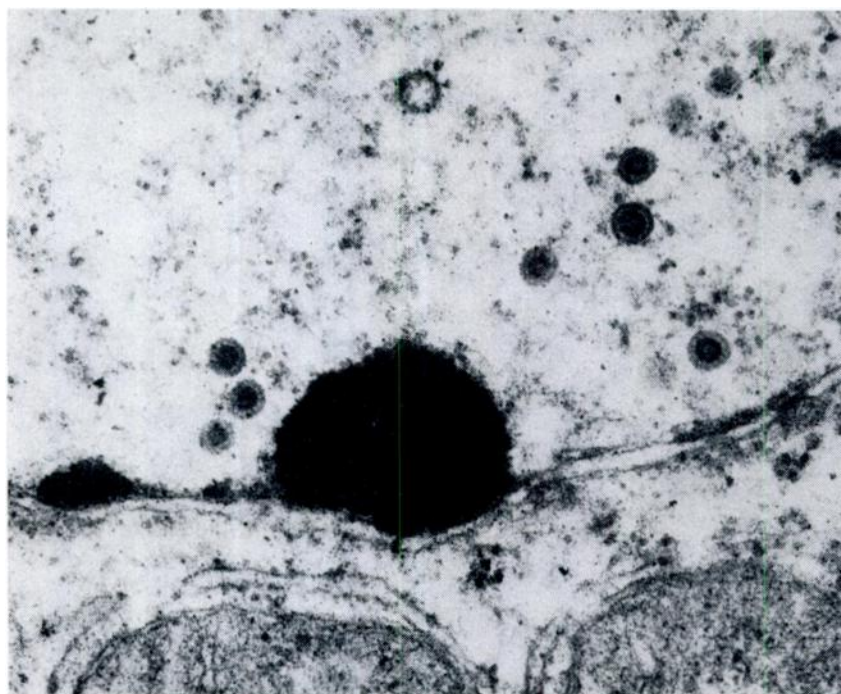


FIGURE 2. Empty capsid, nonenveloped herpesvirus particles (approximately 85 nm) and a peripheral mass of chromatin in the nucleus of a hepatocyte of an owl with experimental inclusion body disease. X 76,250.

A few poorly discernible viral particles were detected in initial attempts to demonstrate virus in the supernatant of homogenate of liver and spleen. Therefore DEF cell cultures were inoculated and while they were not stained to demonstrate inclusion bodies they did demonstrate a distinct CPE. Numerous viral particles with icosahedral nucleocapsid symmetry were recovered from the cells. The nucleocapsid diameter ranged from 108-115 nm and consisted of hollow capsomeres approximately 9 nm in diameter. The diameter of the envelope was 235-255 nm (Figure 4).

DISCUSSION

The presence of typical intranuclear inclusion bodies in lesions, the morphol-

ogy of the viral particles in electron micrographs and the presence of identical lesions and virus particles in both the field case and experimentally inoculated owls suggests a herpesvirus as the etiology of the disease. The importance of secondary bacterial invasion in the pathogenesis of the lesions was not determined. The significant necropsy and microscopic findings were identical to those reported by Green and Schillinger from the Wisconsin owl.⁴ The morphology of the virus was very similar to that reported by Burtscher and Schumacher for the Austrian eagle-owl virus.² The possibility exists that the same herpesvirus was involved in all three cases. It is surprising that this disease of owls went unreported in North America for the past 38 years.

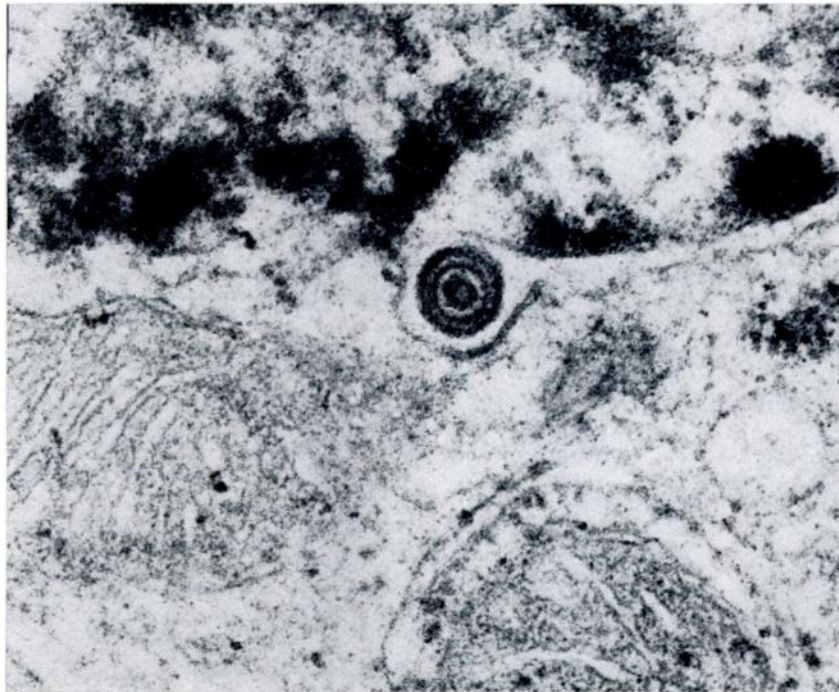


FIGURE 3. Enveloped herpesvirus particles (approximately 130 nm) located in an evagination of the outer nuclear membrane. X 95,000.

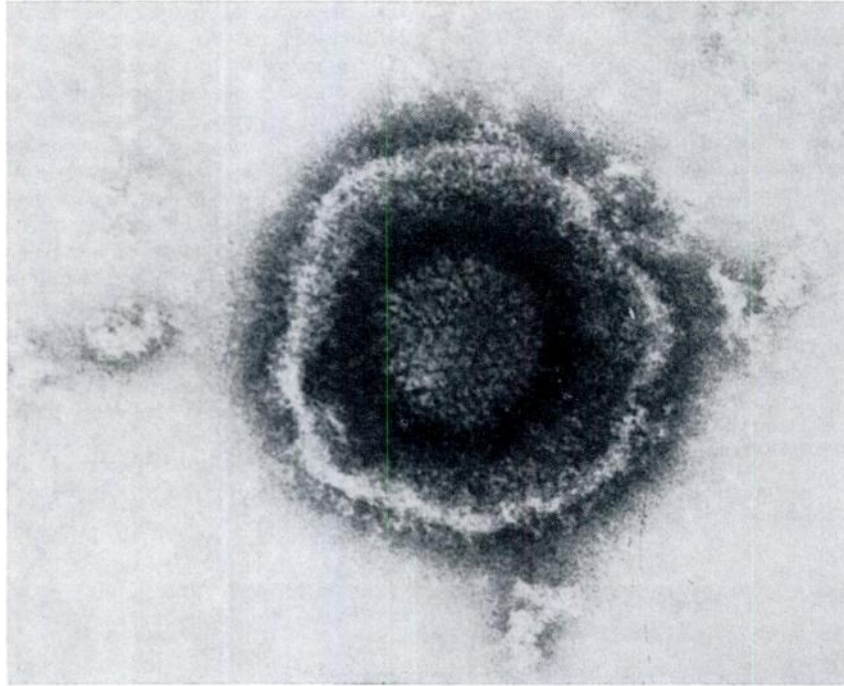


FIGURE 4. Negatively stained herpesvirus particle from duck embryo fibroblast culture inoculated with inclusion body disease agent. X 297,000.

Acknowledgements

Joel Tost of the Ontario Ministry of Natural Resources observed and captured the owl. John Klein of the Department of Pathology, prepared and processed tissues for electron microscopic examination, and Dr. K. Tsai, also of the Department of Pathology, assisted in interpreting the electron micrographs.

LITERATURE CITED

1. BORG, KARL and G. ROCKBORN. 1972. A brief report on virus hepatitis in the eagle owl. *Raptor Research* 6: 106-107.
2. BURTSCHER, H. and A. SCHUMACHER. 1966. Morphologische Untersuchungen zur Virusatologie der Hepatosplenitis Infectiosa Strigum. *Path. Vet.* 3: 506-528.
3. ERRINGTON, P. L. 1932. Great horned owls dying in the wild from diseases. *Wilson Bull.* 44: 180.
4. GREEN, R. G. and J. E. SCHILLINGER. 1936. A virus disease of owls. *Am. J. Path.* 12: 405-410.
5. MARE, C. J. and D. L. GRAHAM. 1973. Falcon herpesvirus, the etiologic agent of inclusion body disease of falcons. *Infect. Imm.* 118-126.
6. WARD, F. PRESCOTT, D. G. FAIRCHILD and J. V. VUICICH. 1971. Inclusion body hepatitis in a prairie falcon. *J. Wildl. Dis.* 7: 120-124

Received for publication 22 March 1974