

## **CYTOMEGALIC INCLUSION DISEASE IN THE EAST AFRICAN HEDGEHOG 1**

Author: KARSTAD, L.

Source: Journal of Wildlife Diseases, 11(2) : 187-188

Published By: Wildlife Disease Association

URL: <https://doi.org/10.7589/0090-3558-11.2.187>

---

The BioOne Digital Library (<https://bioone.org/>) provides worldwide distribution for more than 580 journals and eBooks from BioOne's community of over 150 nonprofit societies, research institutions, and university presses in the biological, ecological, and environmental sciences. The BioOne Digital Library encompasses the flagship aggregation BioOne Complete (<https://bioone.org/subscribe>), the BioOne Complete Archive (<https://bioone.org/archive>), and the BioOne eBooks program offerings ESA eBook Collection (<https://bioone.org/esa-ebooks>) and CSIRO Publishing BioSelect Collection (<https://bioone.org/csiro-ebooks>).

Your use of this PDF, the BioOne Digital Library, and all posted and associated content indicates your acceptance of BioOne's Terms of Use, available at [www.bioone.org/terms-of-use](http://www.bioone.org/terms-of-use).

Usage of BioOne Digital Library content is strictly limited to personal, educational, and non-commercial use. Commercial inquiries or rights and permissions requests should be directed to the individual publisher as copyright holder.

---

BioOne is an innovative nonprofit that sees sustainable scholarly publishing as an inherently collaborative enterprise connecting authors, nonprofit publishers, academic institutions, research libraries, and research funders in the common goal of maximizing access to critical research.

## CYTOMEGALIC INCLUSION DISEASE IN THE EAST AFRICAN HEDGEHOG<sup>†</sup>

L. KARSTAD,<sup>‡</sup> Veterinary Research Laboratory, P.O. Kabete, Kenya

**Abstract:** Cytomegaly with intranuclear inclusion bodies was found in the duct epithelium of the salivary glands of five of ten hedgehogs (*Atelerix albiventris*). Cytomegalovirus infection was presumed to be the cause.

### INTRODUCTION

Cytomegalovirus infections have been found in many species of mammals, including man.<sup>1</sup> These viruses can cause acute, systematic and fatal infections; however, the more common condition is chronic or latent infection of one or more organs of the body, as a sequel to an acute infection which may be mild or inapparent. The salivary glands are the most commonly identified sites of these latent infections, although other organs, particularly the kidneys, may support persistent cytomegalovirus infection. In latent infections, diagnosis may be done incidentally by finding the characteristic large inclusion-bearing cells in histologic sections of salivary glands or kidneys, or in urinary sediment.

### OBSERVATIONS

Ten adult free-living hedgehogs, captured in the vicinity of Kabete, Kenya, were included in a general survey of wildlife diseases. Routine histopathology of major body organs revealed focal collections of very large cells in the sub-mandibular salivary glands of five of the hedgehogs (in three of seven males and two of three females). These cells were obviously transformed cells of the duct epithelium (figure 1). They invariably

contained large eosinophilic intranuclear inclusions, which, together with the cytomegaly, were recognized as characteristic of cytomegalovirus infection. In some cases there was little or no reaction to the altered cells but in others, the islands of enlarged cells were surrounded by infiltrating lymphocytes (figure 2). In no case did the lesions seem to be sufficiently extensive to interfere with function of the glands. All of the affected animals were in good physical condition.

### DISCUSSION

Cytomegalovirus infections have been reported in several mammalian orders, including moles of the Order Insectivora.<sup>1</sup> Apart from their in vitro host range, the viruses are usually host-specific. Therefore, it is unlikely that a cytomegalovirus of the hedgehog, an insectivore, would be infective for taxonomically unrelated species. Because of the high natural rate of infection, however, this disease may be of value as a model for studies on this family of viruses.

Under natural conditions, these infections probably have little effect on their hedgehog hosts. One would expect, however, that generalized fatal cytomegalovirus infections might sometimes occur, particularly in neonatal animals, as they occur on occasion in other species.

<sup>†</sup> Research done in a project of the Government of Kenya, supported by the United Nations Development Fund, with the Food and Agriculture Organization of the United Nations as the executing agency. Published with approval of the Director of Veterinary Services, Kenya.

<sup>‡</sup> Present address: Dept. of Pathology, University of Guelph, Guelph, Ontario, Canada N1G 2W1.

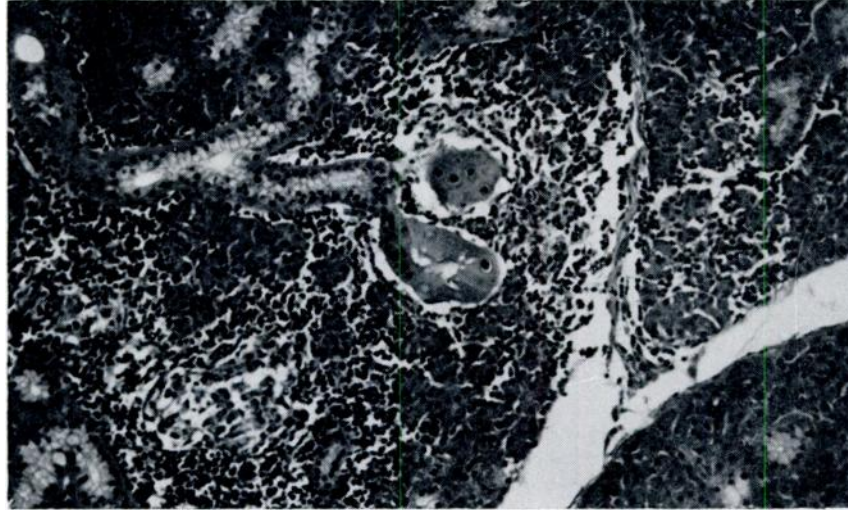


FIGURE 1. Cytomegaly and intranuclear inclusions in duct epithelium of the salivary gland of a hedgehog. Note transition from normal epithelium and infiltration with lymphocytes. Haematoxylin-eosin x 100.

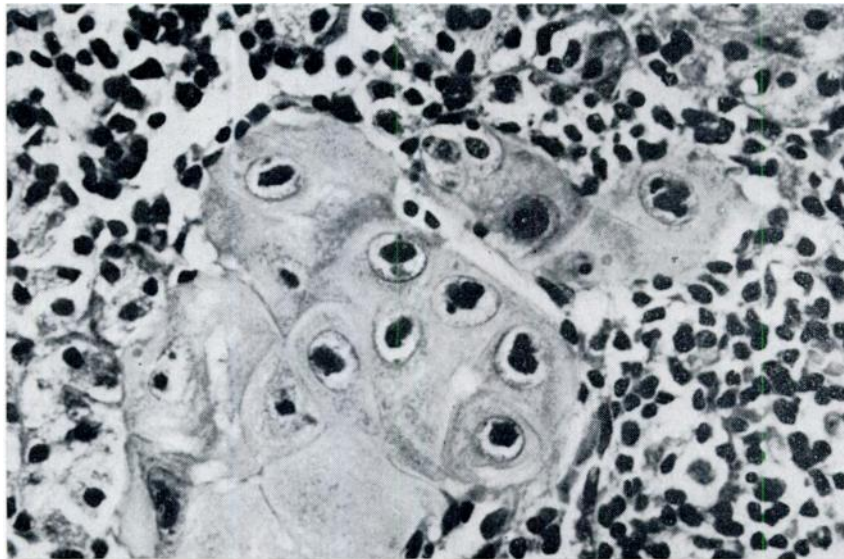


FIGURE 2. Prominent intranuclear inclusions in cytomegalic salivary duct epithelium. Basophilic nucleoli can be distinguished from the larger acidophilic inclusion bodies. Note pronounced lymphocytic infiltrate. Haematoxylin-eosin x 400.

#### LITERATURE CITED

1. HANSHAW, J. B. 1968. Cytomegaloviruses. *Viol. Monographs* 3: 1-23.

*Received for publication 8 July 1974*