



## **RADIOGRAPHIC EXAMINATION OF MANDIBULAR LESIONS IN BARREN-GROUND CARIBOU**

Authors: MILLER, F. L., CAWLEY, A. J., CHOQUETTE, L. P. E., and BROUGHTON, E.

Source: Journal of Wildlife Diseases, 11(4) : 465-470

Published By: Wildlife Disease Association

URL: <https://doi.org/10.7589/0090-3558-11.4.465>

---

BioOne Complete ([complete.BioOne.org](https://complete.BioOne.org)) is a full-text database of 200 subscribed and open-access titles in the biological, ecological, and environmental sciences published by nonprofit societies, associations, museums, institutions, and presses.

Your use of this PDF, the BioOne Complete website, and all posted and associated content indicates your acceptance of BioOne's Terms of Use, available at [www.bioone.org/terms-of-use](https://www.bioone.org/terms-of-use).

Usage of BioOne Complete content is strictly limited to personal, educational, and non - commercial use. Commercial inquiries or rights and permissions requests should be directed to the individual publisher as copyright holder.

---

BioOne sees sustainable scholarly publishing as an inherently collaborative enterprise connecting authors, nonprofit publishers, academic institutions, research libraries, and research funders in the common goal of maximizing access to critical research.

## RADIOGRAPHIC EXAMINATION OF MANDIBULAR LESIONS IN BARREN-GROUND CARIBOU

F. L. MILLER,<sup>1</sup> A. J. CAWLEY,<sup>2</sup> L. P. E. CHOQUETTE<sup>1</sup> and E. BROUGHTON<sup>1</sup>

**Abstract:** Dental anomalies were observed in 43 of 1,226 barren-ground caribou (*Rangifer tarandus groenlandicus*) taken between 1966 and 1968. In five of these 43 animals, the mandibles had deformities which radiography showed to be the result of dental abscesses in four cases and probably of a trauma in the other.

The absence of actinomycotic lesions of the jaw bones of these 1,226 animals, and of more than 500 examined previously, indicates that "lumpy jaw" is rare in barren-ground caribou.

The authors suggest the use of radiography to determine the nature of bone growth on skeletal remains, in the absence of soft tissues for examination for *Actinomyces*, either microscopically or by cultural methods.

### INTRODUCTION

The skulls of 1,226 barren-ground caribou taken between 1966 and 1968 were examined for dental anomalies and deformities. Banfield<sup>2</sup> suggested that mandibular anomalies he had noted in barren-ground caribou were of actinomycotic origin. This note deals with the nature and probable cause of mandibular deformities noted in the skulls examined.

### MATERIALS AND METHODS

The sample collected between April 1966 and August 1968 consisted of the skulls of 1,176 caribou frequenting the mainland range west of Hudson Bay, and of 50 caribou taken in north-central Baffin Island. Nearly 52% of the 1,176 animals taken on the mainland were juveniles or sub-adults, 41 months of age or less, whereas the adult segment was represented mostly by animals 4 to 6 years old with a few 10 or more years old. The oldest animals were a 142 month-old male and a 205 month-old female.

The mandibles were separated from the skull and freed of soft tissue and

foreign matter. Mandibular and dental anomalies detected while measuring the mandibles or studying the eruption and wear patterns of the teeth were recorded. The associated maxillae and teeth were also examined for evidence of trauma. Mandibles showing deformities were radiographed.

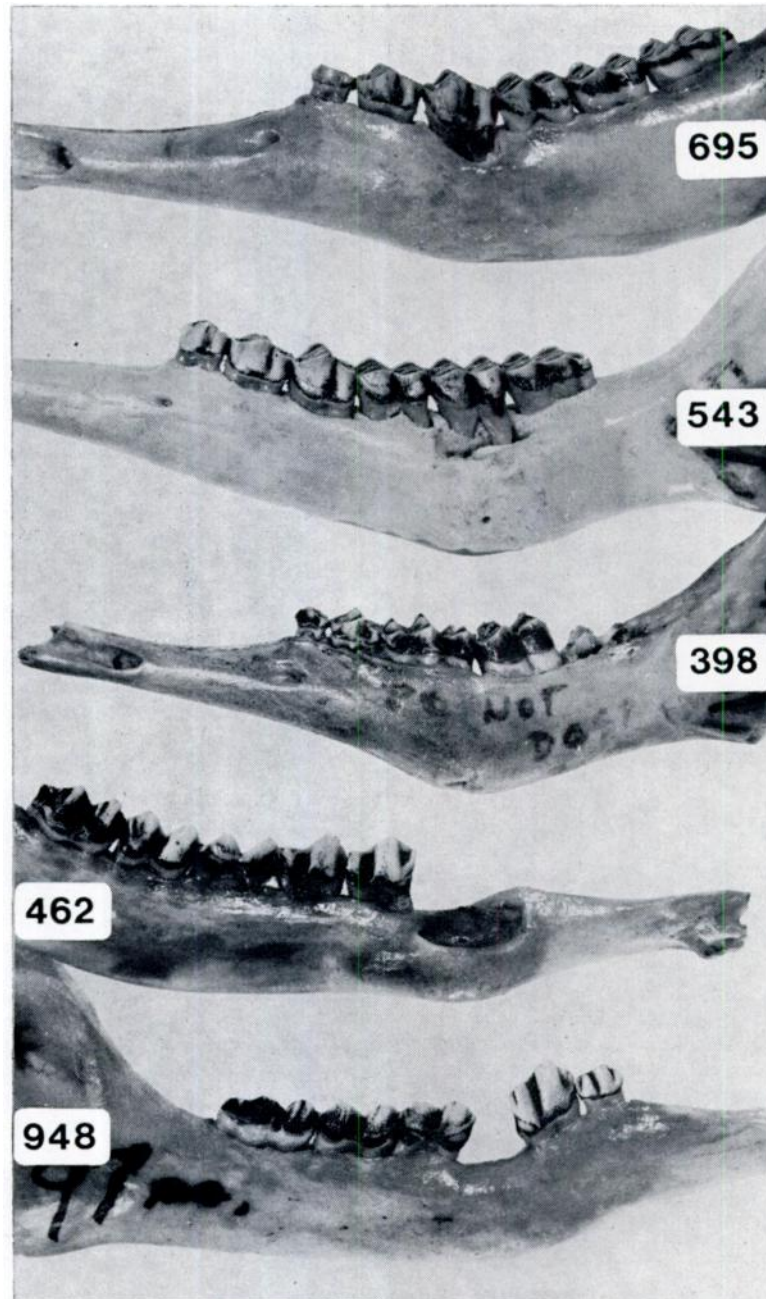
### RESULTS

Dental anomalies were found in 43 of the 1,226 caribou skulls examined. This has been the subject of a report by Miller and Tessier.<sup>10</sup>

In five of the 43 animals, the mandibles had deformities similar to those illustrated by Banfield<sup>2</sup> who considered such anomalies to be of actinomycotic origin. The defects were in the form of thickening of the mandibular shaft in four cases, and of a bony exostosis in the other. The gross and radiological changes seen in the five jaw specimens seem to represent varying stages of dental abscessation in four cases (#695, 543, 398, 462) and the effect of a trauma in the other (#948) (Figs. 1 and 2).

<sup>1</sup> Canadian Wildlife Service, Ottawa, Ontario, Canada.

<sup>2</sup> 6293 Quinpool Road, Halifax, Nova Scotia, Canada.



Specimen no. 695 (89-month-old female) had periosteal new bone on the ventral, medial and lateral aspects of the mandibular shaft, at the site of the fourth premolar (p4), with a sinus tract leading from the caudal root of that tooth to the medial surface of the mandible. Radiologically, bone absorption and formation of a cavity had occurred between the cranial and caudal roots of p4. The caudal root of the tooth does not have adjacent alveolar bone, it lies within the cavity (Fig. 2).

Specimen no. 543 (111-month-old female) had absorption of bone from around the roots of the second molar (m2), a sequestrum lateral to this tooth and periosteal new bone on the surfaces of the mandibular shaft. Radiographically, alveolar bone has been absorbed from around all roots of m2, the caudal root of the first molar (m1) and the cranial root of the third molar (m3). Cavitation of the bone had occurred ventral to m2 with periosteal new bone on the ventral surface of the mandibular shaft (Fig. 2).

Specimen no. 398 (10-month-old female) had essentially similar gross and radiographical findings as no. 543, with a sinus tract from the interdental ridge of p4, m1, adjacent to the root of p4, through to the ventral surface of the mandible (Fig. 2).

Specimen no. 462 (84-month-old female) had mandibular enlargement on

all surfaces at the level of the second premolar (p2), which was missing. The radiograph shows the absence of p2 with an alveolus filled with cancellous bone, periosteal new bone on the ventral surface of the mandible and absorption of bone from around the cranial root of the third premolar (p3) (Fig. 2). These findings represent old inflammatory changes involving p2, which has been lost, and active inflammatory changes affecting the cranial root of p3. An old dental abscess with bone remodelling is the logical conclusion. Specimen no. 948 (97-month-old-female) had the p4 absent with minimal erosion of the alveolar border of the mandible and minimal periosteal bone on the ventral surface of the bone. The limited bone destruction and periosteal bone formation suggest that the tooth was not lost because of dental abscessation-trauma would seem a more likely explanation (Fig. 2).

#### DISCUSSION

In North America, actinomycosis, "lumpy jaw", has been reported in captive and in free-living Cervidae by Fox,<sup>6</sup> Cowan,<sup>3,4</sup> Honess and Winter,<sup>8</sup> Trainer<sup>12</sup> as well as by other authors cited by Pier.<sup>10</sup> As far as we can ascertain, there are only two reports referring to the disease in caribou in Canada. Cowan<sup>3</sup> stated that actinomycosis was much less serious in caribou than in bighorn sheep,

FIGURE 1. Barren-ground caribou mandibles with deformities attributed to dental abscesses in four cases and to trauma in case of caribou no. 948.

#695—Thickening of the mandibular shaft at the level of the fourth premolar and mandibular cavitation around and between the roots of the fourth premolar.

#543—Bony exostosis of rounded conformation, approximately 5 cm in length on lateral aspect of the mandible at the level of the second molar.

#398—Massive enlargement of the left mandible at the level of the fourth premolar and first molar.

#462—Mandibular enlargement on all surfaces at the level of second premolar which is missing. Cranial root of the third premolar exposed.

#948—Fourth premolar missing and alveolus filled with bone. Medial aspect of the ventral border of the mandible is thickened at the level of the missing tooth.

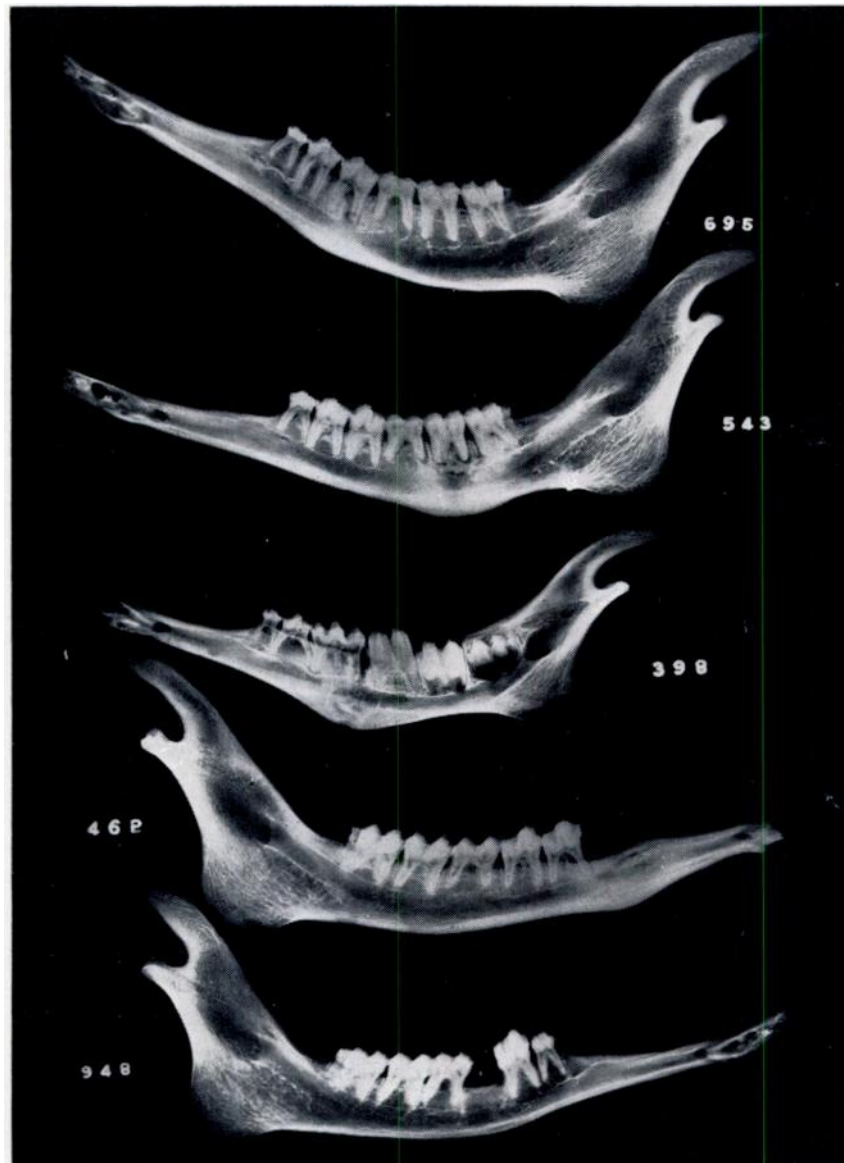

FIGURE 2. Radiographs of the barren-ground caribou mandibles shown in Fig. 1. (see Results for description of radiographic findings).

and Banfield<sup>2</sup> reported that eight mandibles of 380 skulls found on the barren-ground caribou range had lesions (necrosis of alveoli and exostoses) he considered indicative of a disease similar to actinomycosis. He also considered the disease to be widespread in caribou; how-

ever, his photographs of mandibles and his description of the anomalies leave little doubt that the defects were similar to those recorded in the present study. Gibbs<sup>7</sup> did not encounter any lesions suggesting actinomycosis in approximately 150 barren-ground caribou examined

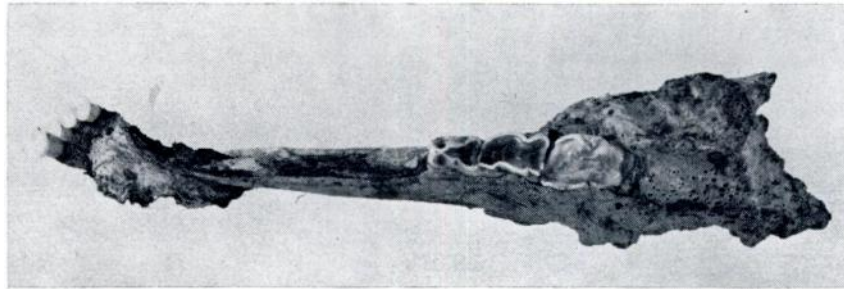


FIGURE 3. Fragment of fractured elk mandible with bone growth suggestive of actinomycosis.

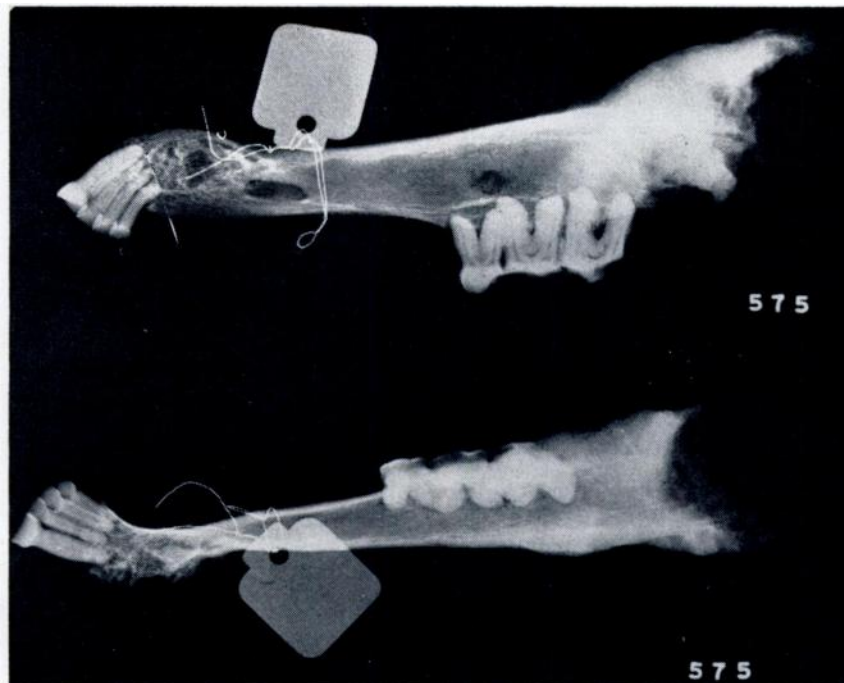


FIGURE 4. Radiograph of bone growth on fragmented elk mandible shown in Fig. 3. It shows the internal honeycombed appearance of the bone and its cavitation at the level of the fracture, which are characteristic of actinomycosis.

in 1957-58. Most biologists who have examined caribou or skeletal remains of caribou have not recorded evidence suggestive of the disease. The foregoing and the present study of more than 1,700 animals support the view that actinomycosis, if it occurs at all, is indeed a rare entity in barren-ground caribou.

As pointed out by Pier<sup>11</sup> many reports of actinomycosis in wildlife are not clinically well-documented. Shahan and Davis,<sup>12</sup> Drake,<sup>5</sup> Ainsworth and Austwick<sup>1</sup> insisted on the necessity of laboratory examinations to confirm the clinical diagnosis of the disease. We agree with Drake<sup>5</sup> that diagnosis on the basis of bone growth, is open to question, even

if the growth resembles the spongy bone typically found in actinomycosis. However, in the absence of soft tissues for examination, either microscopically or by cultural methods, the actinomycotic nature of bone growth (Fig. 3) can be determined radiographically by its internal honeycombed appearance (Fig. 4) resulting from the erosion of the bone and the deposition of new bone replacing the tissue destroyed by necrosis following invasion by *Actinomyces*. The value of radiography for this purpose is evident. Conceivably, this could lead to better statistics on the distribution and incidence of actinomycosis in some free-living wildlife species.

#### LITERATURE CITED

1. AINSWORTH, G. C. and P. K. C. AUSTWICK. 1959. Fungal diseases of animals. Commonwealth Agric. Bureau An. Health. Revue Series no. 6: 64-68.
2. BANFIELD, A. W. F. 1954. Preliminary investigation of the barren-ground caribou. Canadian Wildlife Service, Wildlife Manage. Bull., Ser. 1, 10B: 1-112.
3. COWAN, I. Mct. 1946. Parasites, diseases, injuries and anomalies of the Columbian black-tailed deer, *Odocoileus hemionus columbianus* (Richardson), in British Columbia. Can. J. Res., D 24: 71-103.
4. ———. 1951. The diseases and parasites of big game mammals of western Canada. Proc. 5th. Ann. B.C. Game Convention. 37-64.
5. DRAKE, C. H. 1951. Mistaken diagnosis of actinomycosis for osteogenic sarcoma in an American elk (*Cervus canadensis*). J. Wildl. Manage. 15: 284-287.
6. FOX, H. 1923. Disease in captive wild mammals and birds. Philadelphia, London and Chicago. J. B. Lippincott Company.
7. GIBBS, H. C. 1960. Disease investigation of barren-ground caribou. In (App. 1, pp. 119-132). Cooperative studies of barren-ground caribou, 1957-58 by J. P. Kelsall. Canadian Wildlife Service, Wildlife Manage. Bull., Ser. 1, 15: 145.
8. HONESS, R. F. and K. B. WINTER. 1956. Diseases of Wildlife in Wyoming. Wyoming Game Fish Comm. Bull. 9. 279 pp.
9. HOWE, D. L. 1970. Miscellaneous bacterial diseases: vibriosis, actinomycosis, blackleg and malignant edema, pp. 376-381. In: *Infectious Diseases of Wild Mammals*. eds. J. W. Davis et al., Iowa State University Press, Ames, Iowa.
10. MILLER, F. L. and G. D. TESSIER. 1971. Dental anomalies in caribou, *Rangifer tarandus*. J. Mammal. 52: 164-174.
11. PIER, A. C. 1962. Mycotic diseases of deer. Proceeding 1st National white-tailed deer disease symposium. The University of Georgia, Center for Continuing Education, Athens, Georgia. Feb. 13-15. 202 pp.
12. SHAHAN, M. S. and C. L. DAVIS. 1942. The diagnosis of actinomycosis and actinobacillosis. Am. J. vet. Res. 3: 321-329.

Received for publication 4 February 1975