

## HEPATITIS IN SKUNKS CAUSED BY THE VIRUS OF INFECTIOUS CANINE HEPATITIS

Authors: KARSTAD, L., RAMSDEN, R., BERRY, T. J., and BINN, L. N.

Source: Journal of Wildlife Diseases, 11(4) : 494-496

Published By: Wildlife Disease Association

URL: <https://doi.org/10.7589/0090-3558-11.4.494>

---

The BioOne Digital Library (<https://bioone.org/>) provides worldwide distribution for more than 580 journals and eBooks from BioOne's community of over 150 nonprofit societies, research institutions, and university presses in the biological, ecological, and environmental sciences. The BioOne Digital Library encompasses the flagship aggregation BioOne Complete (<https://bioone.org/subscribe>), the BioOne Complete Archive (<https://bioone.org/archive>), and the BioOne eBooks program offerings ESA eBook Collection (<https://bioone.org/esa-ebooks>) and CSIRO Publishing BioSelect Collection (<https://bioone.org/csiro-ebooks>).

Your use of this PDF, the BioOne Digital Library, and all posted and associated content indicates your acceptance of BioOne's Terms of Use, available at [www.bioone.org/terms-of-use](http://www.bioone.org/terms-of-use).

Usage of BioOne Digital Library content is strictly limited to personal, educational, and non-commercial use. Commercial inquiries or rights and permissions requests should be directed to the individual publisher as copyright holder.

---

BioOne is an innovative nonprofit that sees sustainable scholarly publishing as an inherently collaborative enterprise connecting authors, nonprofit publishers, academic institutions, research libraries, and research funders in the common goal of maximizing access to critical research.

## HEPATITIS IN SKUNKS CAUSED BY THE VIRUS OF INFECTIOUS CANINE HEPATITIS

L. KARSTAD,<sup>1</sup> R. RAMSDEN,<sup>2</sup> T. J. BERRY<sup>1</sup> and L. N. BINN<sup>3</sup>

**Abstract:** Two cases of acute, fatal, hepatitis occurred in young, striped skunks (*Mephitis mephitis*) trapped in southern Ontario. Histologically, lesions in the liver were similar to infectious canine hepatitis. A virus was isolated which produced large intranuclear inclusions in dog kidney cell cultures. These inclusions were Feulgen-positive and fluoresced green with acridine orange stain. The skunk hepatitis isolate was identified as the virus of infectious canine hepatitis by virus neutralization tests.

### CASE HISTORIES

In July, 1971, a litter of five baby skunks, a few weeks old, was presented to a humane society animal shelter in southern Ontario. These skunks had been taken captive near Stoney Creek, Ontario, when the mother skunk was killed. Some of the young were said to show ocular discharge and depression when captured and four of the five skunks died within a day. These were not presented for diagnosis. The surviving skunk, a male, was taken to a nearby wildlife sanctuary. Within 24 h it developed diarrhea, purulent ocular discharge and died.

On arrival at the sanctuary the skunk had been allowed approximately 15 min contact with a young female skunk, of about the same size, that had recently been captured within the city of Guelph. Six days later this second skunk developed inappetance and depression. Two days after disease onset the skunk died.

### MATERIALS AND METHODS

Both skunks were examined by necropsy and histopathology. Supernatant fluids from ground liver tissue suspensions were inoculated onto monolayer cultures of primary dog kidney cells.

Cell cultures and histologic sections of the skunk livers were stained by the Feulgen technique and with acridine orange for fluorescence microscopy. A viral agent isolated in dog kidney cells was identified by neutralization tests with virus-specific antiserum.<sup>3</sup>

### RESULTS

Gross lesions in the male skunk were limited to the liver, which was olive brown and had 1 mm darker spots scattered over the surface of all lobes. The female, presented at death 8 days later, was grossly normal except for slightly enlarged kidneys and adrenals.

Histopathology revealed very large deeply acidophilic or basophilic inclusions in the nuclei of hepatic cells in both cases (Figure 1). In the female, similar inclusions also were present in cells of the bile duct epithelium and the adrenal cortex. The intranuclear inclusions stained red by the Feulgen procedure. Other lesions were necrosis of hepatic and renal tubular epithelial cells, and in the male skunk, infiltrations of mononuclear leukocyte in periportal tissues and in the lungs and meninges. The female skunk had evidence of terminal bacterial embolism involving the brain, heart and kidney.

<sup>1</sup> Department of Pathology, University of Guelph, Guelph, N1G 2W1, Canada.

<sup>2</sup> Ontario Ministry of Natural Resources, Research Branch, Maple, Ontario, Canada.

<sup>3</sup> Walter Reed Army Institute of Research, Washington, D.C. 20012, USA.

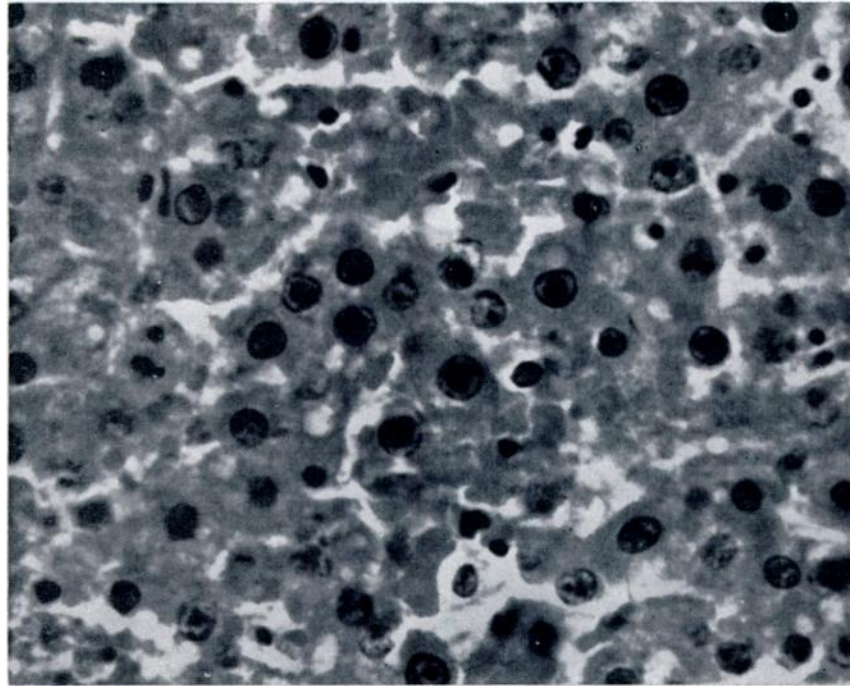


FIGURE 1. Intranuclear inclusions in hepatic cells. Skunk liver. Hematoxylin-eosin X 800.

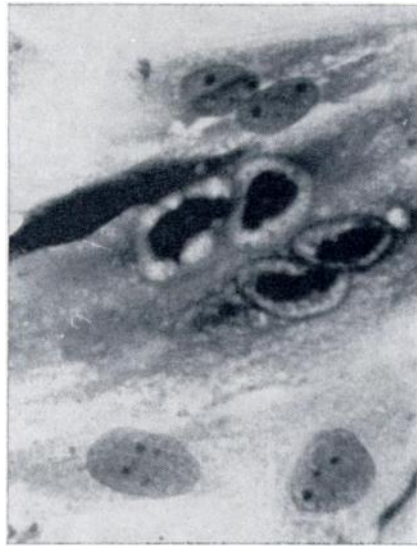

FIGURE 2. Dog kidney cell culture 72 h after inoculation with skunk liver tissue suspension. Note intranuclear inclusions. Giemsa X 800.

Primary dog kidney cells exposed to supernatant fluids from 10% liver suspensions had maximum numbers of intranuclear inclusions at 72-96 h after exposure (Figure 2). The inclusions stained a deep purplish-red with Giemsa. When stained with acridine orange and stained with ultraviolet illumination, inclusions fluoresced bright green.

When the skunk isolate was tested for neutralization by an infectious canine hepatitis antiserum, in parallel with the Cornell strain of ICH virus, both viruses had a neutralization index of 320. There was a lesser cross-reaction with another canine adenovirus, strain A26/61 (Table 1).<sup>4</sup>

A diagnosis of ICH was made on the basis of (1) the intranuclear inclusion bodies in liver cells, (2) propagation of the isolates in dog kidney cells in which intranuclear inclusions were produced, and (3) neutralization of the isolates with ICH antiserum.

TABLE 1. Results of Cross-Neutralization Tests Between the Skunk Isolate and Canine Adenoviruses.

Antigen <sup>a</sup>	Antiserum	
	ICH	A 26/61
Skunk	320	20
ICH (Cornell)	320	80
A 26/61 (F 346)	40	640

<sup>a</sup>Log virus dose was 2.0 for ICH and skunk isolate and 1.0 for the ICH-like virus A 26/61.

#### DISCUSSION

The only previous report of ICH in skunks was of two ICH virus isolates from the pooled liver and spleen tissues of two striped skunks trapped in Maryland.<sup>1</sup> One of the two skunks had pinpoint hemorrhages in the lungs, the other appeared normal. Fifty-nine of 94 skunks

trapped in the Maryland survey had antibodies to ICH virus. The present report indicates that fatal infections can occur in skunks, and confirms that the striped skunk can be a natural wildlife host for ICH virus. In addition to skunks, ICH is known to occur in foxes,<sup>3</sup> and there is evidence of infection in raccoons.<sup>3,5</sup>

#### LITERATURE CITED

1. ALEXANDER, A. D., V. FLYGER, Y. F. HERMAN, S. J. McCONNELL, N. ROTHSTEIN and R. H. YAGER. 1972. Survey of wild mammals in Chesapeake Bay area for selected zoonoses. *J. Wildl. Dis.* 8: 119-126.
2. BINN, L. N., G. A. EDDY, E. C. LAZAR, J. HELMS and T. MURNAME. 1967. Viruses recovered from laboratory dogs with respiratory disease. *Proc. Soc. exptl. Biol. Med.* 128: 140-145.
3. CABASSO, V. J. 1970. Infectious canine hepatitis. In *Infectious Diseases of Wild Mammals*. J. W. Davis *et al.* (eds.) Iowa State Univ. Press, Ames, Iowa. pp. 134-139.
4. DITCHFIELD, J., L. W. MacPHERSON and AUDREY ZBITNEW. 1962. Association of a canine adenovirus (Toronto A26/61) with an outbreak of laryngotracheitis ("kennel cough"). *Can. vet. J.* 3: 238-247.
5. JAMISON, R. K., E. C. LAZAR, L. N. BINN and A. D. ALEXANDER. 1973. Survey for antibodies to canine viruses in selected wild mammals. *J. Wildl. Dis.* 9: 2-3.

Received for publication 13 January 1975