

AN OUTBREAK OF TOXOPLASMOSIS IN WALLAROOS (*Macropus robustus*) IN A CALIFORNIA ZOO

Authors: BOORMAN, G. A., KOLLIAS, G. V., and TAYLOR, R. F.

Source: Journal of Wildlife Diseases, 13(1) : 64-68

Published By: Wildlife Disease Association

URL: <https://doi.org/10.7589/0090-3558-13.1.64>

The BioOne Digital Library (<https://bioone.org/>) provides worldwide distribution for more than 580 journals and eBooks from BioOne's community of over 150 nonprofit societies, research institutions, and university presses in the biological, ecological, and environmental sciences. The BioOne Digital Library encompasses the flagship aggregation BioOne Complete (<https://bioone.org/subscribe>), the BioOne Complete Archive (<https://bioone.org/archive>), and the BioOne eBooks program offerings ESA eBook Collection (<https://bioone.org/esa-ebooks>) and CSIRO Publishing BioSelect Collection (<https://bioone.org/csiro-ebooks>).

Your use of this PDF, the BioOne Digital Library, and all posted and associated content indicates your acceptance of BioOne's Terms of Use, available at www.bioone.org/terms-of-use.

Usage of BioOne Digital Library content is strictly limited to personal, educational, and non-commercial use. Commercial inquiries or rights and permissions requests should be directed to the individual publisher as copyright holder.

BioOne is an innovative nonprofit that sees sustainable scholarly publishing as an inherently collaborative enterprise connecting authors, nonprofit publishers, academic institutions, research libraries, and research funders in the common goal of maximizing access to critical research.

AN OUTBREAK OF TOXOPLASMOSIS IN WALLAROOS (*Macropus robustus*) IN A CALIFORNIA ZOO

G. A. BOORMAN,^[1] G. V. KOLLIAS^[2] and R. F. TAYLOR^[3]

Departments of Pathology^[1] and Medicine,^[2] School of Veterinary Medicine,

University of California, Davis, California 95616, USA,

and the Provincial Veterinary Laboratory, Abbotsford, British Columbia, Canada^[3]

(Present address)

Abstract: Four wallaroos (*Macropus robustus*) from a central California zoo colony of 22 died within a three week period. Histopathologic findings in all four cases were suggestive of toxoplasmosis. Brain, lung and heart were the most frequently involved organs. Within 4 months of the last death sera from nine colony members were tested for antibodies against *Toxoplasma gondii* using the indirect hemagglutination test. All nine had serological titers ranging from 1:64 to 1:131,072.

INTRODUCTION

Few reports are available on diseases affecting macropod marsupials (kangaroos, wallabies and wallaroos) in captivity. In a report on the diseases of Australian laboratory marsupials, nocardiosis was the most common fatal disease,¹ but several sporadic cases of toxoplasmosis also have been noted, usually involving kangaroos.^{3,4,6,8,11} In one serologic study, evidence of toxoplasmosis was not found in kangaroos in their native habitat.² In a recent survey of exotic animals in zoos and in private ownership, serologic evidence of infection with *Toxoplasma gondii* was found in 33% of the animals.⁹ Twelve wallaroos were included in this study and six were seropositive with titers ranging from 1:128 to 1:2048.⁹ Recently, four wallaroos from a central California zoo were submitted for necropsy within a three week period. This report presents the pathology of toxoplasmosis in these wallaroos.

HISTORY

A colony of approximately 22 wallaroos (*Macropus robustus*) has been maintained at a central California zoo for 35 years. Colony size is maintained by selling 4 to 6 animals per year. The

only recent introduction was a male wallaroo obtained from a Texas zoo in 1971. During the fall of 1974 they were moved to a new enclosure that is partially shaded and the ground is bare of vegetation. Water is supplied in a low trough and pelleted alfalfa is fed *ad libitum*. Animals showing clinical signs receive veterinary care while those found dead are submitted to the Department of Pathology, School of Veterinary Medicine, University of California (UCVM) for thorough necropsy. Sporadic deaths have occurred and necropsy reports from this zoo were found by reviewing the UCVM pathology files for the past ten years. The mortalities were random and were attributable to a variety of causes.

Recently, four wallaroos died within a three week period. On 8 March 1975 an adult female wallaroo was found dead without prior clinical signs and was submitted for necropsy. Her offspring (approximately 5 months old) was removed from the group for hand-rearing. The following week, two 6 month old wallaroos were found dead, also without prior clinical signs, and submitted for necropsy. On 29 March the joey died. It had been doing poorly, had intermittent diarrhea and sustained a weight loss. After gross examination, selected tissues were fixed in 10% buffered formalin,

embedded in paraffin, sectioned and routinely stained with hematoxylin and eosin. Selected tissues also were stained with periodic acid-Schiff (PAS), gram-Weigert, Giemsa and Goodpasture.

Within 4 months following the last death, blood was randomly collected from nine wallaroos, allowed to clot, and the serum tested at dilutions ranging from 1:64 to the end point for antibodies against *Toxoplasma gondii* using the indirect hemagglutination (IHA) test.^{5,7}

In early July 1975, a feral female short hair cat (*Felis domesticus*) was seen in the feed trough in the wallaroo enclosure. The animal was caught and kept for observation to determine if she was shedding oocysts and/or had a positive titer for toxoplasmosis.

RESULTS

Pathology

The gross findings in all four wallaroos were minimal except for the respiratory system. Lungs tended to be mottled red-pink, heavy and wet. In two cases portions of the pulmonary tissue sank when placed in formalin.

Histopathologic examination revealed diffuse toxoplasmosis in the three young animals and minimal lesions in the adult female. Organisms occurred either individually in the tissue (Fig. 1), within the cytoplasm of macrophages, or within a structure with a defined wall (Fig. 2).

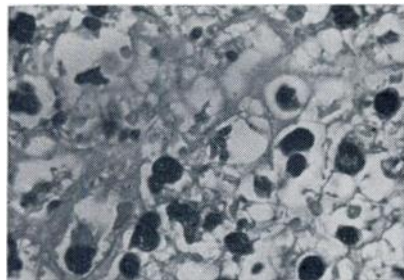


FIGURE 1. *Toxoplasma* organisms in a lymph node of a 6 month old wallaroo (hematoxylin and eosin, original magnification 1000X).

Toxoplasma organisms were found in the lung in all four cases (Fig. 3). Extensive necrosis and fibrin exudation often were found in association with the organisms. An infiltrate of mononuclear cells and fibrin in alveoli also were found (Fig. 4). In the three young animals the brain contained multiple glial nodules (Fig. 5) and occasional *Toxoplasma* cysts were found in the glial nodules (Fig. 6). The brain of the adult was not examined. A review of the slides from necropsy cases of wallaroos from the past 10 years failed to reveal any additional cases of toxoplasmosis, nor was *Toxoplasma* found in animals dying since the outbreak.

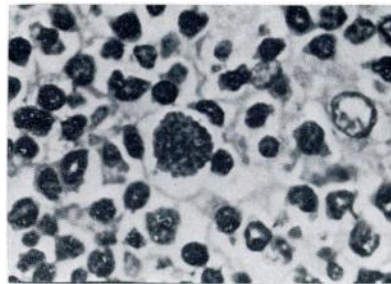


FIGURE 2. Lymph node from a 6 month old wallaroo containing a *Toxoplasma* cyst (hematoxylin and eosin, original magnification 1000X).

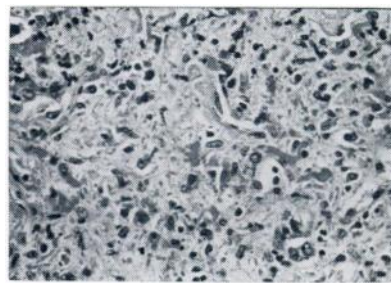


FIGURE 3. Lung from wallaroo showing marked accumulation of cells and protein rich fluid in alveoli. Note *Toxoplasma* cyst (arrow) (hematoxylin and eosin, original magnification 250X).

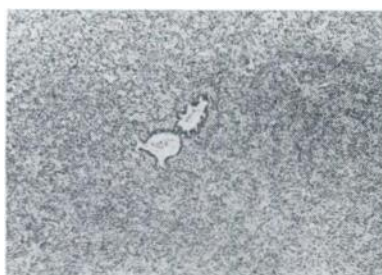

FIGURE 4. Lung from wallaroo showing diffuse pulmonary involvement (hematoxylin and eosin, original magnification 25X).

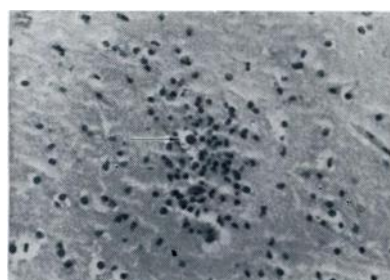

FIGURE 6. Brain of a 6 month old wallaroo with a glial nodule. Note *Toxoplasma* cyst (arrow) (hematoxylin and eosin, original magnification 250X).



FIGURE 5. Brain from a 6 month old wallaroo showing glial nodules (hematoxylin and eosin, original magnification 100X).

Serology

All nine wallaroos were positive for antibodies directed against *gondii* using the IHA test as shown in Table 1. Titers ranged from 1:64 to 1:131,074. One animal tested twice showed a rising titer.

The feral cat caught in the wallaroo enclosure was examined for serologic evidence of toxoplasmosis by the IHA method. Two serum samples, taken over a three week period, were both negative.

TABLE 1. Indirect hemagglutination antibody titers to *Toxoplasma gondii* in Wallaroos (*Macropus robustus*).

| Animal Identification | Sex | Titer* |
|-----------------------|-----|---------|
| 96 | F | 131,072 |
| 97 | F | 2,048 |
| 98 | F | 16,384 |
| 100 | F | 4,096 |
| 100** | F | 32,768 |
| 103 | F | 32,768 |
| 110 | F | 32,768 |
| 117 | M | 512 |
| 86 | F | 512 |
| Offspring of 86 | | 64 |

* Reciprocal serum titer

** Same animal sampled two months later

DISCUSSION

Generally, reports of toxoplasmosis in macropods involve isolated cases and we are aware of only one report in a wallaroo.⁸ In this outbreak, all four cases occurred within three weeks. We have no evidence of toxoplasmosis in animals dying in the previous years and no new cases have occurred in this colony in the past year. This would suggest either a common source of infection or some factor precipitating the disease. Six of 12 wallaroos from the colony had serologic evidence of infection in 1973⁹ indicating that this was not the first exposure to *Toxoplasma* and toxoplasmosis had been reported in Pallas cats (*Felis manul*) from this same zoo.¹⁰

Feral domestic cats have been observed occasionally in the wallaroo enclosure and are certainly a possible source of exposure, although the cat examined was negative. A recent survey

of domestic cats in this area revealed that approximately 14% are seropositive for toxoplasmosis (Riemann, H. P. and Behymer, D. E., personal communication).

Three of the four wallaroos were six months of age or less, indicating that the infection may have taken place *in utero* or neonatally. Additional evidence is the finding of *Toxoplasma* in the mother of one of the dead infants. A case of toxoplasmosis involving mother and infant also has been reported in a kangaroo.³

In a recent report, 33% of captive exotic mammals were seropositive for *Toxoplasma*.⁹ It would seem that the true extent of this disease in our zoo populations is not fully appreciated. Necropsies of animals dying in zoos and serological surveys will help define the problem, but epizootiological studies are needed to pinpoint sources of spread and thus suggest methods of prevention.

Acknowledgements

We are grateful to Dr. H. P. Riemann and D. E. Behymer, Department of Epidemiology and Preventive Medicine, School of Veterinary Medicine, University of California, for performing the serological assays for *Toxoplasma* titers and also to Dr. M. E. Fowler, for helpful advice.

LITERATURE CITED

1. BARKER, S., J. H. CALABY and G. B. SHARMAN. 1963. Diseases of Australian marsupials. Vet. Bull. 33: 539-544.
2. COOK, I. and J. H. POPE. 1959. *Toxoplasma* in Queensland. III. A preliminary survey of animal hosts. Aust. J. Exp. Biol. Med. Sci. 37: 253-263.
3. GRUNBERG, W. 1953. Toxoplasmose beim Bennett-Kanguruh (*Macropus bennetti* Gould) und einem Klippschliefer (*Hyrax syriacus* Schreb). Wein. Tierartl. Msch. 46: 586-593.
4. HACKEL, D. B., T. D. KINNEY and W. WENDT. 1953. Pathologic lesions in captive wild animals. Lab. Invest. 2: 154-163.
5. LEWIS, W. P. and J. F. KESSEL. 1961. Hemagglutination in the diagnosis of toxoplasmosis and amebiasis. Archs. Ophthal. Chicago, 66: 471-476.
6. MANDELLI, G., A. CERIOLI, E. E. A. HAHN and F. STROZZI. 1966. Osservazioni anatomo-istologiche e parassitologiche su di un episodio di Toxoplasmosi nel canguro di Bennett (*Macropus bennetti* Gould). Bull. Ist. Sieroter. Milan 45: 177-192.
7. PARK, H. Y. 1961. Toxoplasma hemagglutination test using alcohol-formalin fixed sensitized lyophilized erythrocytes. Archs. Ophthal., Chicago, 65: 184-191.
8. RATCLIFFE, H. L. 1953. Toxoplasmosis. Rep. Penrose Res. Lab. 7.

9. RIEMANN, H. P., D. E. BEHYMER, M. E. FOWLER, T. SCHULZ, A. LOCK, J. G. ORTHOEFER, S. SILVERMAN and C. E. FRANTI. 1974. Prevalence of antibodies to *Toxoplasma gondii* in captive exotic mammals. J. Am. vet. med. Ass. 165: 798-800.
10. ———, M. E. FOWLER, T. SCHULZ, A. LOCK, J. THILSTED, L. T. PULLEY, R. V. HENRICKSON, A. M. HENNESS, C. E. FRANTI and D. E. BEHYMER. 1974. Toxoplasmosis in Pallas cats. J. Wildl. Dis. 10: 471-477.
11. THOMPSON, S. W. and T. H. REED. 1957. Toxoplasmosis in a swamp wallaby. J. Am. vet. med. Ass. 131: 545-549.

Received for publication 16 August 1976
