

SPONTANEOUS RENAL DISEASE IN LOUISIANA ARMADILLOS (*Dasypus novemcinctus*) 1

Authors: STUART, B. P., CROWELL, W. A., ADAMS, W. V., and
CARLISLE, J. C.

Source: Journal of Wildlife Diseases, 13(3) : 240-244

Published By: Wildlife Disease Association

URL: <https://doi.org/10.7589/0090-3558-13.3.240>

The BioOne Digital Library (<https://bioone.org/>) provides worldwide distribution for more than 580 journals and eBooks from BioOne's community of over 150 nonprofit societies, research institutions, and university presses in the biological, ecological, and environmental sciences. The BioOne Digital Library encompasses the flagship aggregation BioOne Complete (<https://bioone.org/subscribe>), the BioOne Complete Archive (<https://bioone.org/archive>), and the BioOne eBooks program offerings ESA eBook Collection (<https://bioone.org/esa-ebooks>) and CSIRO Publishing BioSelect Collection (<https://bioone.org/csiro-ebooks>).

Your use of this PDF, the BioOne Digital Library, and all posted and associated content indicates your acceptance of BioOne's Terms of Use, available at www.bioone.org/terms-of-use.

Usage of BioOne Digital Library content is strictly limited to personal, educational, and non-commercial use. Commercial inquiries or rights and permissions requests should be directed to the individual publisher as copyright holder.

BioOne is an innovative nonprofit that sees sustainable scholarly publishing as an inherently collaborative enterprise connecting authors, nonprofit publishers, academic institutions, research libraries, and research funders in the common goal of maximizing access to critical research.

SPONTANEOUS RENAL DISEASE IN LOUISIANA ARMADILLOS (*Dasypus novemcinctus*)¹

B. P. STUART,² W. A. CROWELL,³ W. V. ADAMS and J. C. CARLISLE

Abstract: Renal lesions were present in 34 (68%) of 50 armadillos (*Dasypus novemcinctus*) collected for a survey of the prevalence of leptospires in Louisiana wildlife. The renal lesions were not associated with elevations in the renal function tests of blood urea nitrogen or serum creatinine or with consistent serologic or cultural evidence of leptospires.

INTRODUCTION

The armadillo (*Dasypus novemcinctus*) is becoming an important model for biomedical research in organ culture systems (Amborski, R. L., pers. comm.), genetic studies² and as a model for leprosy.^{6,9} This interest, and the paucity of literature on morphologic studies on this species, prompted the present retrospective investigation of renal disease in the armadillo. The animals were collected in a prior survey for leptospires in Louisiana wildlife.⁷

MATERIALS AND METHODS

The method of capturing armadillos in Louisiana has been described.¹ Sera were collected for serologic evaluation and stored at -10 C for 10-16 years. Kidneys and urine were cultured for leptospires⁸ and samples of each kidney were placed in bottles containing 10% formalin. These bottles were labeled, sealed in paraffin and stored at ambient temperature (for 10-16 years). Kidneys from 50 of 226 animals of all ages originally captured were randomly selected for morphologic evaluation. Multiple

slices of each kidney were sectioned to insure evaluation of cortex, medulla, and pelvis and were processed by standard histological techniques. Tissue sections of 5 μ m thickness were stained with hematoxylin and eosin and examined by light microscopy. Selected sections were stained by the following techniques: Von Kossa for calcium salts; Periodic acid-Schiff for mucopolysaccharides, Warthin-Starry for spirochetes; Ziehl-Neelsen and Fite-Faraco for acid fast organisms.

Morphologic alterations in the renal interstitium, renal corpuscles, renal tubules, pelvis and vasculature were subjectively graded as follows: Zero, no lesion; 1+, mild focal lesion; 2+, multifocal or moderate lesion; 3+, focal disseminated or extensive lesion.

Stored sera were thawed and blood urea nitrogen (BUN) and serum creatinine (SC) determinations made utilizing either single⁴ or automated chemistry⁵ technique. These tests and results of serum agglutination reactions and culture attempts for leptospires were compared with the histologic renal changes.

¹ A joint contribution from the Department of Veterinary Pathology (Stuart, Carlisle and Crowell) and the Department of Veterinary Science (Adams), Louisiana State University, School of Veterinary Medicine, Baton Rouge, Louisiana 70803, USA.

² Present address: Veterinary Diagnostic and Investigational Laboratory, College of Veterinary Medicine, University of Georgia, Tifton, Georgia 31794, USA.

³ Present address: Department of Pathology, College of Veterinary Medicine, University of Georgia, Athens, Georgia 30602, USA.

⁴ Urograph, Warner-Chilcott, Morris Plains, N.J.

⁵ Hycel, Hycel, Inc., Houston, Texas.

RESULTS AND DISCUSSION

Morphologic changes of varied severity and type were present in 34 (68%) of the kidneys examined (Table 1). The most prominent and consistent lesion was multifocal to focal disseminated nonsuppurative interstitial nephritis (Figs. 1 and 2). This lesion, present in 32 (64%) animals and largely limited to the renal cortices, was characterized by interstitial infiltration of mononuclear cells, principally lymphocytes and plasma cells. Connective tissue proliferation or scarring was often moderate to extensive. Periglomerular sclerosis or connective tissue thickening of Bowman's capsule paralleled the interstitial fibrosis. Fourteen (28%) animals had mild to moderate periglomerular sclerosis. Von Kossa-positive mineral debris occasionally was seen within the thickened Bowman's capsule. Renal tubular degeneration, present in 14 (28%) animals, accompanied areas of moderate to extensive interstitial cellular infiltrate and scarring. This degeneration was characterized by tubular dilation with flattened epithelium, occasional cellular cast formation and compensatory hyperplasia and hypertrophy. Mild lymphocytic infiltration within the submucosa of the renal pelvis was present in 5 (10%) animals. Multifocal mineral deposits were present within the medullary interstitium in 7 (14%) animals. Chronic perirenal fibrosis and proliferative endarteritis were observed in 2 (4%) animals. Microorganisms were not demonstrated within the renal lesions by specialized histologic stains.

BUN and SC values were not significantly different ($p < .05$, F and T tests) for animals with or without renal lesions (Table 2). The BUN determinations with the urograph procedure gave notably higher values than those determined by automated methods. Variables such as air conditions in the room, including tobacco smoke, affect the urograph strip more than the automated methods, and probably account for the differences. The values for BUN and SC are comparable to or lower than published data

from captured¹⁰ or colony reared⁴ armadillos. The normal BUN and SC values emphasize the subclinical nature of the renal lesions. Renal disease may not be clinically apparent until approximately 66% to 75% of the nephrons are destroyed, resulting in azotemia.⁵

The etiology of this naturally occurring interstitial nephritis in the armadillo is unknown. *Leptospires* (*L. pomona*, *L. sentot*) were isolated from 2 animals, one with no renal lesions, the other with mild focal lymphocytic interstitial infiltrates. Positive titers to a variety of serotypes shown in Table 3 were present in 19 (38%) armadillos in this survey. Only 2 (6%) animals with interstitial nephritis had agglutination titres of 100 or greater. Positive titers at these levels indicate previous exposure to the organism with immunoconversion. Active infection with associated morphologic renal lesions is not implied. In a study of 497 armadillos in Argentina, *bataviae* serogroup was isolated from 5.4%, with a 23% serologic reactor rate to several other serotypes.³

The renal lesions in armadillos in this survey are primarily of cortical distribution, suggesting hematogenous rather than ascending route of entry for an etiologic agent. This nongranulomatous inflammatory response in these kidneys was not accompanied by an eosinophilic infiltrate, nor was there evidence of parasitic debris. A mild lymphocytic infiltrate in the renal pelvis in 5 (10%) animals was not associated with disruption of the pelvic epithelium.

Armadillos have received attention in the field of leprosy research.^{9,11} The animal is reported to have an intact immune system capable of mobilizing a cellular response to injury.⁹ Macrophages containing acid-fast organisms have been described in the leprosy-like disease occurring naturally in armadillos, but there was no mention of renal involvement.¹¹ A lymphocytic response was prominent within the kidneys in the present study. However, there was minimal histiocytic response. Acid-fast organisms were not observed.

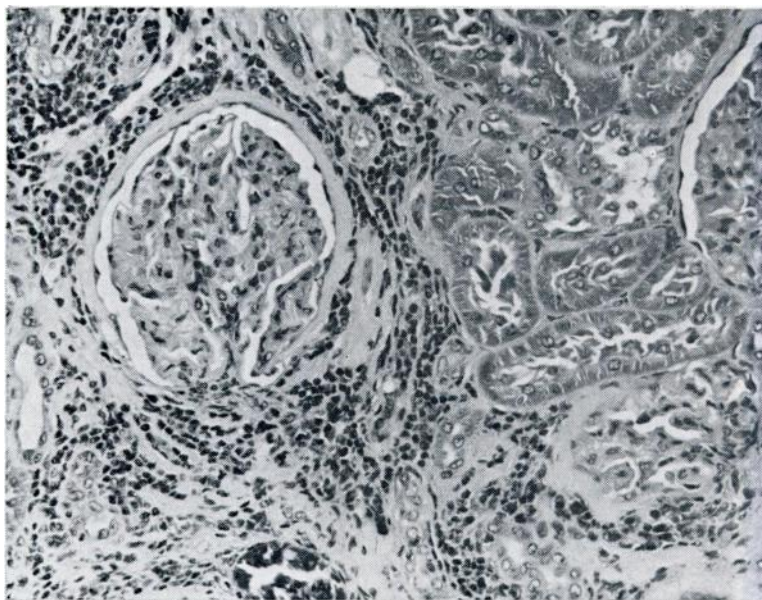


FIGURE 1. Moderate interstitial fibrosis and lymphocytic inflammatory cell infiltration. Note thickening of Bowman's capsule of the renal corpuscle. H & E x 160.

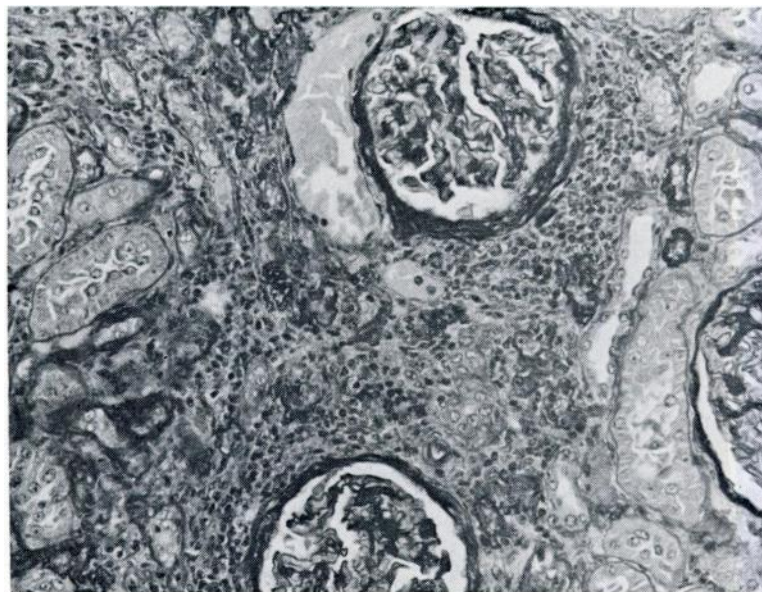


FIGURE 2. Focus of moderate to marked nonsuppurative interstitial nephritis. Note cellular infiltrate, destruction of renal tubules and thickened Bowman's capsule. PAS x 160.

TABLE 1. Distribution of renal lesions in 50 Armadillos (*Dasypus novemcinctus*).

Lesions	Interstitial	Renal Tubules	Renal Pelvis	Renal Corpuscles	Focal Mineralization	Other
None	12 ^a (6) ^b	20(16)	23(22)	20(16)	22(21)	23(25)
Mild 1+	9(11)	5 (7)	2 (3)	5 (7)	2 (4)	1 (0)
Moderate 2+	4 (4)	0 (2)	0 (0)	0 (2)	1 (0)	1 (0)
Marked 3+	0 (4)	0 (0)	0 (0)	0 (0)	0 (0)	0 (0)
Percentage Lesions M (F)	52 (76)	20(36)	8(12)	20(36)	12(16)	8 (0)
Total Percentages (M and F)	64	28	10	28	14	4

^a Male^b () FemaleTABLE 2. Blood Urea Nitrogen (BUN) and Serum Creatinine (SC) determinations in Armadillos (*Dasypus novemcinctus*).

Sex	BUN	SC	Nephritis
M	13	1.0	0
F	35*	qns	0
M	6	0.7	0
F	13	0.9	0
M	25*	0.4	0
F	6	0.7	0
F	11	0.2	3+
F	25*	qns	2+
M	14	0.7	2+
F	24	0.5	2+
F	17	0.7	2+
F	15	0.5	3+

* Urograph, Warner Chilcott

TABLE 3. *Leptospira* Serotypes in 50 Armadillos (*Dasypus novemcinctus*).

Interstitial Nephritis	Total Lesions	Sero Negative	Sero Positive	<i>L. ballum</i>	<i>L. ictero</i>	<i>L. grippo</i>	<i>L. mini georgia</i>	<i>L. paidjan</i>	<i>L. 1945</i>	<i>L. myocastorius</i>	<i>L. autumnalis</i>	<i>L. pomona</i>
None	18	12	6		1	1	1		3	1	1	1
Mild	19	11	8	1	1	2	2		1	1	2	1
Moderate	9	5	4		1	2		1				1
Marked	4	3	1								1	1

The renal tubular basement membrane's interstitium, Bowman's capsule and glomerular mesangium appear more prominent in the unaffected armadillo kidneys than in the common livestock and pet species. This, and the high pre-

valence 34 (68%) of mild to marked nonsuppurative interstitial nephritis in the armadillo, should be considered when utilizing this animal for biomedical research.

LITERATURE CITED

1. ADAMS, W. V., G. E. SANFORD, E. E. ROTH and L. L. GLASGOW. 1964. Nighttime capture of striped skunks in Louisiana. *J. Wildl. Manage.* 28: 368-373.
2. ANDERSON, J. M. and K. BENIRSCHKE. 1966. The armadillo, *Dasypus novemcinctus*, in experimental biology. *Lab. An. Care* 16: 202-216.
3. CARILLO, C. G., D. M. MEYERS and B. SZYFRES. 1972. Bataviae group leptospirae isolated from armadillos in Argentina. *Trop. Geogr. Med.* 24: 377-381.
4. GIACOMETTI, L., A. K. BERNTZEN and M. L. BLISS. 1972. Hematologic parameters of the nine-banded armadillo, *Dasypus novemcinctus*. *Comp. Biochem. Physiol.* 43: 213-217.
5. OSBORNE, C. A., D. G. LOW and D. R. FINCO. 1972. *Canine and feline urology*. W. B. Sanders Co., Philadelphia, PA.
6. PURTILO, D. T., G. P. WALSH, E. E. STORRS and C. GANNON. 1975. The immune system of the nine-banded armadillo (*Dasypus novemcinctus*, Linn). *Anat. Rec.* 181: 725-734.
7. ROTH, E. E., W. V. ADAMS, K. NEWMAN, G. E. SANFORD, B. GREER and K. LOWE. 1965. The epidemiology of leptospirosis in Louisiana. *J. La. State Med. Soc.* 117: 110-115.
8. LINDER, D. and W. V. ADAMS. 1961. The use of agar plates as an aid for the isolation of leptospirae. *Am. J. vet. Res.* 22: 308-312.
9. STORRS, E. E. 1971. The nine-banded armadillo: A model for leprosy and other biomedical research. *Int. J. Lepr.* 39: 703-714.
10. STROZIER, L. M., C. B. BLAIR, JR. and B. H. EVANS. 1971. Armadillos: Basic profiles I. serum chemistry values. *Lab. An. Sci.* 21: 399-400.
11. WALSH, G. P., E. E. STORRS, H. P. BURCHFIELD, E. H. COTTRELL, M. F. VIDRINE and C. H. BINFORD. 1975. Leprosy-like disease occurring naturally in armadillos. *J. Retic. End. Soc.* 18: 347-351.
12. WAMPLER, S. N. 1969. Husbandry and health problems of armadillos, *Dasypus novemcinctus*. *Lab. An. Care* 19: 391-393.

Received for publication 27 January 1977