



## POXVIRUS FIBROMAS ON AFRICAN HARES 1

Authors: KARSTAD, L., THORSEN, J., DAVIES, G., and KAMINJOLO, J. S.

Source: Journal of Wildlife Diseases, 13(3) : 245-247

Published By: Wildlife Disease Association

URL: <https://doi.org/10.7589/0090-3558-13.3.245>

---

BioOne Complete ([complete.BioOne.org](https://complete.BioOne.org)) is a full-text database of 200 subscribed and open-access titles in the biological, ecological, and environmental sciences published by nonprofit societies, associations, museums, institutions, and presses.

Your use of this PDF, the BioOne Complete website, and all posted and associated content indicates your acceptance of BioOne's Terms of Use, available at [www.bioone.org/terms-of-use](https://www.bioone.org/terms-of-use).

Usage of BioOne Complete content is strictly limited to personal, educational, and non - commercial use. Commercial inquiries or rights and permissions requests should be directed to the individual publisher as copyright holder.

---

BioOne sees sustainable scholarly publishing as an inherently collaborative enterprise connecting authors, nonprofit publishers, academic institutions, research libraries, and research funders in the common goal of maximizing access to critical research.

## POXVIRUS FIBROMAS ON AFRICAN HARES<sup>1</sup>

L. KARSTAD,<sup>2</sup> J. THORSEN,<sup>3</sup> G. DAVIES<sup>2</sup> and J. S. KAMINJOLO<sup>4</sup>

**Abstract:** Small dermal tumors were found on three African hares (*Lepus capensis*) in the Laikipia District, Kenya. Gross and histopathologic studies revealed similarities to the Shope's fibroma of wild rabbits in North America and fibromas of European hares. Histological examination of the African hare fibromas revealed intracytoplasmic inclusion bodies characteristic of poxviruses and poxvirus virions were demonstrated by electron microscopy of ultrathin sections. Attempts to propagate the virus in rabbit skin, embryonated chicken eggs and cell cultures were unsuccessful.

### INTRODUCTION

Poxviruses of the myxoma-fibroma group, Genus *Leporipoxvirus*, cause naturally-occurring fibromas in the European rabbit (*Oryctolagus cuniculus*), cottontail rabbit (*Sylvilagus floridanus*), European hare (*Lepus europaeus*) and gray squirrel (*Sciurus carolinensis*).<sup>2,3,4</sup> This paper concerns the occurrence of a poxvirus-induced fibroma in African hares.

### CASE HISTORY

Small sessile tumors 0.5 to 1.5 cm in diameter were present on the feet of 3 of 12 hares (*Lepus capensis*) shot in January, 1976 near the Suguroi River, altitude 2200 m, Laikipia District, Kenya. The group comprised two mature males, four mature females, and six immature but almost fully-grown hares, three of each sex. Skin lesions were present on one mature male, one mature female and one immature female. The immature female had the largest (1.5 cm) lesion, located on the dorsolateral aspect of a front foot. She also had

three lesions on the face, each about 5 mm in diameter, located above and on each side of the nose. The skin over the tumors on this hare was hairless and smooth, while those on the toes of the hind feet of the other two animals were fissured and crusted, possibly the result of trauma of regression.

### LABORATORY STUDIES

The foot lesions were fixed in formalin, embedded in paraffin, sectioned at about 6  $\mu$ m and stained with haematoxylin and eosin (H & E). Histopathology revealed that the tumor was primarily of dermal origin, consisting of proliferating oval or round cells resembling fibroblasts. Many of the largest of these cells had rarified or vacuolated "ballooned" cytoplasm containing large, granular eosinophilic inclusions. Overlying the dermal component of the tumor, the stratified squamous epithelium was hyperplastic and a few of the cells in the stratum spinosum were hypertrophied and contained cytoplasmic inclusions. Prominent interpapillary columns of epidermis extended deep

<sup>1</sup> Studies undertaken within a cooperative programme in research on wildlife diseases supported by the Government of Kenya, the Canadian International Development Agency and the International Development Research Centre. Published with the permission of the Director of Veterinary Services, Kenya.

<sup>2</sup> Veterinary Research Laboratories, Kabete, Kenya.

<sup>3</sup> Department of Veterinary Microbiology and Immunology, University of Guelph, Guelph, Ontario, Canada.

<sup>4</sup> Department of Veterinary Pathology and Microbiology, Faculty of Veterinary Medicine, University of Nairobi, Kenya.

into the tumor where they terminated in irregular masses of hypertrophied epithelial cells. These cells were difficult to differentiate from the hypertrophied fibroblast-like cells in the central part of the tumor (Figure 1).

The formalin-fixed fibroma tissues were finely divided and suspended in 2.5% glutaraldehyde in phosphate buffer for electron microscopy. This was followed by post-fixation in osmium tetroxide in phosphate buffer and dehydration in acetone. Tissues were embedded in Epon 812 and stained with uranyl acetate and lead citrate. Sections were examined in a Philips 200 electron microscope at 60 Kv. Some fresh frozen material was prepared and processed for electron microscopy without fixation in formalin. These sections were examined in a Zeiss EM 9A electron microscope.

Electron microscopic examination revealed viral particles with typical poxvirus morphology located in the cytoplasm (Figure 2). Particles cut in cross section consisted of regularly arranged outer layers, surrounding a biconcave central nucleoid. The concavities were due to lateral bodies on either side of the nucleoid. The width of the poxvirions in cross section averaged 250 nm and the thickness, 145 nm. This compares with measurements for myxoma width of  $230 \text{ nm} \pm 20$  and for rabbit fibroma, 244 nm.<sup>1</sup>

A single lesion of 5 mm diameter adjacent to the nares was dissected from a specimen which had been kept at -20 C. This was minced with sterile sand and phosphate buffered saline containing 200 iu penicillin and 200  $\mu\text{g}$  streptomycin sulphate per ml and ground in a pestle. The resulting suspension was frozen and thawed with dry ice and alcohol and the buffer added to make a 10% suspension of the original tissue. This was clarified by centrifugation at 300 X G for 10 min.

This suspension was used to inoculate the chorioallantoic membrane of 6-day embryonated eggs and a cell culture prepared from bovine foetal muscle, which has been found to be susceptible to most Orthopox and Ungulopox viruses. The

eggs were inoculated with 0.1 ml aliquots onto the dropped membranes, incubated at 35 C for 6 days; the membranes harvested and passaged. Although

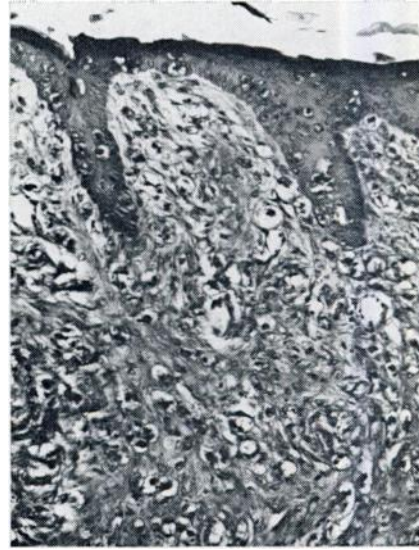


FIGURE 1. Histologic section of a hare fibroma. Note thickened epidermis and greatly proliferated dermis, both containing hypertrophied cells with vacuolated cytoplasm, and cells in both areas containing eosinophilic granular cytoplasmic inclusions. Hematoxylin-eosin X300.

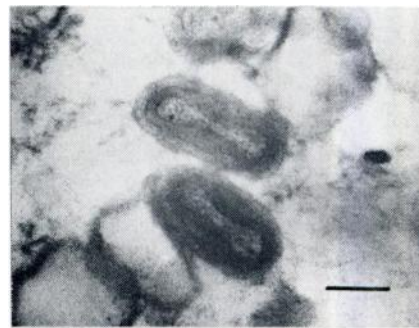

FIGURE 2. Electron micrograph of ultrathin section of hare fibroma. Two poxvirus particles have been cut in cross section, showing outer layers and biconcave nucleoid. Bar = 100 nm.

a slight oedema was seen in some membranes after the first passage, two further passages did not show this oedema nor any discrete pock-like lesions. Tube cultures of the foetal muscle cells were inoculated with 0.1 ml of the 10% suspension. Cytopathic effects were not seen after 14 days incubation at 37 C, nor did they occur after two passages of the frozen and thawed monolayers and cell culture fluid. Flying coverslips of the three passages were stained with H and E. No intracytoplasmic inclusions were seen suggestive of poxvirus.

A similar suspension of lesion material was used to inoculate a rabbit, and cell cultures of foetal sheep skin, bovine foetal lung and bovine foetal kidney. No evidence of cytopathic effect was observed in the cell cultures.

Lesions in the rabbit skin were limited to a transient inflammatory response to the inoculum. Skin biopsies taken 10 days postinoculation from the inoculated rabbit were examined by electron microscopy, but no virus particles were detected.

#### DISCUSSION

These hare fibromas are grossly and histologically very similar to Shope's fibroma of cottontail rabbits.<sup>3,4</sup> The similarities extend also to the morphology of the poxvirus involved.<sup>4</sup> Shope's fibroma, however, has not been reported on the African continent. The failure to propagate the virus in rabbit skin, chicken embryos and cell cultures suggests a relatively high degree of host specificity.

#### Acknowledgements

The authors are grateful to H. M. Karstad who collected the hares and reported the lesions.

#### LITERATURE CITED

1. FENNER, F. 1968. Poxviruses. In: *"Viral and Rickettsial Infections of Animals"* (A. O. Betts and C. J. York, eds.) Academic Press, New York.
2. KILHAM, L., C. M. HERMAN and E. R. FISHER. 1953. Naturally occurring fibromas of gray squirrels related to Shope's rabbit fibroma. *Proc. Soc. Exper. Biol. Med.* 82: 298-301.
3. SHOPE, R. E. 1932. A transmissible tumor-like condition in rabbits. *J. Exp. Med.* 56: 793-802.
4. YUILL, T. M. 1970. Myxomatosis and fibromatosis. In: *Infectious Diseases of Wild Mammals* (Davis, J. W. et al. Eds.) Iowa State University Press, Ames, pp. 104-130.

*Received for publication 13 January 1977*