



## **HISTOPATHOLOGIC ALTERATIONS ASSOCIATED WITH Anisakis LARVAE IN PACIFIC HERRING FROM OREGON 1**

Author: HAUCK, A. K.

Source: Journal of Wildlife Diseases, 13(3) : 290-293

Published By: Wildlife Disease Association

URL: <https://doi.org/10.7589/0090-3558-13.3.290>

---

BioOne Complete ([complete.BioOne.org](https://complete.BioOne.org)) is a full-text database of 200 subscribed and open-access titles in the biological, ecological, and environmental sciences published by nonprofit societies, associations, museums, institutions, and presses.

Your use of this PDF, the BioOne Complete website, and all posted and associated content indicates your acceptance of BioOne's Terms of Use, available at [www.bioone.org/terms-of-use](https://www.bioone.org/terms-of-use).

Usage of BioOne Complete content is strictly limited to personal, educational, and non - commercial use. Commercial inquiries or rights and permissions requests should be directed to the individual publisher as copyright holder.

---

BioOne sees sustainable scholarly publishing as an inherently collaborative enterprise connecting authors, nonprofit publishers, academic institutions, research libraries, and research funders in the common goal of maximizing access to critical research.

## HISTOPATHOLOGIC ALTERATIONS ASSOCIATED WITH *Anisakis* LARVAE IN PACIFIC HERRING FROM OREGON<sup>1</sup>

A. K. HAUCK,<sup>2</sup> Department of Fisheries and Wildlife, Oregon State University,  
Corvallis, Oregon 97331, USA

E. B. MAY, Department of Veterinary Medicine, Oregon State University,  
Corvallis, Oregon 97331, USA

**Abstract:** A histopathologic study of *Anisakis* sp. larvae in Pacific herring (*Clupea harengus pallasii*) is presented. Tissue alterations included mechanical compression of the pancreas and liver, granulomatous inflammation and necrosis of the liver, and trauma to the muscularis externa of the pyloric caeca. Host exudate in most lesions contained macrophages (histiocytes) and lymphocytes.

### INTRODUCTION

*Anisakis* sp. larvae have a wide distribution in many species of marine fishes, which serve as transfer hosts. *Anisakis* larvae are a stable part of the parasitic fauna of herring (*Clupea* sp.)

The importance of *Anisakis* larvae as a public health problem became known when they were found to cause gastric granulomata in man. This condition, presently known as human anisakiasis, was initially reported from Holland,<sup>13</sup> then later from Japan,<sup>1</sup> and more recently from the U.S.<sup>11</sup> Subsequently, the histopathologic changes and the visceral *larva migrans* accompanying anisakiasis have been thoroughly investigated in man and in experimental wild animals.<sup>8,9,10,12,15</sup> Relatively little is known of the pathologic effect of *Anisakis* larvae upon fish hosts,<sup>2</sup> and although various investigators have described lesions in some fish species infected with *Anisakis* larvae,<sup>4,6</sup> its histopathology in Pacific herring (*Clupea harengus pallasii*) from Oregon waters has not been documented.

### MATERIALS AND METHODS

Between April and July, 1975, 116 herring were purchased at Newport, Oregon. All specimens were examined for *Anisakis* larvae. A total of 15 fish, with varying levels of infection, were selected for the study. These were killed and fixed immediately after purchase. Since the larvae excysted and continued to migrate from fish being fixed in 10% formalin, Dietrich's fixative was selected to fix the larvae *in situ*. To facilitate fixation of the gastrointestinal tract, Dietrich's fixative was injected into the esophagus using a 50 cc syringe. Tissues were processed according to standard histological methods, and 6  $\mu$ m sections were stained with Harris' hematoxylin-eosin for conventional light microscopy. Tissue sections and blood smears were respectively stained with Giemsa and Wright-Leishman stains to identify blood cell types. Liver sections with granulomas were stained with Gram's and acid fast methods. Larvae were identified following the descriptions of various investigators.<sup>3,14</sup>

<sup>1</sup> Oregon Agricultural Experiment Station Technical Paper No. 4190.

<sup>2</sup> Present address: Fish Pathology Laboratory, State of Alaska, Department of Fish and Game, Anchorage, Alaska 99502, USA.

## RESULTS

*Anisakis* larvae were present in all fish examined. At gross inspection the larvae were coiled inside a connective tissue capsule at the surface of the pyloric caeca, pancreatic tissue, liver and large intestine. Gross lesions were not detectable.

Most larvae found in microscopic examination were encapsulated in a concentrically layered capsule (Fig. 1). In some cases the capsule adhered to the tissue serosa, but it was generally separated by a layer of host exudate containing free macrophages and lymphocytes. Macrophages also were aggregated together, forming the denser part of the capsule. Larger numbers of lymphocytes appeared to be associated with the capsule of lightly to moderately infected fish than of heavily infected fish.

All specimens examined demonstrated mechanical compression and displacement of the pancreas as well as host exudate at sites of close or direct larval contact. Numerous macrophages and lymphocytes had infiltrated the same region, but they were not found within the pancreatic tissue.

Four of the fish had high larval infections; these specimens had *Anisakis* involvement at or near the liver. In moderate to light infections, larval concentrations near the liver did not exist. All four fish had parenchymal granulomas of an undetermined nature. Acid fast and Gram stained sections did not give evidence that the granulomatous lesions were of bacterial etiology. Necrosis, often associated within granulomatous inflammation in mammals, was not observed. Mechanical compression of the liver by *Anisakis* larvae was found in all cases of liver involvement. Necrosis

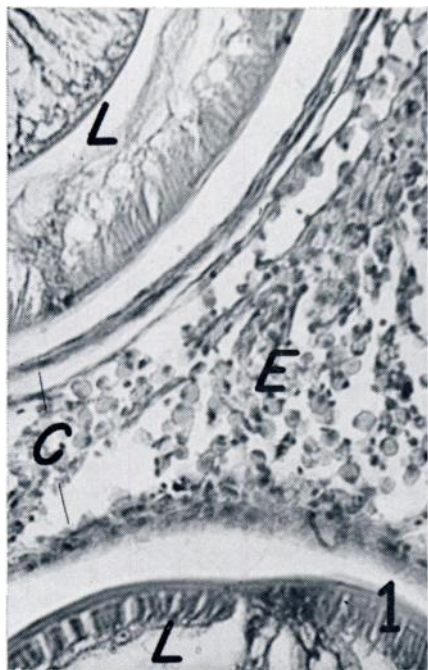


FIGURE 1. *Anisakis* larvae (L) within host capsules (C) and cellular exudate (E). H & E x240.

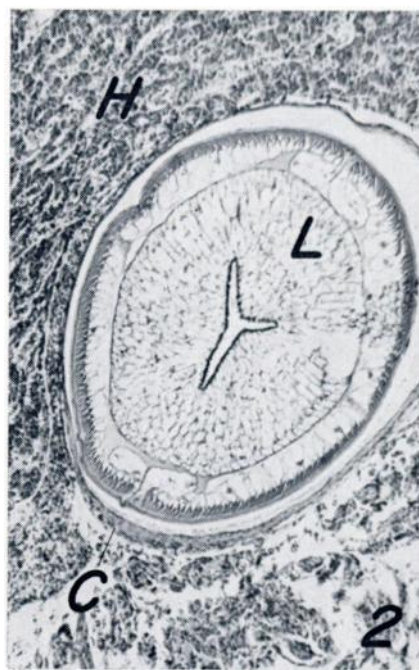

FIGURE 2. Compressed hepatic tissue (H) with associated *Anisakis* larva (L) and host capsule (C). H&E x74.

was not associated with this compression (Fig. 2). One heavily infected fish had severe, diffuse liver necrosis. Since compression of the parenchyma was not evident in this case, *Anisakis* larvae were not considered to be the cause. Larval penetration of the parenchyma was non-existent in all fishes examined; one specimen, however, showed larval penetration deep in the interlobular spaces.

Mechanical injury to the muscularis externa of a pyloric caecum was noted on one fish, and a single autolytic larva was found in the muscularis externa and lamina propria of a pyloric caecum in a second specimen (Fig. 3).

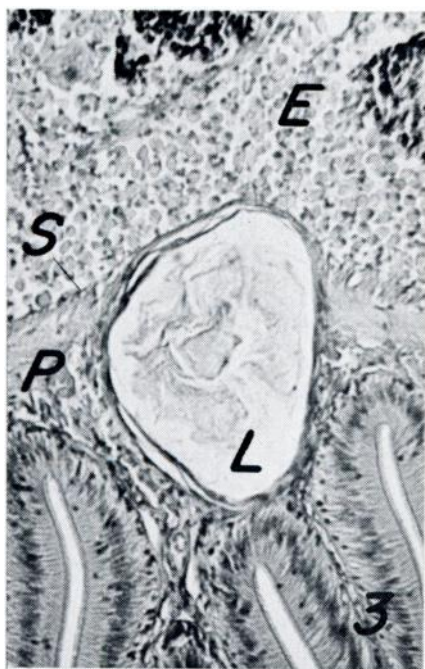

FIGURE 3. Autolytic larva (L) within pyloric caecum (P), serosa (S) and cellular exudate (E). H&E x180.

#### DISCUSSION

Capsule formation around *Anisakis* larvae in the Pacific herring appears similar to that described in other species

of fish.<sup>6</sup> A thin, hyalinized layer of degenerative tissue was located adjacent to the larva. The next layer contained loose connective tissue and aggregated macrophages; this was followed by free macrophages and lymphocytes. The macrophages appeared morphologically similar to the "finely reticular cells" described by various investigators.<sup>5</sup> However, macrophages of the present study were identified as such because they participated in capsule formation, contained a foamy cytoplasm, lacked granules, and were numerous. Although the macrophages lacked the characteristic "dirty" cytoplasm resulting from phagocytosed particulate matter, the cells may be actively imbibing the serous inflammatory exudate in the lesion.

The specific route of parasitic penetration from the gastrointestinal tract to the final position in the peritoneal cavity was undetermined. The reaction in two fish indicated that the pyloric caecum may be a route to the peritoneal cavity. More fish should be examined before the penetration route can be determined.

The origin of the liver granulomas and necrosis remains unclear. These conditions existed only in heavily infected fish, but the absence of repair tissue does not indicate direct mechanical injury.

Helminthic infections in higher vertebrates often elicit an eosinophilic inflammatory response in host tissues. Such response is common in human anisakiasis, but was not present in the fish examined in this study. This corroborates the findings of other investigators,<sup>7</sup> who asserted that extensive eosinophilia is not the usual inflammatory reaction of fish hosts against parasites.

It is unlikely that a critical organ dysfunction results from *Anisakis* infection in Pacific herring. But the presence of the exudate and inflammatory cells suggest an immunologic response of the host to the larvae. The cellular components of the lesion indicate a chronic pathology, which would be significantly serious only in older, more heavily infected fish.

**Acknowledgements**

Appreciation is expressed to Dr. R. A. Tubb, Department of Fisheries and Wildlife, Oregon State University; Dr. J. D. Hendricks and Professor J. H. Wales, Department of Food Science and Technology, Oregon State University; Dr. M. C. Mix and Mr. K. I. King, Department of General Science, Oregon State University; Dr. M. L. Landolt, College of Fisheries, University of Washington.

**LITERATURE CITED**

1. ASAMI, K., T. WATANUKI, H. SAKAI, H. IMANO and R. OKAMOTO. 1965. Two cases of stomach granuloma caused by *Anisakis*-like larval nematodes in Japan. *Am. J. Trop. Med. Hyg.* 14: 119-123.
2. BERLAND, B. 1961. Nematodes from some Norwegian marine fishes. *Sarsia* 2: 1-50.
3. CHITWOOD, M. and J. R. LICHTENFELS. 1972. Parasitological review. Identification of parasitic metazoa in tissue sections. *Exp. Parasit.* 32: 407-519.
4. KAHL, W. 1938. Nematoden in Seefischen. II. Erhebungen ueber den Befall von Seefischen mit Larven von *Anacanthocheilus rotundatus* (Rudolphi) und die durch diese Larven hervorgerufenen Reaktionen des Wirtesgewebes. *Z. Parasitenkd.* 10: 513-534.
5. LESTER, R. J. G. and B. A. DANIELS. 1976. The eosinophilic cell of the white sucker, *Catostomus commersoni*. *J. Fish. Res. Board Can.* 33: 139-144.
6. MARGOLIS, L. 1970. Nematode diseases of marine fishes, pp. 190-208. In: S. F. Snieszko, ed. *A Symposium on Diseases of Fishes and Shellfishes*. Am. Fish. Soc. Spec. Publ. No. 5, Washington, D.C.
7. MAWDESLEY-THOMAS, L. E. 1975. Some diseases of muscle, pp. 343-363. In: W. E. Ribelin and G. Migaki, eds. *The Pathology of Fishes*. University of Wisconsin Press, Madison, Wisconsin.
8. MIGAKI, G., D. VAN DYKE and R. C. HUBBARD. 1971. Some histopathological lesions caused by helminths in marine mammals. *J. Wildl. Dis.* 7: 281-289.
9. MYERS, B. J. 1963. The migration of *Anisakis*-type larvae in experimental animals. *Can. J. Zool.* 41: 147-151.
10. OISHI, K., S. OKA and S. JOSHO. 1969. An introduction to food hygiene of the *Anisakis* larva. (Transl. from Japanese). *Fish. Res. Board Transl. Ser. No. 1414*, 270 pp.
11. PINKUS, G. S., C. COOLIDGE and M. D. LITTLE. 1975. Intestinal anisakiasis. First case report from North America. *Am. J. Med.* 59: 114-120.
12. RILEY, J. 1972. The pathology of *Anisakis* nematode infections of the fulmar *Fulmaris glacialis*. *Ibis* 114: 102-104.
13. VAN THIEL, P. H., F. C. KUIPERS and R. T. RISKAM. 1960. A nematode parasitic to herring, causing acute abdominal syndromes in man. *Trop. Geogr. Med.* 2: 97-113.
14. YORKE, W. and P. A. MAPLESTONE. 1926. *The Nematode Parasites of Vertebrates*. J. & A. Churchill, London, 536 pp.
15. YOUNG, P. C. and D. LOWE. 1969. Larval nematodes from fish of the subfamily Anisakinae and gastro-intestinal lesions in mammals. *J. Comp. Path.* 79: 301-313.

Received for publication 7 February 1976