



## FIBROSARCOMA IN A WHITE-TAILED DEER

Authors: ELWELL, M. R., BURGER, G. T., MOE, J. B., WHITE, J. D.,  
and STOOKEY, J. L.

Source: Journal of Wildlife Diseases, 13(3) : 297-299

Published By: Wildlife Disease Association

URL: <https://doi.org/10.7589/0090-3558-13.3.297>

---

BioOne Complete ([complete.BioOne.org](https://complete.BioOne.org)) is a full-text database of 200 subscribed and open-access titles in the biological, ecological, and environmental sciences published by nonprofit societies, associations, museums, institutions, and presses.

Your use of this PDF, the BioOne Complete website, and all posted and associated content indicates your acceptance of BioOne's Terms of Use, available at [www.bioone.org/terms-of-use](https://www.bioone.org/terms-of-use).

Usage of BioOne Complete content is strictly limited to personal, educational, and non - commercial use. Commercial inquiries or rights and permissions requests should be directed to the individual publisher as copyright holder.

---

BioOne sees sustainable scholarly publishing as an inherently collaborative enterprise connecting authors, nonprofit publishers, academic institutions, research libraries, and research funders in the common goal of maximizing access to critical research.

## FIBROSARCOMA IN A WHITE-TAILED DEER

M. R. ELWELL, G. T. BURGER,<sup>1</sup> J. B. MOE,<sup>1</sup> J. D. WHITE and J. L. STOOKEY

United States Army Medical Research Institute of Infectious Diseases,  
Fort Detrick, Frederick, Maryland 21701, USA

**Abstract:** A large, rapidly growing subcutaneous fibrosarcoma was observed on the head of an aged male white-tailed deer (*Odocoileus virginianus*) from Frederick County, Maryland. Although there was no evidence of distant metastasis, the large neoplastic mass had extensively invaded the osseous supraorbital process, and had several small satellite nodules nearby.

### INTRODUCTION

Numerous case reports and studies concerning cutaneous tumors in the white-tailed deer (*Odocoileus virginianus*) have been summarized by Fay.<sup>1</sup> These tumors, which have been described as fibromas and fibrosarcomas, have been shown to be transmittable and of viral origin.<sup>4</sup> Although the viral-induced lesions have been described by Shope *et al.*<sup>3</sup> as slow-growing benign tumors, a more recent case reported multiple fibroblastomas in the lung of a deer with cutaneous fibromatosis.<sup>2</sup> The purpose of this report is to describe a neoplasm similar to those reported previously, but differing in that it was a rapidly growing, locally invasive mass in which viral etiology was not demonstrated. This condition has not been reported previously in deer in Maryland.

### CASE HISTORY

In March, 1975, a 2.5-cm diameter, smooth nodular mass was noted over the left eye of an aged male white-tailed deer from a herd of deer in Central Maryland. In April, the mass had increased to a diameter of 8 cm, and enlarged the following month so as to completely block vision from the left eye. The deer was killed, a thorough necropsy was performed, and tissues

were taken for light and electron microscopic examination. Tumors were not observed in other deer in the herd.

The tumor (Fig. 1) consisted of a solid mass of tissue, 12.5 x 7.5 x 10.5 cm, firmly attached to the supraorbital process of the left frontal bone. The overlying epithelium was slightly pigmented, partially alopecic, and loosely attached to the tumor. Several small 1 to 2 cm nodules were adjacent but separate from the larger mass. There was no gross evidence of distant metastasis and no other significant gross lesions in the otherwise healthy, well-nourished animal.

Light microscopy revealed the tumor and smaller nodules to consist of well vascularized, proliferating masses of fibrous connective tissue with cells growing in bundles and whorls (Fig. 2). Tumor cells were fusiform or stellate in shape. In addition, there were many larger plump cells with pale ovoid nuclei; occasional multinucleated cells also were present. Mitotic figures were rarely seen. Small lymphocytes and neutrophils were scattered occasionally throughout the tumor. The mass did not extend into the dermis of the overlying skin but extensively infiltrated the bone of the supraorbital process. Examination of all other organ systems revealed no metastasis or significant lesions.

<sup>1</sup> Present addresses: G. T. Burger, Pathology Services, National Center for Toxicological Research, Jefferson, Arkansas 72079, USA, and J. B. Moe, Department of Veterinary Pathology, College of Veterinary Medicine, University of California, Davis, California 95616, USA.



FIGURE 1. The head with the tumor extending over the left eye.

Electron microscopy confirmed that the mass was comprised of fibroblasts and collagen fibers. Viral particles were not seen within the tumor or overlying epithelium.

#### DISCUSSION

Although this neoplasm is similar to others described in the literature, there are features of this case which differ from the viral-induced fibromas/fibrosarcomas. The growth rate of tumors in experimentally infected deer is considerably slower; the size is of less magnitude than in this naturally occurring case.<sup>2</sup> The experimentally induced tumors reached a maximum size of 3 cm in one deer 8 months after the cutaneous nodules first appeared.<sup>2</sup> Although transmission of the tumor and virus isolation were not attempted in this case, viral

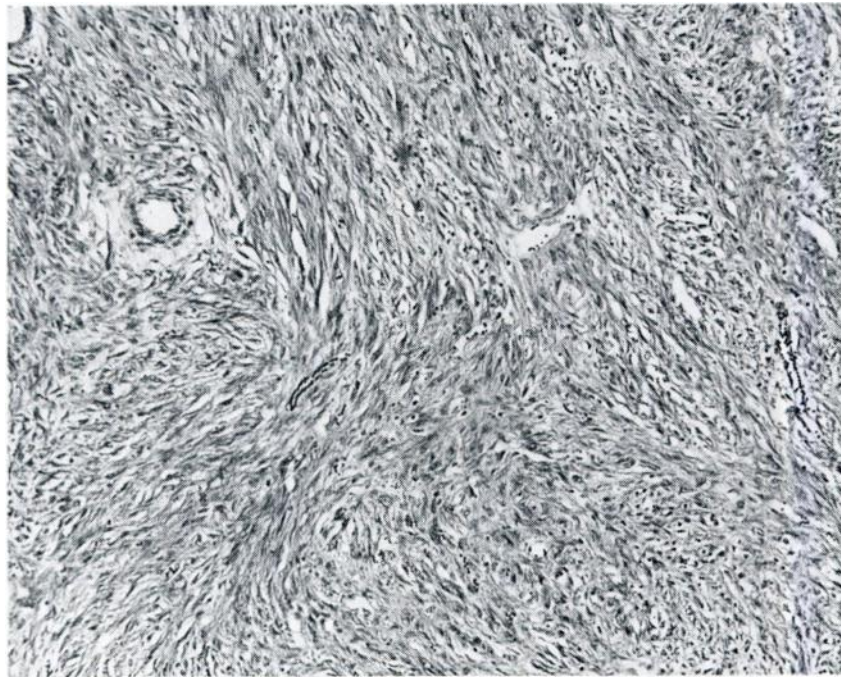


FIGURE 2. Typical pattern of connective tissue bundles formed by the neoplastic cells. H & E stain, 72X.

particles could not be demonstrated in the tumor or overlying epithelium. Such a finding does not negate the possibility of a viral role in this case but suggests that another form of this condition may exist.

Distant metastasis of the type de-

scribed by Koller and Olson<sup>2</sup> were not present but the invasion of the bone of the skull demonstrates a locally malignant characteristic of this neoplasm which has not been reported to occur in the tumors induced by the deer fibroma virus.

#### LITERATURE CITED

1. FAY, L. D. 1970. Skin tumors of the cervidae. In: *Infectious Diseases of Wild Mammals*, Davis, J. W., Karstad, L. H. and Trainer, D. O., Eds., Iowa University Press, Ames, pp. 385-392.
2. KOLLER, L. D. and C. OLSON. 1971. Pulmonary fibroblastomas in a deer with cutaneous fibromatosis. *Cancer Res.* 31: 1373-1375.
3. SHOPE, R. E., R. MANGOLD, L. G. MacNAMARA and K. R. DUMBELL. 1958. An infectious cutaneous fibroma of the Virginia white-tailed deer (*Odocoileus virginianus*). *J. exp. Med.* 108: 797-802.
4. TAJIMA, M., D. E. GORDON and C. OLSON. 1968. Electron microscopy of bovine papilloma and deer fibroma viruses. *Am. J. vet. Res.* 29: 1185-1194.

*Received for publication 16 August 1976*

---