



RENAL LESIONS IN STRIPED SKUNKS (*Mephitis mephitis*) FROM LOUISIANA

Authors: CROWELL, W. A., and STUART, B. P.

Source: Journal of Wildlife Diseases, 13(3) : 300-303

Published By: Wildlife Disease Association

URL: <https://doi.org/10.7589/0090-3558-13.3.300>

BioOne Complete (complete.BioOne.org) is a full-text database of 200 subscribed and open-access titles in the biological, ecological, and environmental sciences published by nonprofit societies, associations, museums, institutions, and presses.

Your use of this PDF, the BioOne Complete website, and all posted and associated content indicates your acceptance of BioOne's Terms of Use, available at www.bioone.org/terms-of-use.

Usage of BioOne Complete content is strictly limited to personal, educational, and non - commercial use. Commercial inquiries or rights and permissions requests should be directed to the individual publisher as copyright holder.

BioOne sees sustainable scholarly publishing as an inherently collaborative enterprise connecting authors, nonprofit publishers, academic institutions, research libraries, and research funders in the common goal of maximizing access to critical research.

RENAL LESIONS IN STRIPED SKUNKS (*Mephitis mephitis*) FROM LOUISIANA

W. A. CROWELL¹ and B. P. STUART,² Department of Veterinary Pathology

W. V. ADAMS, Department of Veterinary Science, School of Veterinary Medicine,
Louisiana State University, Baton Rouge, Louisiana 70803, USA

Abstract: Renal tissue from 100 striped skunks (*Mephitis mephitis*) examined microscopically showed evidence of inflammation in 74% of the kidneys. Azotemia was present in 20% of the skunks that had severe renal lesions. The cause of inflammation is unknown, but leptospire were cultured from kidneys or urine of 55% of these skunks.

INTRODUCTION

Renal lesions have not been reported as a major problem in striped skunks (*Mephitis mephitis*). Thus, when severe lesions were observed in the kidneys of pet and feral striped skunks presented for necropsy examination at the Department of Veterinary Pathology, Louisiana State University, a survey was conducted to determine the frequency of renal lesions. Fortuitously, renal tissue from striped skunks collected as a part of a previous survey for leptospire and cultured by Roth, *et al.*^{1,7,8,9} had been fixed and stored in formalin. This is a retrospective survey of renal lesions accomplished by utilizing tissues collected 10 to 16 years previously.

MATERIALS AND METHODS

The method of capturing skunks,¹ and the results of culturing the urinary system for leptospire were described previously.^{7,9} Portions of kidney from each skunk had been placed in individual bottles of formalin. The bottles were labeled, sealed by immersion in paraffin and stored at ambient temperature for 10 to 16 years. One hundred bottles of renal tissue were randomly chosen from

the approximately 900 in storage. Multiple sections of kidney from each animal were processed by standard histologic techniques, stained with hematoxylin and eosin, or Periodic acid-Schiff and examined microscopically.

Morphologic alterations in the glomeruli, tubules, interstitium, pelvis or vessels were subjectively graded as 0 (no lesion), + (mild lesion), ++ (moderate lesion) and +++ (severe lesion). The lesions were tabulated and correlations were made regarding lesion severity, sex, and *Leptospira* sp. isolated.

Serum was harvested from the blood of each skunk at the time of euthanasia and stored at -10 C for 10 to 16 years. Sera from 10 skunks with no renal lesions and 10 skunks with severe renal lesions were randomly selected for measuring serum creatinine (SC) and blood urea nitrogen (BUN) levels.

RESULTS AND DISCUSSION

Renal lesions characterized by infiltration of the interstitium with mononuclear cells, principally lymphocytes, were present in 74% of the skunks examined (Tables 1 and 2). This cellular infiltrate was found most consistently in

¹ Present address: Department of Veterinary Pathology, University of Georgia, Athens, Georgia 30602, USA.

² Present address: Tifton Diagnostic Laboratory, P.O. Box 1389, Tifton, Georgia 31794, USA.

TABLE 1. Distribution of renal lesions in male and female striped skunks.

Lesion	Glomeruli	Interstitium	Tubules	Renal Pelvis	Renal Vessels	Focal Mineralization
None	88 (90)*	26 (33)	83 (79)	86 (79)	95 (100)	69 (80)
Mild	12 (10)	33 (28)	17 (21)	9 (18)	5 (0)	0 (0)
Moderate	0 (0)	19 (28)	0 (0)	5 (3)	0 (0)	31 (20)
Marked	0 (0)	22 (11)	0 (0)	0 (0)	0 (0)	0 (0)

*Female results in parenthesis. M (F).

TABLE 2. Comparison of *Leptospira* cultural results and inflammatory reaction in the interstitium of striped skunk kidneys.

Culture	Number of Skunks	Number of inflammatory reactions and (%)			
		Absent	Mild	Moderate	Marked
Negative	45	24 (54)	13 (29)	6 (13)	2 (4)
<i>L. pomona</i>	18	2 (11)	3 (17)	6 (33)	7 (39)
<i>L. hyos</i>	16	1 (6)	10 (63)	5 (31)	0 (0)
<i>L. canicola</i>	12	1 (8)	0 (0)	5 (42)	6 (50)
<i>L. ballum</i>	8	2 (25)	4 (50)	1 (12.5)	1 (12.5)
<i>L. icterohem.</i>	1	0 (0)	1 (100)	0 (0)	0 (0)

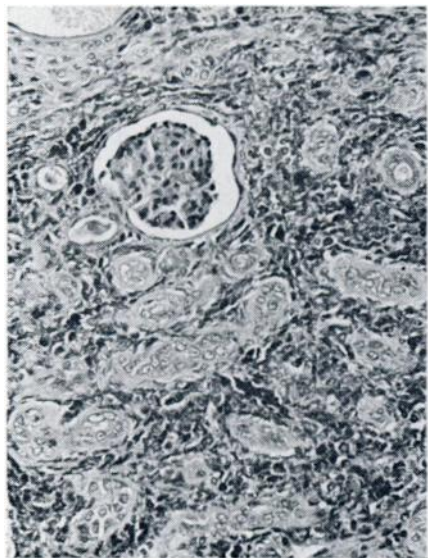


FIGURE 1

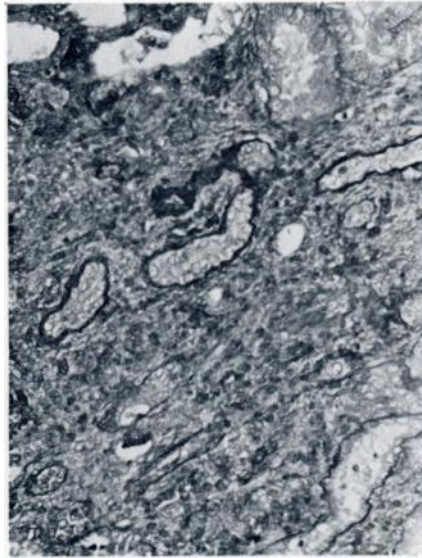


FIGURE 2

Photomicrographs of kidneys from skunk. There is marked infiltration of lymphocytes in the interstitium, increased fibrosis and destruction of nephrons.

the interstitium of the cortical areas, but also was seen in the pelvis, medulla and occasionally adjacent to blood vessels (Figures 1 and 2). Glomeruli usually were normal, but occasionally atrophy, periglomerular fibrosis or thickening of glomerular capillary walls was present. Glomerular changes usually were associated with interstitial fibrosis in the cortex. In addition to the interstitial infiltrate, renal tubular degeneration and dilation of tubules, some containing hyaline casts was present. Tubular epithelium varied from a flattened, squamous-type to areas of regeneration with hyperplasia and hypertrophy. Focal mineralization was present in the interstitium of the medulla. The morphologic diagnosis that best encompasses these lesions is chronic nephritis or chronic interstitial nephritis.

Undamaged nephrons compensate for nephrons that are damaged or destroyed by renal lesions. Thus, renal function may not be seriously compromised unless approximately 66% to 75% of the nephrons are destroyed.⁹ As renal disease progresses, more nephrons are destroyed and renal function declines until azotemia, uremia and death may result. The mean levels of SC and BUN in the 10 skunks showing severe renal lesions were higher than those of the 10 skunks without renal lesions (Table 3). Only 2 of the 10 skunks with severe renal lesions were considered azotemic. Those 2 skunks had BUN levels of 49 and 47 mg/dl. One had a SC level of 1.2 mg/dl. Serum from the other skunks tested had BUN levels less than 30 mg/dl, and SC levels less than 0.7 mg/dl.

The cause of these renal lesions is unknown. Use of the Chi-square test for unequal expectations revealed a positive correlation between the presence of renal lesions and the presence of leptospire (p < .005). However leptospire were not isolated from all skunks with renal lesions and, conversely, were isolated from some skunks without renal lesions. *Leptospira pomona* and *L. Canicola* were associated with the most severe renal changes. These serotypes also are two of the most significant isolates in the common domestic and pet species.³

If nephritis is due to an infectious agent, that agent may reach the kidney via the blood or from the lower urinary tract. Ascending infection from the lower urinary tract can occur in other species as a result of vesicoureteral reflex⁷ (backflushing of urine into the ureters during micturition) or other means.^{4,10} Pyelitis is usually present with ascending infection. Since pyelitis was not a major lesion in these skunks, the agent probably reached these kidneys via the blood.

There were no differences in prevalence of renal lesions between sexes. Thus the nephritis apparently is not more frequent in males, as reported in dogs.²

These data from a retrospective group suggest that renal lesions in striped skunks from Louisiana often were associated with exposure to leptospire. Although we examined only two skunks that were killed or died in 1976, both had moderate to severe renal lesions similar to those in our retrospective group. Further study is needed to determine if renal lesions and leptospire continue to be prevalent in striped skunks.

TABLE 3. Serum Creatinine and blood urea nitrogen levels in two groups of skunks.

Group	Number of Skunks	Serum Creatinine*		Urea Nitrogen*	
		Range	Mean (S.D.)	Range	Mean (S.D.)
No renal lesions	10	.1 to .7	0.41 (.22)	12 to 27	10.6 (4.6)
Severe renal lesions	10	.4 to 1.2	0.62 (.23)	18 to 49	27.2 (11.7)

*in mg/dl

LITERATURE CITED

1. ADAMS, W. V., G. E. SANFORD, E. E. ROTH and L. L. GLASGOW. 1964. Nighttime Capture of Striped Skunks in Louisiana. *J. Wild. Manage.* 28: 368-373.
2. BLOOM, F. 1954. *Pathology of the Dog and Cat. The Genitourinary System, with Clinical Considerations.* Am. Vet. Publ., Inc., Evanston, Illinois.
3. KENZY, S. G. and L. M. RINGEN. 1967. In: *Veterinary Bacteriology and Virology.* Ed. by I. A. Merchant and R. A. Packer. 7th ed., Iowa State University Press. Ames, Iowa.
4. KING, W. W. and C. E. COX. 1972. Bacterial Inhibition of Ureteral Smooth Muscle Contractility. I. The Effect of Common Urinary Pathogens and Endotoxin in an in Vitro System. *J. Urol.* 108: 700-705.
5. MURNAGHAN, F. 1976. The significance of Vesico-Ureteral Reflux in the Aetiology of Chronic Pyelonephritis. In: *Proc. 14th Cong. Int. Soc. of Urol., Munich July 9-14.* G et R. Joly, Paris. 429-444.
6. OSBORN, C. A., D. G. LOW and D. R. FINCO. 1972. *Canine and Feline Urology.* W. B. Saunders Co., Philadelphia, Pa.
7. ROTH, E. E., W. V. ADAMS and D. LINDER. 1961. Isolation of *Leptospira canicola* from Skunks in Louisiana. *Publ. Health Rpts.* 76: 335-340.
8. SANFORD, G. E., M. MOORE, K. NEWMAN and B. GREER. 1963. Leptospiuria in Striped Skunks. *Publ. Health Rpts.* 78: 994-1000.
9. NEWMAN, K., M. MOORE, G. E. SANFORD, W. V. ADAMS and B. GREER. 1964. Comparative Cultural Results of Renal Tissue and Urine of Striped Skunks for Leptospire. *Cornell Vet.* LIV: 353-359.
10. SHAPIRO, A. H., M. Y. JAFFRIN and S. L. WEINBERG. 1969. Peristaltic Pumping with Long Wavelengths at Low Reynolds Number. *J. Fluid Mech.* 37: 799-825.

Received for publication 17 November 1976