



## MANDIBULAR LESIONS OF PREHISTORIC ALEUTIAN SEA MAMMALS

Authors: BJOTVEDT, GEORGE, and TURNER, CHRISTY G.

Source: Journal of Wildlife Diseases, 13(4) : 360-365

Published By: Wildlife Disease Association

URL: <https://doi.org/10.7589/0090-3558-13.4.360>

---

BioOne Complete ([complete.BioOne.org](https://complete.BioOne.org)) is a full-text database of 200 subscribed and open-access titles in the biological, ecological, and environmental sciences published by nonprofit societies, associations, museums, institutions, and presses.

Your use of this PDF, the BioOne Complete website, and all posted and associated content indicates your acceptance of BioOne's Terms of Use, available at [www.bioone.org/terms-of-use](https://www.bioone.org/terms-of-use).

Usage of BioOne Complete content is strictly limited to personal, educational, and non - commercial use. Commercial inquiries or rights and permissions requests should be directed to the individual publisher as copyright holder.

---

BioOne sees sustainable scholarly publishing as an inherently collaborative enterprise connecting authors, nonprofit publishers, academic institutions, research libraries, and research funders in the common goal of maximizing access to critical research.

## MANDIBULAR LESIONS OF PREHISTORIC ALEUTIAN SEA MAMMALS

GEORGE BJOTVEDT, Animal Care Office, and CHRISTY G. TURNER II,  
Department of Anthropology, Arizona State University, Tempe, Arizona 85281, USA

**Abstract:** Disarticulated mandibles from prehistoric Aleutian sea mammals showed three general categories of paleopathology: (1) lesions imposed on the dentition and surrounding bone by bacteria and their by-products observed in 13 of 49, (2) lesions associated with periodontal disease observed in 14 of 49, and (3) lesions associated with mechanical attrition in 6 of 49. The sea mammal bones obtained from prehistoric eastern Aleutian village refuse middens suggest that younger and possibly weakened or old animals were preferentially captured by the Aleuts, although it remains to be determined the actual proportion of young to old, and the proportion of sick to healthy, in the natural populations. Radiography may be useful to determine the extent of dento-alveolar abscesses and periodontal disease in the absence of soft tissues for examination.

### INTRODUCTION

Seasonal migration of sea mammals has been occurring in waters adjacent to the eastern Aleutian Islands for at least 4,000 years. These islands are a westward extension of the Alaska Peninsula, lying within the Alaska-Aleutian physiographic province of Alaska, the sub-Arctic life-zone of North American and the Pacific-earthquake zone. For 4,000 to 8,500 years marine mammals from these waters have constituted a major source of protein and the primary source of bone tool and clothing fabrication material for the Aleuts.<sup>5</sup>

During the summer months of 1970-1973, anthropologic studies were conducted on two of these islands (Akun and Akutan, latitude 165°, longitude 54°) to learn about the early inhabitants, their culture, and their adaptation to and utilization of the Aleutian habitat.<sup>6</sup> In the present study of sea mammals, we used excavated mandibles from abandoned Akun and Akutan village sites dating back 1,200 years to describe the assemblage of captured species utilized by the ancient Aleuts.

There appears to be little information available on skeletal and oral pathology of sea mammals, both sub-fossil and living.<sup>6</sup> The following data are presented

so that they may be useful in the natural and comparative study of mammalian oral disease. In this paper, we review the lesions found on the sea mammal mandibles.

### MATERIALS AND METHODS

With the exception of whales, whose skeletal remains were too expensive to return to the laboratory, samples used were collected during excavation. Midden refuse from these sites yielded bones and teeth of the northern sea lion (*Otarioidae*), harbor seal (*Phocidae*), dolphin (*Delphinoidea*), walrus (*Odobenidae*), fur seal (*Arctocephalinae*), sea otter (*Mustelidae*), and whale (*Cetacea*), as well as other mammalian, fish, bird and marine invertebrate remains. The midden excavated from all sites is less than 0.1 of 1% of the total estimated volume of refuse covering a time period of 4,000 years.

The criteria used for determining the sex of the various sea mammal species, where applicable, include: (1) the size of the canine alveolus, (2) the diameter and length of the alveoli, and (3) the arcade thickness and bony protuberance of the corpus mandibulum. Aging was determined by linear size arrangement and appearance of the alveoli and length

of the corpus mandibulum. Some of the disarticulated mandibles were without teeth. No attempt was made to determine the exact age by examining dentin deposition of the canine teeth; instead, individuals were assigned to the age groups: adult, sub-adult or pup.

## RESULTS

Lesions were found only in the adult jaws of fur seals, sea lions, harbor seals and sea otters (Table 1). Dento-alveolar abscesses were associated with the canine tooth. Periostitis of the mandibular bone at the abscess foramen was present, with a sinus tract leading from the opening to the caudal root of the tooth. All jaws with dento-alveolar abscesses had ante-mortem loss of post-canine teeth; alveoli were filled with varying amounts of cancellous bone. In the case of the harbor seals, all the post-canine alveoli were filled with cancellous bone (Figure 1).

X-ray films of the dento-alveolar abscesses revealed necrotic extensions to adjacent bone marrow spaces, producing osteomyelitis. Radiolucent areas were present at canine alveolar apices and adjacent first post canine teeth in sea lions and fur seals and at the second premolar in some of the sea otters (Figure 2).

Radiographic evidence of periodontal disease was recognized in the adult sea lion and sea otter groups (14/49). Irregularities of the alveolar crest were noted in the post-canine teeth of the sea lions and the premolars and molars of the sea otters. Alveolar crest destruction was pronounced in the sea lion jaws. This

bony change occurred frequently and in about equal proportion among males and females in the sea lions. Alveolar crest destruction was more subtle in the sea otter.

Dental anomalies or healed mandibular fractures were not observed in our sea mammal group. Enamel attrition was noted in the sea otters (3/5).

Sex dimorphism is pronounced in the teeth and jaws of adult and sub-adult fur seals, harbor seals and sea lions. Dolphins and sea otters could not be sexed by us. In the case of pups, sex is readily discernible in the fur seal and sea lion due to their monophyodont dentitions. The number and nature of the sampled species is listed (Table 2). Fur seal pups, in about equal proportions of males and females, occur most frequently. Of all adults, more females seem to have been captured.

## DISCUSSION

The dental formula of the permanent

teeth is  $\begin{matrix} 3 & 1 & 4 & 1 \\ I & C & P & M \\ 2 & 1 & 4 & 1 \end{matrix}$  in the sea lion

and harbor seal,  $\begin{matrix} 3 & 1 & 4 & 2 \\ I & C & P & M \\ 2 & 1 & 4 & 1 \end{matrix}$  in the

fur seal, and  $\begin{matrix} 3 & 1 & 3 & 1 \\ I & C & P & M \\ 2 & 1 & 3 & 2 \end{matrix}$  in the sea

otter. The adaptive significance of the numerical variations observed in the dentition of sea lions, fur seals, harbor seals and sea otters has been reported.<sup>1,2,4</sup>

TABLE 1. Oral lesions in adult sea mammals.

	Alveolar Abscess	Periodontal Disease	Attrition
Fur seal ( <i>Callorhinus ursinus</i> )	4/7	0/7	0/7
Sea lion ( <i>Eumetopias jubatus</i> )	5/33	9/33	0/33
Harbor seal ( <i>Phoca vitulina</i> )	3/4	0/4	0/4
Sea otter ( <i>Enhydra lutris</i> )	1/5	5/5	3/5
Total	13/49	14/49	3/49

These variations may be interpreted as examples of evolutionary recession towards the full mammalian dentition. The animals being discussed are those which have adapted to an aquatic environment. We may reasonably state that sea mammal dentition, with the possible exception of the sea otter and walrus, is important in grasping and tearing their prey. With loss of teeth, these sea mammals would experience difficulty in capturing their

prey and would decrease their effectiveness as predators of marine forms.<sup>7</sup> In our sample, the gross and radiological changes seen in the 13/49 jaw specimens from the adult fur seal, sea lion, harbor seal and sea otter seem to represent varying stages of dental abscesses. Correction of dental abscesses requires extraction of affected teeth. Chronicity of these abscesses may be inferred, since the canine tooth or remnant was present in

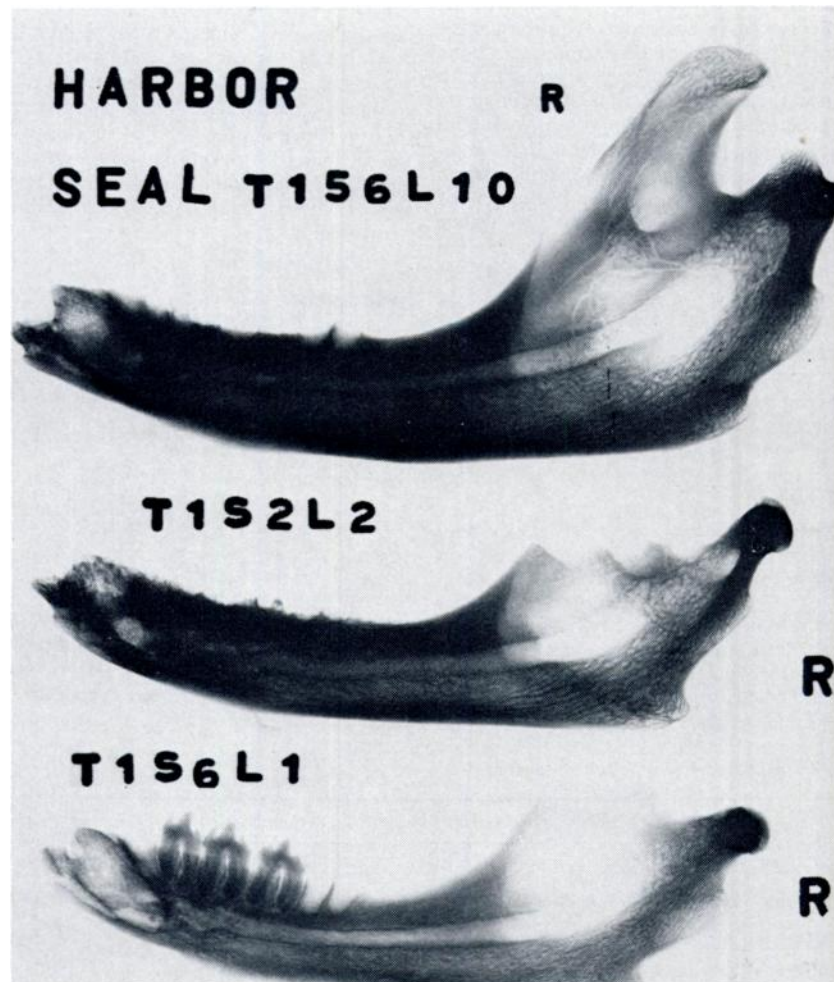


FIGURE 1. Lateral radiographic view of mandibles of harbor seals, top two showing antemortem loss of post canine teeth, bottom some post canine teeth in alveoli.

all cases. The reoccurrence of dental disease would seemingly inconvenience these animals, thus making them easy to capture by Aleut hunters.

Observations of lesions on California sea lions and dolphins from the Naval Undersea Center of San Diego has led to

the conclusion that mandibular lesions are associated with fractures. (J. C. Sweeney, pers. comm.). These open fractures commonly occur behind the second premolar and osteomyelitis develops. No evidence of healed fractures was present in our sample.

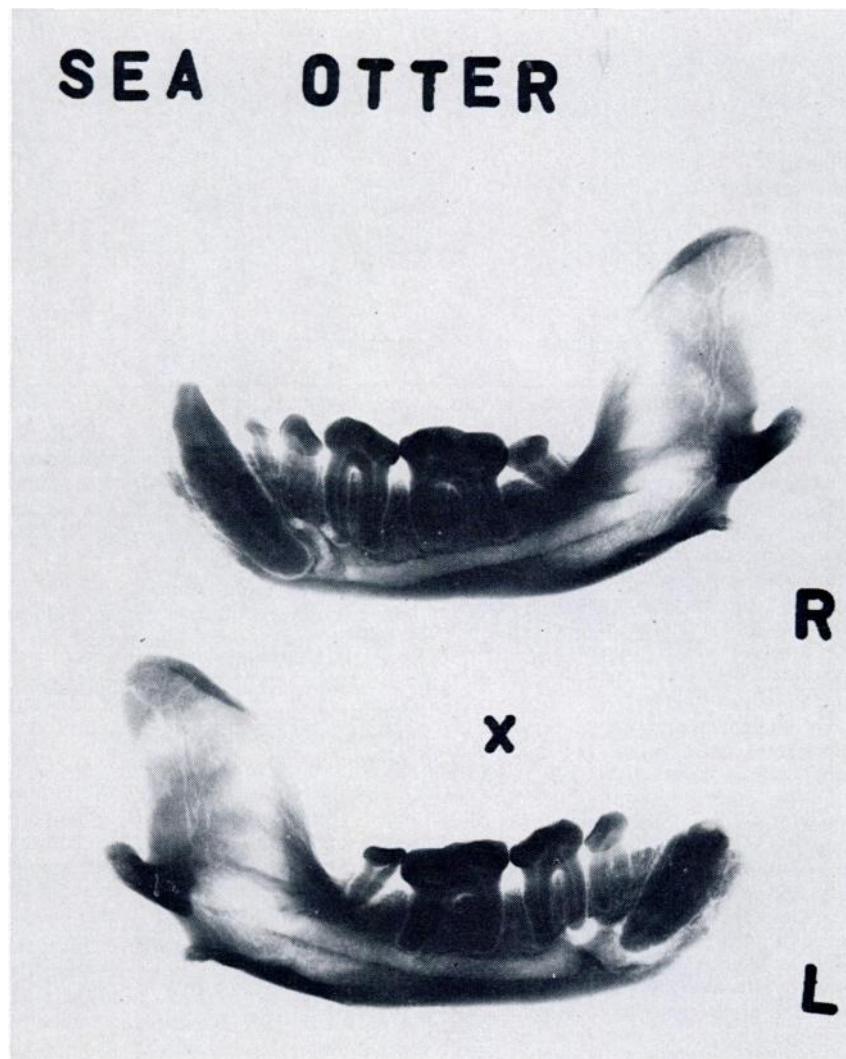


FIGURE 2. Lateral radiographic view of mandibles of sea otters, showing typical alveolar crest destruction—periodontal disease, bottom, canine tooth with alveolar abscess.

TABLE 2. Sea mammal representation from abandoned Aleut village middens on Akun and Akutan Islands (individual count based on lower jaws).

Species		Adults			Sub-adults			Pups			Total
		M	F	?	M	F	?	M	F	?	
Fur seal ( <i>Callorhinus ursinus</i> )	Left	4	1	0	3	5	0	38	28	0	79
	Right	0	2	0	4	3	0	36	38	0	83
Sea lion ( <i>Eumetopias jubatus</i> )	Left	5	13	0	2	5	0	1	1	0	27
	Right	4	11	0	1	1	0	0	0	0	17
Harbor seal ( <i>Phoca vitulina</i> )	Left	0	0	0	6	2	0	0	0	6	14
	Right	2	2	0	7	5	0	0	0	0	16
Dolphin ( <i>Tursiops truncatus</i> )	Left	0	0	9	0	0	0	0	0	0	9
	Right	0	0	5	0	0	0	0	0	0	5
Sea otter ( <i>Enhydra lutris</i> )	Left	0	0	2	0	0	0	0	0	0	2
	Right	0	0	3	0	0	0	0	0	0	3
Whale ( <i>Balaena glacialis</i> )	Left	0	0	1	0	0	0	0	0	0	1
	Right	0	0	0	0	0	0	0	0	0	0
Total		15	29	20	23	21	0	75	67	6	256

The presence of periodontal disease, most frequent in the adult sea lion should be considered as part of the general aging process. Regressive changes in sea lion teeth occur with sufficient frequency to create some doubt if such teeth should be considered diseased. In the case of the sea otter, the frequency of periodontal disease with associated enamel attrition should be considered diseased. The etiology of the periodontal disease is poorly understood at present.

We obtained a preliminary measure of oral lesions in Aleutian sea mammals dating mainly from A.D. 1900 to A.D. 780. The adaptive significance of oral lesions in sea mammals is unknown, and would be impossible to assess accurately without clinical examination of the animals and population studies. However, approximately 20% of all adult jaws had abscesses with necrosis of bone and loss of teeth; likely this interferes with food gathering. If mandibular lesions can be used as a crude measure of fitness, then possibly Aleut predation was selective and could have indirectly contributed to the overall fitness of sea mammals in the Aleutian area by eliminating the weaker individuals.

Excluding those animals we could not sex, it is apparent that the Aleuts were capturing more adult females than males (Table 2). Of sub-adults and pups, females were taken in approximately the same number as males.

In the sub-adult group, where sex dimorphism is not obviously discernible by a predator, random capturing of males and females could be possible assuming they were in equal numbers. In addition, capturing sub-adults would be less hazardous than their comparable adult companions.

A relatively large number of fur seal pups were captured. This apparently heavy premodern mortality could be explained by the abundance of this species and the relative ease of taking such immature animals.<sup>3</sup>

Natural predation would include the selection of younger, weaker and old members. It would have been advantageous for the prehistoric Aleuts to behave as natural predators, serving to maintain and enhance the ecological system, as well as to minimize hunting accidents and hazards to themselves.

**LITERATURE CITED**

1. BJOTVEDT, G. and C. G. TURNER, II. 1976. Tooth trauma and feeding behavior in prehistoric Aleutian Sea Otters. *Vet. Med., Sm. An. Clin.* 71: 831-833.
2. CHIASSON, R. B. 1957. The dentition of the Alaskan Fur Seal. *J. Mammal.* 38: 310-319.
3. KENYON, K. W. and F. WILKE. 1953. Migration of the Northern Fur Seal. *Callorhinus Ursinus*. *J. Mammal.* 34: 86-97.
4. KUBOTA, K. and S. TOGAWA. 1964. Numerical variations in the dentition of some pinnipeds. *Anat. Rec.* 150: 487-501.
5. LAUGHLIN, W. S. and W. G. REEDER. 1962. Aleut-Konyag prehistory and ecology. *Arctic Anthropology*. 1-1: 104-108.
6. RIDGWAY, S. H., J. R. GERACI and W. MEDWAY. 1975. Diseases of pinnipeds. *Rapp P-V Reun. Cons. Int. Explor Mer.* 169: 327-337.
7. STIRLING, I. 1969. Tooth wear as a mortality factor in the Weddell Seal, *Leptonychotes Weddell*. *J. Mammal.* 50: 559-565.
8. TURNER II, C. G., J. S. AIGNER and L. R. RICHARDS. 1974. Chaluka stratigraphy. Umnak Island, Alaska *Arctic Anthropology*. XI: 125-142.

*Received for publication 25 April 1977*

---