



## **TOXOPLASMOSIS, DISTEMPER, AND HERPESVIRUS INFECTION IN A SKUNK (*Mephitis mephitis*) 1**

Authors: DITERS, RICHARD W., and NIELSEN, SVEND W.

Source: Journal of Wildlife Diseases, 14(1) : 132-136

Published By: Wildlife Disease Association

URL: <https://doi.org/10.7589/0090-3558-14.1.132>

---

BioOne Complete ([complete.BioOne.org](https://complete.BioOne.org)) is a full-text database of 200 subscribed and open-access titles in the biological, ecological, and environmental sciences published by nonprofit societies, associations, museums, institutions, and presses.

Your use of this PDF, the BioOne Complete website, and all posted and associated content indicates your acceptance of BioOne's Terms of Use, available at [www.bioone.org/terms-of-use](http://www.bioone.org/terms-of-use).

Usage of BioOne Complete content is strictly limited to personal, educational, and non - commercial use. Commercial inquiries or rights and permissions requests should be directed to the individual publisher as copyright holder.

---

BioOne sees sustainable scholarly publishing as an inherently collaborative enterprise connecting authors, nonprofit publishers, academic institutions, research libraries, and research funders in the common goal of maximizing access to critical research.

## TOXOPLASMOSIS, DISTEMPER, AND HERPESVIRUS INFECTION IN A SKUNK (*Mephitis mephitis*)<sup>□</sup>

RICHARD W. DITERS and SVEND W. NIELSEN, Northeastern Research Center for Wildlife Diseases, College of Agriculture and Natural Resources, University of Connecticut, Storrs, Connecticut 06268, USA

**Abstract:** A striped skunk (*Mephitis mephitis*) showing abnormal behavior had histopathologic lesions of toxoplasmosis and canine distemper in addition to intranuclear, eosinophilic inclusions in the reticuloendothelial cells of the spleen, liver and lung. The inclusions, on electron microscopic examination, were compatible with herpesvirus infection.

### INTRODUCTION

Toxoplasmosis and canine distemper are common diseases of wild mustelids, procyonids, and canids.<sup>13,17</sup> Surveys have shown that many wild animals have serum antibodies against both agents.<sup>8,15</sup> The toxoplasmosis-distemper complex, which has been reported to occur in dogs, also has been seen frequently in wildlife.<sup>3</sup> Møller speculated that distemper virus infection may lower resistance and promote development of latent toxoplasmosis into a fulminating disease process.<sup>12</sup>

This paper describes a case of canine distemper virus infection complicated by toxoplasmosis and records the morphologic evidence of a herpesvirus infection in a striped skunk (*Mephitis mephitis*).

### MATERIALS AND METHODS

On 12 December, 1976, a wild male striped skunk was submitted for necropsy to the Northeastern Research Center for Wildlife Diseases. The case history disclosed that the

animal had been wandering blindly in a suburban neighborhood of Old Lyme, Connecticut, and showed erratic behavior, including staggering, circling, stumbling, and bumping into objects.

Tissues taken at necropsy were fixed in 10% phosphate buffered formalin, embedded in paraffin, sectioned at 6  $\mu$ m, and stained with hematoxylin and eosin. Feulgen's DNA stain, methyl-pyronin green, periodic acid-Schiff, Schorr's, Macchiavello's rickettsial stain, Giemsa, and Pollack's trichrome were used as needed.

Tissues for electron microscopy were dissected from 10% formalin fixed spleen, washed overnight in several changes of 1/15 M phosphate buffer (pH 7.0), and postfixed for 1 h. in 2% osmium tetroxide. Following fixation, the specimens were washed in distilled water, dehydrated in a graded series of ethanol solutions, cleared in propylene oxide, and embedded in DER 334. Thin sections were cut on an LKB ultramicrotome III, stained with uranyl acetate and lead citrate, and examined with a Philips EM 300 electron microscope.

<sup>□</sup> Scientific Contribution No. 680, Storrs Agricultural Experiment Station, University of Connecticut, Storrs, Connecticut 06268, USA

## NECROPSY AND HISTOLOGIC FINDINGS

### Gross Pathology

The haircoat was in excellent condition and body fat was abundant. A slight purulent discharge from the eyes was observed. Grayish, raised nodules, 0.3 to 1.0 cm in diameter, were present on the pleura and within the parenchyma of the lungs. These nodules were firm and of uniform color. The small bronchioles were filled with a yellowish mucoid material. Small white foci were seen on the serosal and cut surfaces of the liver. The spleen was of normal size, slightly firm when cut, and brick red. There was a moderate amount of fresh ingesta in the stomach and intestines. All other organs appeared normal.

### Histopathology

Microscopically, the pulmonary nodules were areas of necrosis,

hemorrhage and fibrin exudation. A few neutrophils and mononuclear cells were present, often in various stages of degeneration. Within nodules the parenchymal architecture was completely obliterated. Several *Toxoplasma gondii* were seen in macrophages and cysts in the lung tissue surrounding the fibrino-necrotic foci, whereas free forms were seen in the necrotic areas (Fig. 1). Lung tissue surrounding these foci was hyperemic, and edematous with prominent alveolar cell hyperplasia. The pleural mesothelium overlying the areas of necrosis and acute inflammation was hyperplastic. Intracytoplasmic inclusion bodies of canine distemper virus were present in epithelial cells of the bronchi and within multinucleate syncytial alveolar lining cells. Large, dark-staining eosinophilic intranuclear inclusions were seen occasionally in fixed alveolar macrophages.

Splenic germinal centers were small and did not stand out from the sur-

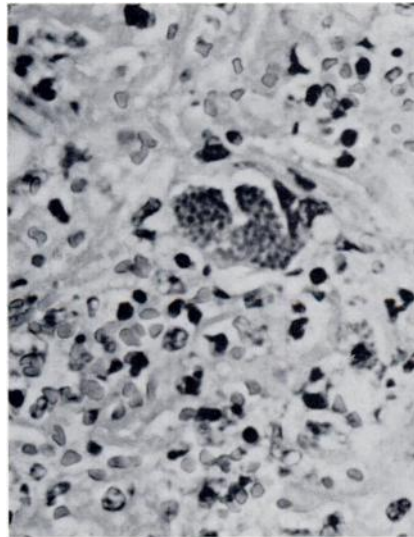


FIGURE 1. Pulmonary section from edge of necrotic focus depicting severe hemorrhage, fibrin exudation, and one large *Toxoplasma* cyst. H & E; X530.

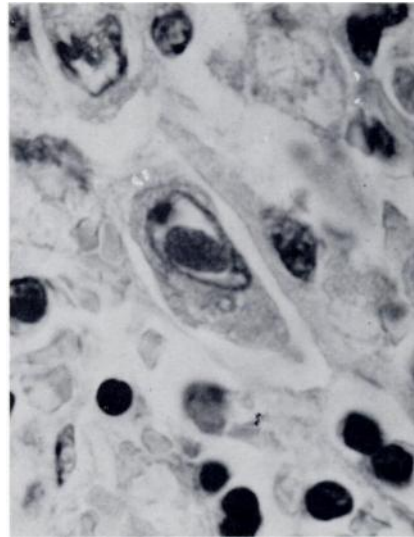


FIGURE 2. Reticuloendothelial cell of spleen containing a large eosinophilic intranuclear inclusion body. H & E; X1300.

rounding red pulp. Minute multifocal areas of necrosis and neutrophilic infiltration were present. Many large reticuloendothelial cells contained large, centrally located, dark-staining intranuclear inclusions surrounded by a narrow halo with margination of chromatin (Fig. 2). Nucleoli were displaced to the margin of the nucleus.

The inclusion bodies were Feulgen-negative but slightly DNA-positive using methyl-pyronin green. With Schorr's stain they appeared a deep brownish red. The inclusions did not stain by the periodic acid-Schiff reaction. Macchiavello's rickettsial staining technique resulted in a red to pink stain, and with Pollack's trichrome, inclusions varied from red to blue. These staining reactions are consistent with those of other herpesvirus inclusions.<sup>2,18</sup>

Randomly distributed, well delineated, small foci of necrosis associated with *Toxoplasma* cysts were evident in the liver. Large intranuclear inclusion bodies, similar to those observed in the spleen, were occasionally seen in Kupffer cells. Canine distemper virus inclusions were present in the epithelium of the bile ducts, renal pelvis, urinary bladder, and ductuli efferentes of the testes.

Multifocal glial proliferations, mild nonsuppurative leptomeningitis, and mild lymphocytic perivascular cuffing were present in the brain.

#### Electron Microscopy

Electron microscopic examination of the spleen revealed numerous viral particles within nuclei of reticuloendothelial cells (Fig. 3). The intranuclear inclusions observed with the light microscope consisted of prominent laminar filamentous structures, which resembled microtubules, and non-enveloped viral particles. Virions had a central core of electron-dense material

about 35 to 45 nm in diameter, surrounded by a narrow electron-lucent zone. An electron-dense band, measuring approximately 80 to 90 nm in diameter, surrounded both structures. Viral particles, found outside the nucleus, measured 125 to 140 nm. The morphology and size of the virus and replication in the nucleus are consistent with that of the herpesvirus group.<sup>2,4,16</sup>

#### DISCUSSION

The focal fibrino-necrotic pneumonia seen is typical of fulminating pulmonary toxoplasmosis in cats and dogs.<sup>7,14</sup> The acute nature of the toxoplasmosis lesions and simultaneous distemper virus infection support the hypothesis that distemper may facilitate the development of fatal toxoplasmosis.<sup>10,12</sup>

A remarkable finding was the incidental occurrence of large intranuclear herpesvirus inclusion bodies in reticulum cells of the lung, liver and spleen. The association of tissue damage and the presence of herpesvirus inclusions could not be ascertained in the present case, partly because of the severe lesions caused by *T. gondii* and distemper virus. To our knowledge no herpesviruses associated with lesions of the type described here have been reported in free-living striped skunks. However, isolations of human type strains of herpesvirus have been documented in pet skunks and may be associated with herpetic encephalitis.<sup>5,9</sup>

According to McKercher, herpesviruses are ubiquitous in nature and naturally occurring herpesvirus infections are found among most common domestic and laboratory animal species.<sup>11</sup> The number of wildlife species examined for herpesvirus has been limited but recent isolations have been made in the cottontail rabbit (*Sylvilagus floridanus*),<sup>6</sup> kinkajou (*Potos*

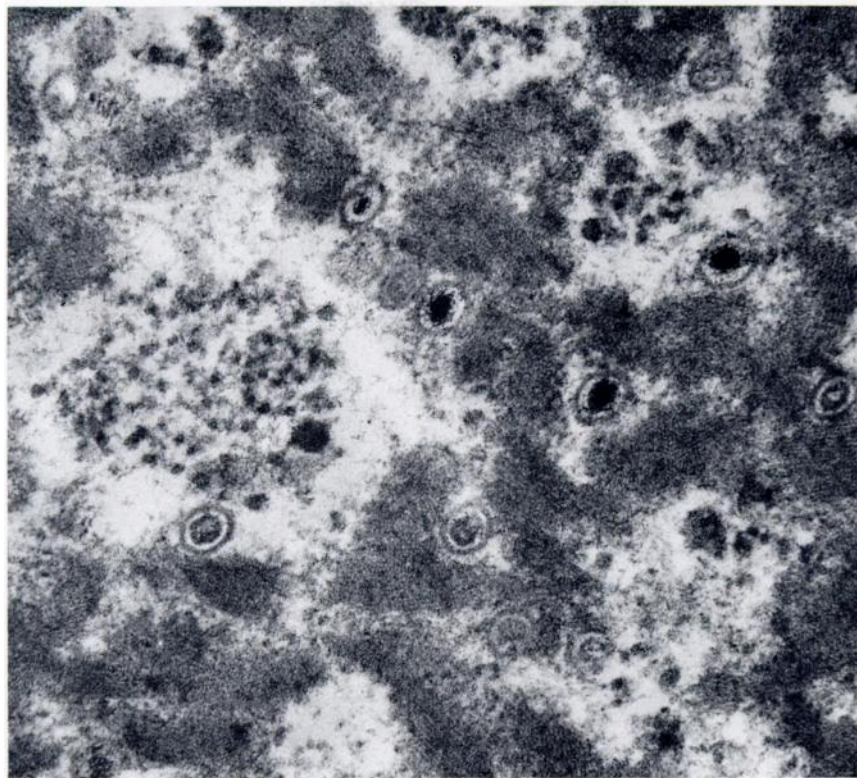


FIGURE 3. An electron micrograph of an intranuclear inclusion illustrating two different forms of non-enveloped viral particles. X67,500.

*flavus*),<sup>1</sup> and fallow deer (*Dama dama*).<sup>19</sup> Herpesviruses are known for their ability to produce long lasting latent infections which may flare up as a result of lowered host resistance.<sup>4,11</sup> Infection with canine distemper virus and *T. gondii* may have lowered host resistance of this skunk sufficiently to allow development of herpetic lesions.

#### Acknowledgements

The authors wish to express their appreciation to Dr. Lamia Khairallah for her advice and technical skill on electron microscopy.

#### LITERATURE CITED

1. BARAHONA, H. H., B. F. TRUM, L. V. MELENDEZ, F. G. GARCIA, N. W. KING, M. D. DANIEL and D. A. JACKMAN. 1973. A new herpesvirus isolated from kinkajous (*Potos flavus*). *Lab. Anim. Sci.* 23: 830-836.
2. BURNET, F. M. and W. M. STANLEY, Editors. 1961. *The Viruses*. Vol. 3. Academic Press, New York.

3. CAMPBELL, R. S. F., W. B. MARTIN and E. D. GORDON. 1955. Toxoplasmosis as a complication of canine distemper. *Vet. Rec.* 67: 708-712.
4. CHEVILLE, N. F. 1975. Cytopathology of viral diseases. *Monogr. Virol.* 10: 1-235.
5. EMMONS, R. W. and E. H. LENNETTE. 1968. Isolation of herpesvirus hominis from naturally infected pet skunks. *Health Lab. Sci.* 5: 31-37.
6. HINZE, H. C. 1971. A new member of the herpesvirus group isolated from cottontail rabbits. *Infect. Immun.* 3: 350-354.
7. HIRTH, R. S. and S. W. NIELSEN. 1969. Pathology of feline toxoplasmosis. *J. Small Anim. Pract.* 10: 213-221.
8. JAMISON, R. K., E. C. LAZAR, L. N. BINN and A. D. ALEXANDER. 1973. Survey for antibodies to canine viruses in selected wild animals. *J. Wildl. Dis.* 9: 2-3.
9. KANITZ, C. L. and M. E. WOODRUFF. 1976. A herpesvirus isolated from a skunk: Serologic relationship to other viruses of the herpes group. *Proc. 19th Annual Meet., Am. Ass. Vet. Lab. Diag.*: 1-12.
10. MANGI, R. J., T. P. UNYER, S. KRAKOWKA, R. O. JACOBY and F. S. KANTOR, 1976. A canine distemper model of virus-induced anergy. *J. Infect. Dis.* 133: 556-563.
11. McKERCHER, D. G. 1973. Viruses of other vertebrates. pp. 427-493. In: *The Herpesviruses*. A. S. Kaplan, ed. Academic Press, New York.
12. MØLLER, T. 1951. Et tilfælde af letalt forlobende toxoplasmosis hos en hund. *Nord. Vet.-Med.* 3: 1073-1093.
13. ——— and S. W. NIELSEN. 1964. Toxoplasmosis in distemper-susceptible carnivores. *Path. Vet.* 1: 189-203.
14. NIELSEN, S. W. 1969. Infectious granulomas. pp. 590-632. In: *Joest's Handbuch Speziellen Pathologischen Anatomie der Haustiere*. Third edition. Paul Parey, Berlin.
15. QUINN, P. J., R. O. RAMSDEN and D. H. JOHNSTON. 1976. Toxoplasmosis: A serological survey in Ontario wildlife. *J. Wildl. Dis.* 12: 504-510.
16. RABIN, E. R. and A. B. JENSON. 1967. Electron microscopic studies of animal viruses with emphasis on *in vivo* infections. *Progr. Med. Virol.* 9: 392-450.
17. SMITH, H. A., T. C. JONES and R. D. HUNT. 1972. *Veterinary Pathology*. Fourth ed. Lea and Febiger, Philadelphia, Pennsylvania.
18. THOMPSON, S. W. and R. D. HUNT. 1966. *Selected Histochemical and Histopathologic Methods*. Charles C. Thomas, Publisher, Springfield, Illinois.
19. THORSEN, J., L. KARSTAD, M. W. BARRETT and G. A. CHALMERS. 1977. Viruses isolated from captive and free-ranging wild ruminants in Alberta. *J. Wildl. Dis.* 13: 74-79.

Received for publication 31 May 1977