



## **Sarcocystis AND RELATED ORGANISMS IN AUSTRALIAN WILDLIFE: I. SURVEY FINDINGS IN MAMMALS.**

Authors: MUNDAY, B. L., MASON, R. W., HARTLEY, W. J., PRESIDENTE, P. J. A., and OBENDORF, D.

Source: Journal of Wildlife Diseases, 14(4) : 417-433

Published By: Wildlife Disease Association

URL: <https://doi.org/10.7589/0090-3558-14.4.417>

---

BioOne Complete ([complete.BioOne.org](https://complete.BioOne.org)) is a full-text database of 200 subscribed and open-access titles in the biological, ecological, and environmental sciences published by nonprofit societies, associations, museums, institutions, and presses.

Your use of this PDF, the BioOne Complete website, and all posted and associated content indicates your acceptance of BioOne's Terms of Use, available at [www.bioone.org/terms-of-use](http://www.bioone.org/terms-of-use).

Usage of BioOne Complete content is strictly limited to personal, educational, and non - commercial use. Commercial inquiries or rights and permissions requests should be directed to the individual publisher as copyright holder.

---

BioOne sees sustainable scholarly publishing as an inherently collaborative enterprise connecting authors, nonprofit publishers, academic institutions, research libraries, and research funders in the common goal of maximizing access to critical research.

## ***Sarcocystis* AND RELATED ORGANISMS IN AUSTRALIAN WILDLIFE: I. SURVEY FINDINGS IN MAMMALS.**

B. L. MUNDAY and R. W. MASON, Mt. Pleasant Laboratories, P.O. Box 46, Launceston South, Tasmania.  
W. J. HARTLEY, Department of Veterinary Clinical Studies, University of Sydney, Camden, New South Wales.  
P. J. A. PRESIDENTE and D. OBENDORF, Department of Veterinary Paraclinical Sciences, University of Melbourne, Veterinary Clinical Centre, Werribee, Victoria, Australia.

**Abstract:** Muscle samples from 1497 Australian mammals, comprising 73 species (2 monotreme, 48 marsupial, 3 cetacean, 1 lagomorph, 10 rodent, 2 canid, 3 chiropteran and 4 cervid) were examined histologically for cysts of *Sarcocystis*. Cysts were recorded in 126 (8.4%) of the mammals examined. Type A cysts (cysts with thick walls and/or large zoites and/or internal trabeculation) were found in 77 (5.1%) of these mammals, representing 13 species (4 marsupial, 1 cetacean, 1 lagomorph and 7 rodent). Type B cysts (cysts with thin walls and small zoites) were found in 50 (3.3%) of the animals, representing 20 species (14 marsupial, 1 cetacean and 5 rodent).

The greatest prevalence of type A cysts (21.1%) was found in rabbits, *Oryctolagus cuniculus*. Among the rodents examined, type A cysts were more frequently encountered (11.1%) than type B (2.2%). In four species, *Rattus fuscipes*, *R. lutreolus*, *R. rattus* and *Mus musculus*, both types of cyst were found. Both types of cyst also were recorded in the macropodid marsupials, but type B cysts were encountered more frequently (7.2%) than type A cysts (1.7%) and only in one species, *Macropus rufus*, were both forms detected. Type B cysts were found in macropods in Tasmania as well as on the mainland of Australia, whereas only the mainland marsupials harbored type A cysts.

Scrapings of intestinal mucosa or feces were examined from 92 dasyurid marsupials, comprising 5 species, and from 55 feral cats (*Felis domesticus*). Sporulated sporocysts typical of *Sarcocystis* or *Frenkelia* were found in 1 Tasmanian devil, *Sarcophilus harrisii*, 1 tiger cat, *Dasyurus maculatus*, and 1 feral cat.

### **INTRODUCTION**

There are very few published reports of *Sarcocystis* in wildlife in Australia. In their survey of the literature, Kalyakin and Zasukhin<sup>9</sup> found references for sarcocysts in four marsupial species (*Dasyurus hallucatus*, *Isodon obesulus*, *Bettongia lesueri*, and *Macropus rufogriseus*), and three rodent species (*Rattus rattus*, *R. norvegicus* and *R. fuscipes*). Rzepczyk<sup>19</sup> has described a species of *Sarcocystis* in the southern bush-rat, *R. fuscipes*, which has as its definitive host the python, *Morelia spilotes*. Sarcocysts have been reported in another five species of Australian rats (*Uromys caudimaculatus*, *Melomys cer-*

*vinipes*, *Melomys littoralis*, *R. sordidus* and *R. lutreolus*) by workers in northern Queensland<sup>8</sup> (Glazebrook, pers. comm.). In addition, Owen and Kakulas<sup>17</sup> found sarcocysts in a sperm whale, *Physeter catadon*. Sporulated, isosporan-type sporocysts typical of *Sarcocystis* or *Frenkelia* have been reported in feces of the dingo, *Canis familiaris dingo*.<sup>1</sup>

The paucity of published information prompted a survey of available material for *Sarcocystis* and related organisms. In this first communication on our findings, results of the examination of Australian mammals are presented. Survey findings in birds and reptiles will be given in Part II.<sup>15</sup>

## MATERIALS AND METHODS

### Examination for muscle cysts

Muscle samples were obtained from 1497 mammals, consisting of 73 species (Table 1). The majority of these animals was collected in the southern states of eastern Australia (i.e. New South Wales, Victoria and Tasmania). Some specimens came from South Australia, Queensland and the Northern Territory. Specimens were obtained during various scientific collections, as part of pest-control programs, or as road-killed animals.

For each animal, striated muscle was examined from one or more of the following sites: heart, diaphragm, tongue, abdominal muscle, pectoral muscle and limb muscle. These tissues were fixed in 10% formol saline or 70% alcohol at the time of collection, processed routinely, sectioned at 6-10  $\mu\text{m}$ , and stained with hematoxylin and eosin (H&E).

For cysts found, the features noted were size, type of wall, presence or absence of trabeculae, and relative size of zoites.

Electron microscopic examination of *Sarcocystis*-infected muscles was attempted in tissues where cysts were present in large numbers. Portions of formalin-fixed muscle were post-fixed in osmium and embedded in Spurr's medium. Sections were stained with uranyl acetate and lead citrate and then examined in a Philips 201 electron microscope at 60KV.

### Examination for oocysts or sporocysts

Scrapings of the intestinal mucosa from 92 carnivorous marsupials were diluted with physiological saline and examined for sporulated, isosporan-type oocysts or sporocysts. These consisted of five dasyurid species: 1 swamp antechinus (*Antechinus minimus*), 3 dusky antechinus (*A. swainsonii*), 27 quolls (*Dasyurus viverrinus*), 11 tiger cats (*D. maculatus*) and 50 Tasmanian devils (*Sarcophilus harrisi*).

TABLE 1. Prevalence of protozoan cysts in muscle of some Australian mammals.

FAMILY Species	Number Examined		Type A cysts (thick walls and/or large zoites and/or trabeculation)	Type B cysts (thin walls small zoites)
	Total	Infected		
<b>MONOTREMATA</b>				
Echimididae				
Negative mammals*	7	0		
Ornithorhynchidae				
Negative mammals*	2	0		
<b>MARSUPIALIA</b>				
Dasyuridae				
<i>Antechinus stuartii</i>	44	4		4
<i>Antechinus swainsonii</i>	12	1		1
<i>Sarcophilus harrisi</i>	29	1		1

TABLE 1. (continued).

Negative mammals*	0		6
Total	142	(4.2%)	
<b>Peramelidae</b>			
<i>Perameles gunnii</i>	31	3	3
<i>Perameles nasuta</i>	2	1	1
<i>Isodon macrourus</i>	1	1	1
Negative mammals*	24	0	
Total	58	5 (8.6%)	5
<b>Phalangeridae</b>			
<i>Trichosurus caninus</i>	44	2	2
<i>Trichosurus vulpecula</i>	155	1	1
Total	199	3 (1.5%)	3
<b>Burramyidae</b>			
Negative mammals*	8	0	
<b>Petauridae</b>			
<i>Pseudocheirus archeri</i>	1	1	1
Negative mammals*	46	0	
Total	47	1 (2.1%)	1
<b>Macropodidae</b>			
<i>Thylogale billardieri</i>	123	2	2
<i>Peradorcas concinna</i>	3	2	2
<i>Petrogale venustula</i>	4	3	3
<i>Macropus agilis</i>	3	1	1
<i>Macropus giganteus</i>	18	2	2
<i>Macropus rufogriseus</i>	105	14	14
<i>Macropus rufus</i>	47	7	6
<i>Wallabia bicolor</i>	2	1	1

TABLE 1. (continued).

FAMILY Species	Number Examined		Type A cysts (thick walls and/or large zoites and/or trabeculation)	Type B cysts (thin walls small zoites)
	Total	Infected		
Negative mammals*	55	0		
Total	360	32 (8.9%)	6	26
Phascolarctidae				
Negative mammals*	6	0		
Vombatidae				
Negative mammals*	39	0		
EUTHERIA				
Balaenopteridae				
Negative mammals*	1	0		
Physeteridae				
<i>Physeter catadon</i>	1	1	1	
Delphinidae				
<i>Delphinus</i> sp.	3	1		1
Leporidae				
<i>Oryctolagus cuniculus</i>	109	23 (21.1%)	23	
Muridae				
<i>Hydromys chrysogaster</i>	27	1		1
<i>Rattus fuscipes</i>	50	15	13	2
<i>Rattus lutreolus</i>	43	15	13	2
<i>Rattus norvegicus</i>	47	3	3	
<i>Rattus rattus</i>	73	14	11	3
<i>Pseudomys higginsi</i>	18	3	3	
<i>Mastomys fuscus</i>	3	1	1	
<i>Mus musculus</i>	141	2	1	1

TABLE 1. (continued).

Negative mammals*	4	0		
Total	406	54 (13.3%)	45	9
Canidae				
Negative mammals*	3	0		
Otariidae				
Negative mammals*	27	0		
Vespertilionidae				
Negative mammals*	7	0		
Cervidae				
Negative mammals*	72	0		
TOTAL	1497	126 8.4%	76 5.1%	50 3.3%
% of total sample			60.3%	39.7%
% of infected mammals				

\*NEGATIVE MAMMALS. Echidnidae: *Tachyglossus aculeatus* (7); Ornithorhynchidae: *Ornithorhynchus anatinus* (2); Dasyuridae: *Planigale* sp. (2); *Antechinus minimus* (7); *A. rosamondae* (4); *Dasyurus maculatus* (7); *D. viverrinus* (27); *Sminthopsis leucopus* (10); Peramelidae: *Isodon obesulus* (24); Burramyidae: *Cercartetus lepidus* (6); *C. nanus* (2); Petauridae: *Gymnobelideus leadbeateri* (2); *Petaurus breviceps* (2); *Pseudochirus dahlia* (2); *P. herbertensis* (1); *P. peregrinus* (39); Macropodidae: *Hypsiprymnodon moschatus* (2); *Potorous tridactylus* (16); *Bettongia gaimardi* (3); *Aepyprymnus rufescens* (3); *Thylogale stigmatica* (1); *Petrogale godmani* (1); *P. purpureicollis* (1); *Lagorchestes conspicillatus* (3); *Macropus bernardus* (1); *M. dorsalis* (5); *M. eugenii* (12); *M. fuliginosus* (4); *M. robustus* (2); *Dendrolagus lumholtzi* (1); Phascolarctidae: *Phascolarctos cinereus* (6); Vombatidae: *Vombatus ursinus* (37); *Lasiorchinus latifrons* (2); Balaeopteridae: *Balaenoptera acutorostrata* (1); Muridae: *Rattus villosissimus* (3); *Pseudomys novaehollandiae* (1); Canidae: *Vulpes vulpes* (3); Otariidae: *Arctocephalus doriferus* (27); Vespertilionidae: *Pipistrellus tasmaniensis* (1); *Eptesicus pumilus* (5); *Nyctophilus geoffroyi* (1); Cervidae: *Cervus timorensis* (4); *C. unicolor* (2); *Dama dama* (45); *Axis procinus* (21).

Feces were collected from the rectum of 55 feral cats (*Felis domesticus*). Oocysts and sporocysts were demonstrated in these samples by flotation in sucrose solution (sp. gr. 1.15) and examination of the washed supernatant at 125X.

## RESULTS

### Examination for muscle cysts

Muscle cysts were not found in the majority (91.6%) of 1497 mammals examined (Table 1). Where cysts were detected they were arbitrarily classified as type A cysts or type B cysts. Type A cysts were those cysts which had thick walls and/or large zoites and/or internal trabeculation; all attributes frequently found in *Sarcocystis* spp. Type B cysts were those cysts with thin walls and small zoites and, therefore, could have belonged to the genera *Sarcocystis*, *Hammondia* or *Toxoplasma*.

#### I. Type A cysts

Type A cysts were found in 4 marsupial, 1 cetacean, 1 lagomorph and 7

rodent species (Table 1). None of this type of cyst was found in Tasmanian marsupials although some were detected in 1 kangaroo, 2 rock-wallabies and a petaurid marsupial from mainland Australia. However, type A cysts were found in rats and rabbits throughout Australia.

### Marsupials

Sarcocysts were numerous in the skeletal muscles, but not the hearts, of 2 little rock-wallabies, *Peradorcas concinna*. The cysts were up to 410  $\mu\text{m}$  in length and 40  $\mu\text{m}$  in width with relatively small zoites and no detectable trabeculae. Two types of cyst wall were distinguished by light microscopy. Cysts in the tongue had walls 2-4  $\mu\text{m}$  wide with striations. Cysts in limb muscles had walls 1-2  $\mu\text{m}$  wide within which could be discerned protrusions or villi 1-2  $\mu\text{m} \times 1 \mu\text{m}$ .

Fewer sarcocysts were found in 3 of 4 brush-tailed rock wallabies *Petrogale venustula* but they were very similar to those seen in *P. concinna* (Fig. 1). The

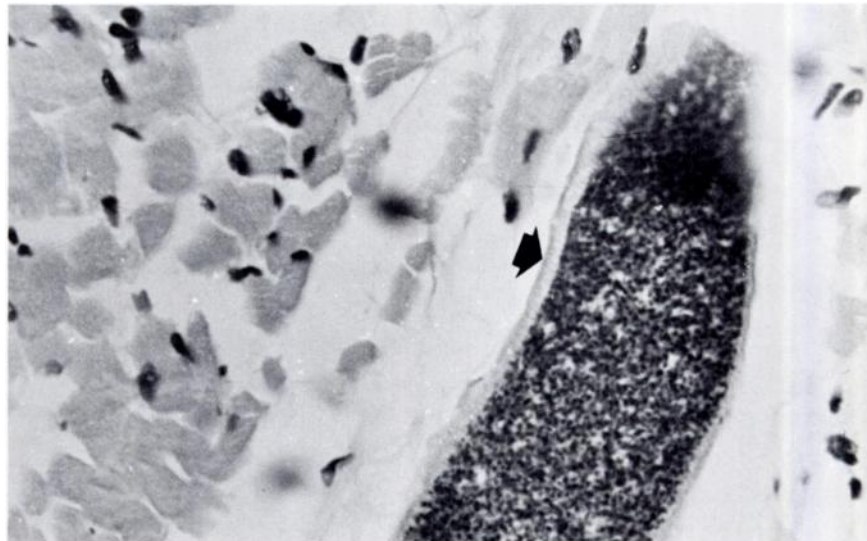


FIGURE 1. Sarcocyst in skeletal musculature of *Petrogale venustula*. Note thick wall (arrowed). H & E  $\times 1500$

longest cyst measured was 140  $\mu\text{m}$  and the widest was 75  $\mu\text{m}$ . In one instance cysts were found in the heart.

One red kangaroo, *Macropus rufus*, had long (up to 2.5 mm) sarcocysts in skeletal muscles, but not in the heart. These cysts were up to 175  $\mu\text{m}$  in width, had a thin wall, and were compartmentalized. Zoites were relatively small. Other kangaroos in the same area had a steatitis associated with schizonts in the fat cells (Fig. 2). Some organisms were round to oval and others were triangular due to compression by fat globules. The schizonts were up to 90  $\mu\text{m}$  in length and 45  $\mu\text{m}$  in width and contained zoites measuring 7  $\mu\text{m} \times 1.2 \mu\text{m}$ . Possibly these were *Sarcocystis* schizonts because O'Donoghue (pers. comm.) has found schizonts of *S. ovicanis* in adipose tissue of lambs.

Numerous thick-walled (up to 5  $\mu\text{m}$ ) sarcocysts were found in the only green ringtail, *Pseudocheirus archeri*, examined (Figs. 3 & 4). Close examination of the cyst wall revealed that it was probably composed of finger-like villi 4-5

$\mu\text{m}$  long by 1  $\mu\text{m}$  wide. The longest cyst found was 1.2 mm long and 145  $\mu\text{m}$  wide.

#### Whales

Tongue was the only tissue examined from the sperm whale, *Physeter catodon*, but sarcocysts were numerous. These had a maximum diameter of 100  $\mu\text{m}$  and the longest cyst measured was 2.5 mm. The wall was smooth and thin and surrounded tightly packed zoites (Fig. 5). The interiors of the cysts were subdivided by fine trabeculae and in larger cysts with a central cavity, this produced a honeycombed appearance. The cysts had a primary, but not a secondary, cyst wall which was up to 60 nm thick. It was very extensively folded to form very many short (0.15  $\mu\text{m}$ ), narrow protrusions.

#### Rabbits

Although the greatest prevalence of type A cysts detected was in rabbits, *Oryctolagus cuniculus*, (23 of 109, 21.1%; Table 1) only a few sarcocysts were found in infected animals. These were mainly in the diaphragm and tongue, never in the heart. None was macroscopically

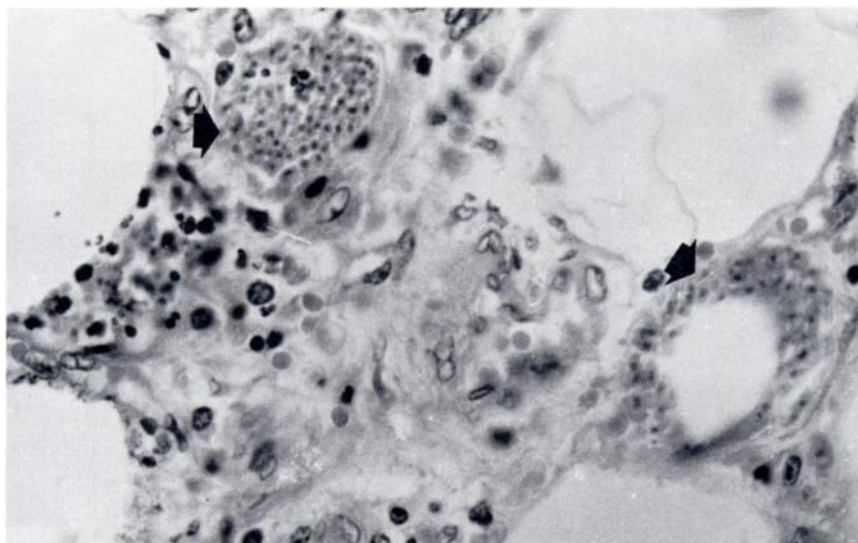


FIGURE 2. Protozoan steatitis in *Macropus rufus*. Schizonts arrowed. H & E  $\times 1500$



visible. The cysts had thick (5-10  $\mu\text{m}$ ), striated walls and were up to 90  $\mu\text{m}$  in diameter (Fig. 6). Their length could not be ascertained as none was cut longitudinally. Relatively large zoites were contained in compartments, but

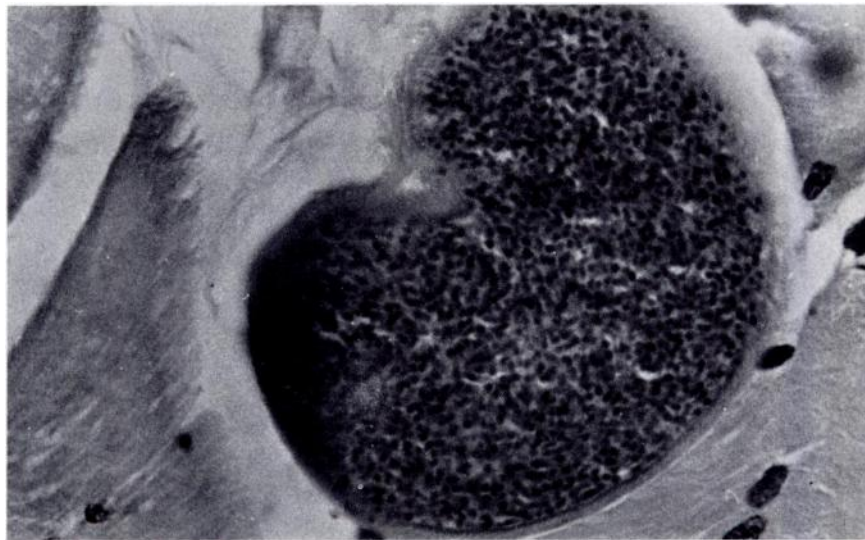


FIGURE 3. Sarcocyst in skeletal musculature of *Pseudocheirus archeri*. H & E  $\times$  1500

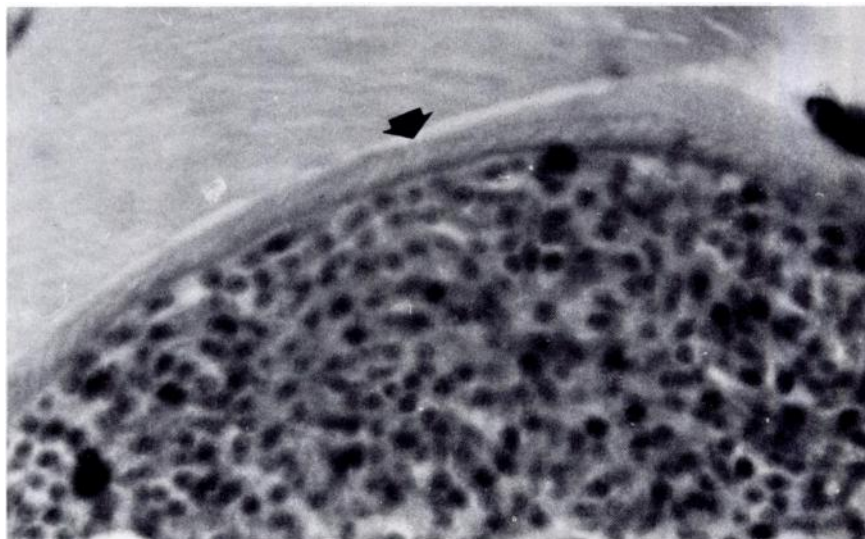


FIGURE 4. Striated wall (arrowed) of sarcocyst in *P. archeri*. H & E  $\times$  3750

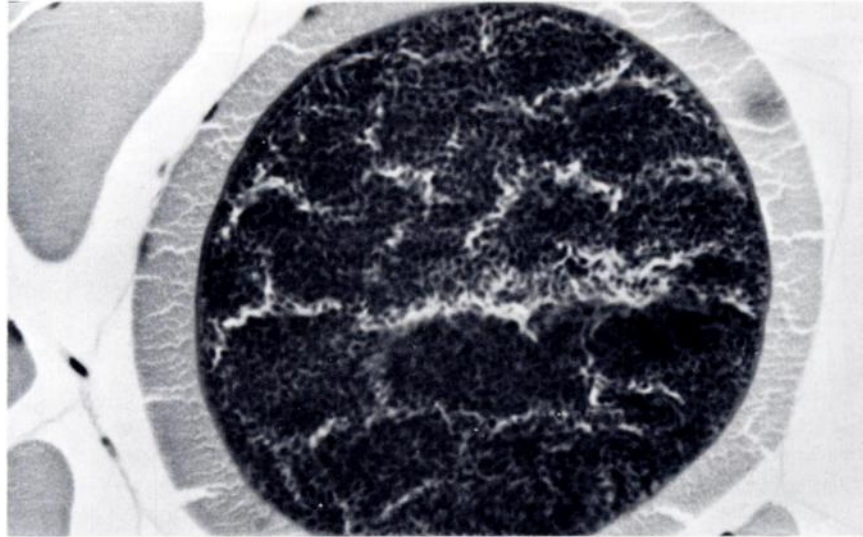


FIGURE 5. Sarcocyst in tongue of *Physeter catadon*. H & E  $\times$  1500

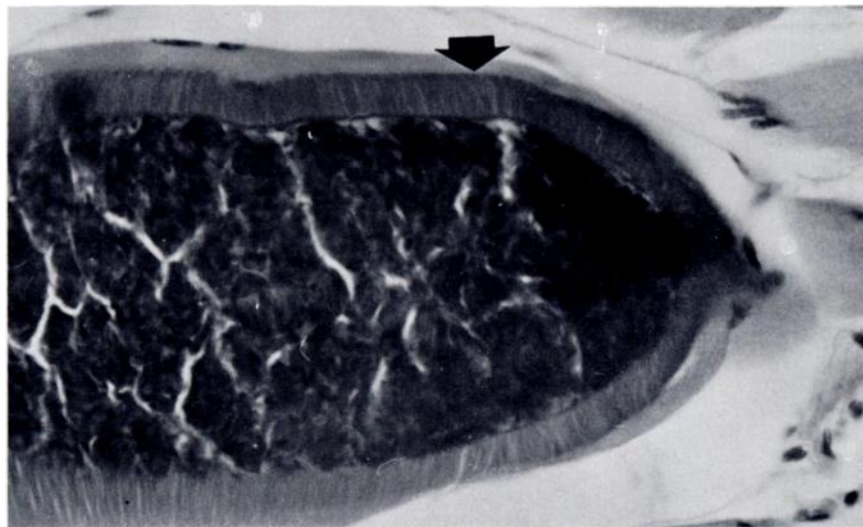


FIGURE 6. Sarcocyst in diaphragm of *Oryctolagus cuniculus*. Note thick, striated wall (arrowed). H & E  $\times$  1500

trabeculae were not detected by light microscopy. With the aid of electron microscopy the cyst wall was seen to

consist of long, closely packed, slender protrusions. Each protrusion had a central core of about 100 closely packed

trabeculae were not detected by light microscopy. With the aid of electron microscopy the cyst wall was seen to consist of long, closely packed, slender protrusions. Each protrusion had a central core of about 100 closely packed microfilaments which continued into the ground substance of the cyst wall proper.

### Rodents

Macroscopic sarcocysts were found in 13 of 48 southern bush-rats, *R. fuscipes*, collected in Victoria and none of 2 collected in New South Wales. The cysts in *R. fuscipes* were up to 2 mm in length and 70  $\mu\text{m}$  in width and had a thick (5-10  $\mu\text{m}$ ), striated cyst wall. The zoites measured  $2 \times 7 \mu\text{m}$ , and were contained within compartments by fine trabeculae.

Native rats, *R. lutreolus*, *Pseudomys higginsi*, *Mastacomys fuscus*, and introduced rats (*R. rattus* and *R. norvegicus*) in Tasmania all appeared to be infected by the same type of sarcocyst which was found in all muscles examined except the heart. Macroscopic sarcocysts were not detected in any of the infected animals. The microscopic cysts had thick (4-8  $\mu\text{m}$ ), striated walls sur-

rounding masses of relatively small zoites (Fig. 7) or, occasionally, groups of metrocytes. In some sections, fine trabeculae could be discerned subdividing the interior of the cyst. The greatest diameter measured was 75  $\mu\text{m}$  and the greatest length 200  $\mu\text{m}$ . Ultrastructurally, there was only a primary cyst wall folded into long and very wide protrusions up to 6  $\mu\text{m}$  in length and 4  $\mu\text{m}$  wide (Fig. 8). In addition, one ship rat, *R. rattus*, and 3 Norway rats, *R. norvegicus*, had thin-walled cysts containing large zoites. These varied in size from  $27 \times 54 \mu\text{m}$  to  $160 \times 576 \mu\text{m}$ , and some showed fine trabeculation. Metrocytes were present in some of the smaller cysts.

Thin-walled cysts containing large zoites were found in the skeletal muscles of one house mouse, *Mus musculus*. These cysts ranged from 40 to 60  $\mu\text{m}$  in diameter and did not have visible trabeculae.

### II. Type B cysts

Thin-walled cysts containing small zoites were found in 14 marsupial, 1 cetacean and 5 rodent species (Table 1).

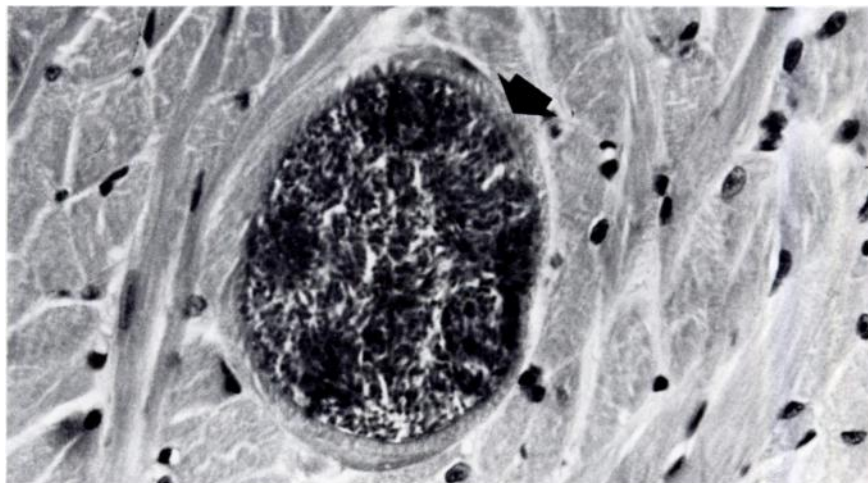


FIGURE 7. Sarcocyst in skeletal musculature of *Rattus lutreolus*. Note thick, striated wall (arrowed). H & E  $\times 1500$

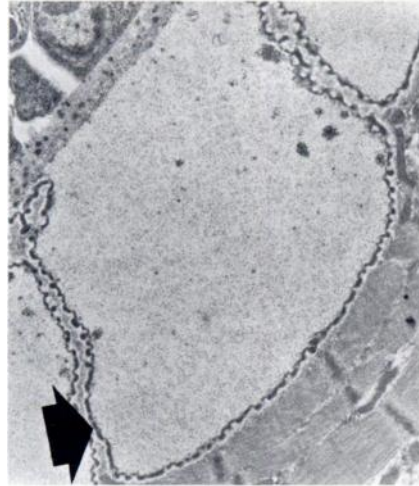


FIGURE 8. Electronmicrograph showing broad villi of cyst wall (arrowed) of sarcocyst in *R. lutreolus*.  $\times 13,500$

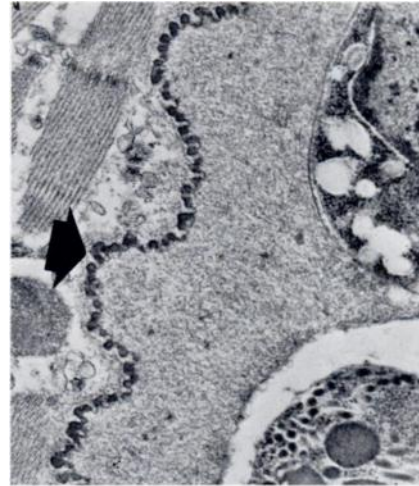


FIGURE 9. Electronmicrograph showing simple wall (arrowed) of sarcocyst in *Antechinus stuartii*.  $\times 30,000$

#### Marsupials $\square$

Prevalence of thin-walled cysts with small zoites was low in each of the four marsupial families affected. The prevalence in dasyurids was 4.2%, in peramelids 8.6%, in phalangerids 1.5% and in macropods 7.2% (Table 1).

The cysts in the muscles of the *Antechinus* spp. measured up to 800  $\mu\text{m}$  in length by 45  $\mu\text{m}$  in width and had thin walls. Ultramicroscopic examination revealed that the wall was simple with undulations and many invaginations (Fig. 9).

Only 1 Tasmanian devil of the many examined had protozoan cysts. The cysts measured up to 2 mm in length and 52  $\mu\text{m}$  in width and were present in skeletal muscles and diaphragm, but not the heart.

The cysts in the brindled bandicoot, *Isodon macrourus*, had thin, but

definite walls and well-defined zoites (Fig. 10). The longest cyst found was 220  $\mu\text{m}$  long and 50  $\mu\text{m}$  wide. In contrast, the cysts in the *Perameles* spp. had ill-defined walls and zoites and were mainly round to ovoid in cross-section (Fig. 11). On the basis of morphology these latter organisms were tentatively identified as *Toxoplasma* which was supported in one instance by the fact that cysts were present in adrenal gland as well as muscle.

The only cyst detected in a brush-tailed possum *Trichosurus vulpecula* was found in the extrinsic muscles of the eye. The cyst was distorted due to muscular contraction and measured 330  $\mu\text{m} \times 180 \mu\text{m}$ . Cysts were relatively numerous in the tongues of mountain possums, *T. caninus*, (Fig. 12) and measured up to 220  $\mu\text{m}$  in length and 72  $\mu\text{m}$  in width.

The thin-walled cysts present in the muscles of macropods, *Thylogale billar-*

$\square$  After this article had gone to press, five of 11 *A. swainsonii* collected in Victoria had sarcocysts in skeletal muscle. As well as thin-walled cysts there were some organisms with walls consisting of closely-packed villi 2-3  $\mu\text{m}$  long. This is another instance of thick-walled sarcocysts being found in mainland marsupials, but not in Tasmania.

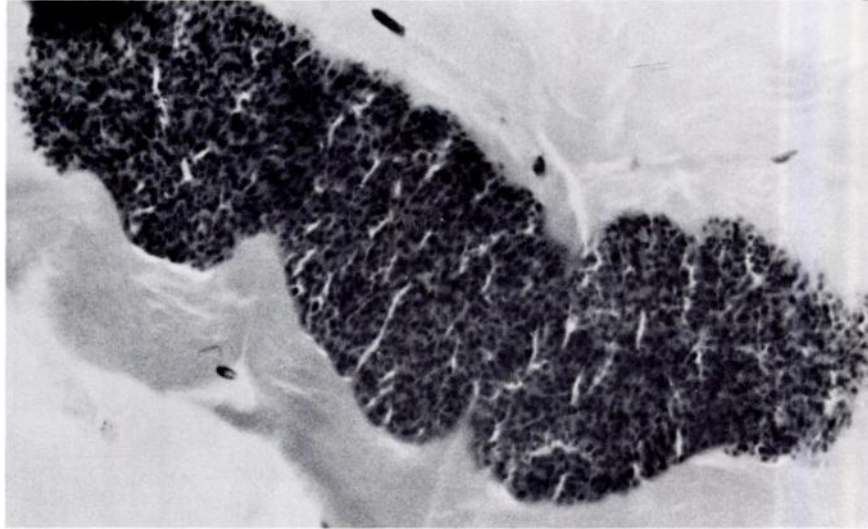


FIGURE 10. Thin-walled sarcocyst in skeletal musculature of *Isodon macrourus*. H & E  $\times$  1500

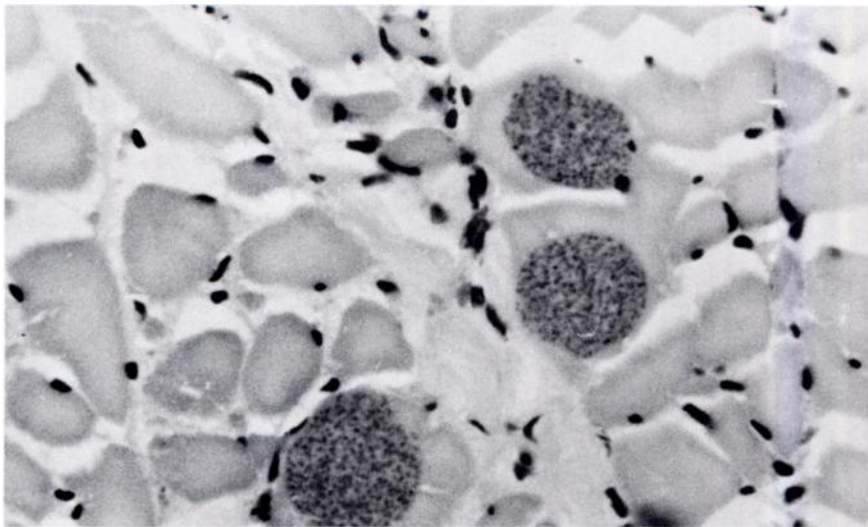


FIGURE 11. Presumed *Toxoplasma* in musculature of *Perameles nasuta*. H & E  $\times$  1500

*dierii*, *Macropus agilis*, *M. rufogriseus*,  
*M. giganteus*, *M. rufus* and *Wallabia*  
*bicolor* were located in various skeletal

muscles, tongue and diaphragm, but not  
heart. These muscle cysts had thin walls,  
relatively small zoites and no detectable

trabeculae (Fig. 13). There was considerable variation in size with the longest cyst measuring 500  $\mu\text{m}$  and having a width of 200  $\mu\text{m}$ . No cysts were detected in macropods collected from islands where dasyurid marsupials were unknown.

#### Dolphins

A single thin-walled cyst, 750  $\mu\text{m}$  long and 80  $\mu\text{m}$  wide was found in 1 of 3 dolphins, *Delphinus* sp., examined.

#### Rodents

Muscle cysts with thin walls and small zoites were found in skeletal and/or cardiac muscle of 1 water rat, *Hydromys chryogaster*, 2 *R. fuscipes*, 2 *R. lutreolus* and 3 *R. rattus* (Table 1, Fig. 14). The longest cyst measured was 900  $\mu\text{m}$  and cyst diameters varied between 18 and 70  $\mu\text{m}$ .

Long cysts (up to 750  $\mu\text{m}$ ) were found in the skeletal muscles of a house mouse.

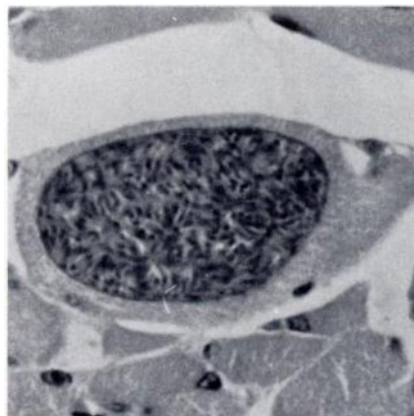


FIGURE 13. Thin-walled sarcocyst in musculature of *Macropus rufogriseus*. H & E  $\times$  1500

These cysts ranged in diameter from 35 to 60  $\mu\text{m}$  and the zoites were relatively small.

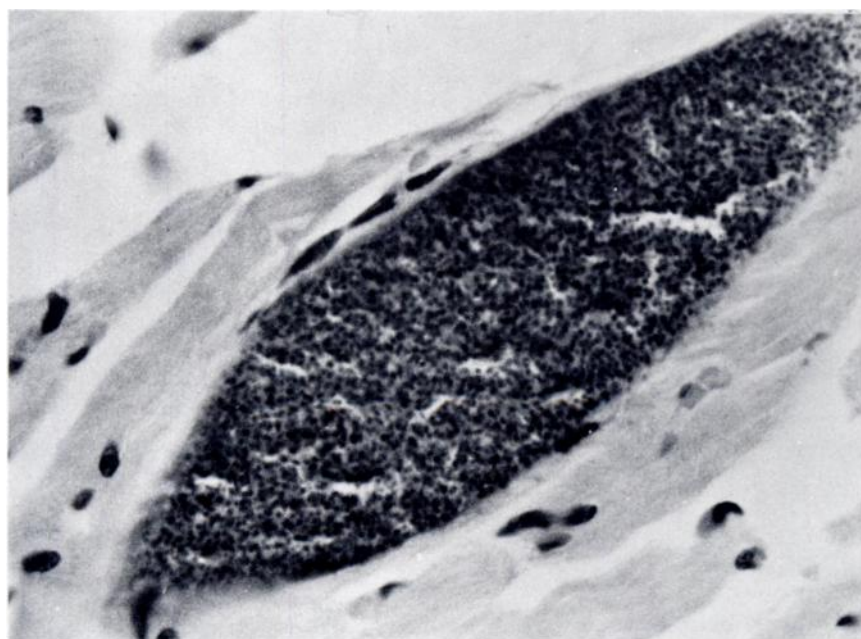


FIGURE 12. Thin-walled sarcocyst in tongue of *Trichosurus caninus*. H & E  $\times$  1500

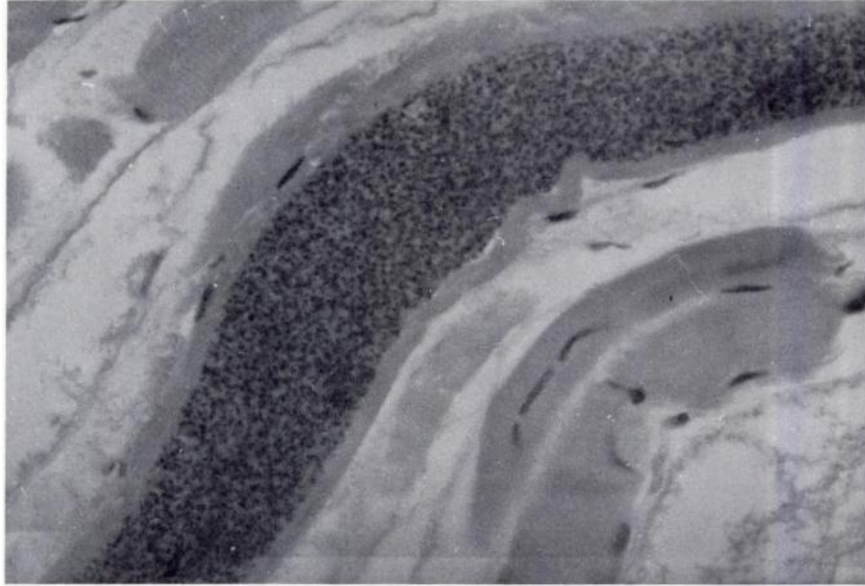


FIGURE 14. Thin-walled sarcocyst in musculature of *R. lutreolus*. H & E  $\times 1500$

#### Examination for oocysts or sporocysts

Only 1 Tasmanian devil and 1 tiger cat of 92 carnivorous marsupials examined had sporocysts in intestinal mucosal scrapings. The sporocysts from the Tasmanian devil measured  $7.2 \times 10 \mu\text{m}$  and occurred in pairs within a fine oocyst membrane (Fig. 15). Those from the tiger cat were similar, but larger ( $8 \times 11.5 \mu\text{m}$ ). Also, it was not possible to definitely demonstrate that the tiger cat sporocysts originated in the intestinal mucosa and therefore they could have been pseudoparasites derived from a prey species. Very small numbers of sporocysts,  $13\text{-}14 \times 8.5 \mu\text{m}$ , typical of *Sarcocystis* or *Frenkelia* were found in the feces of 1 of 55 feral cats examined.

#### DISCUSSION

Results of this survey greatly extend the range of mammals and number of species which harbor *Sarcocystis* or related organisms. To the list of hosts

known, we now add 3 new dasyurid, 3 peramelid, 2 phalangerid, 1 petaurid and 6 macropodid marsupials. The report of *Sarcocystis* in a sperm whale was confirmed and cysts also were found in a dolphin. *Sarcocystis* was rather common

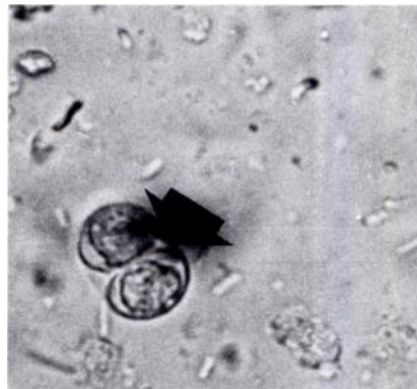


FIGURE 15. Oocyst containing sporocysts (arrowed) in an intestinal scraping from *Sarcophilus harrisii*.  $\times 3750$

in the rabbit, an introduced species. To the eight rodent species listed by Kalyakin and Zasukhin<sup>9</sup> and Glazebrook *et al.*,<sup>8</sup> 3 native rats *H. chrysogaster*, *P. higginsi* and *M. fuscus*, and the introduced mouse, *M. musculus*, are added.

Sarcocysts with thin walls and small zoites (type B cysts) were found in most infected marsupials with the exception of 1 petaurid and 2 macropodid species. The fact that type A cysts were found only in macropods on the mainland of Australia and not in Tasmania suggests that the definitive host(s) also may be geographically restricted. The obvious possibility is the dingo, which does not occur in Tasmania. Not very much can be said about thin-walled sarcocysts in marsupials until such time as their life cycles have been elucidated. However, it is possible that the definitive host could be a carnivorous marsupial because sporocysts typical of *Sarcocystis* were found in the feces of a Tasmanian devil. This hypothesis is supported by the fact that the American opossum, *Didelphis virginiana*, can act as a definitive host for *Sarcocystis*,<sup>2</sup> and also by the observation that all 50 Bennett's wallabies (*M. rufogriseus*) in this series which were collected on islands without carnivorous marsupials did not have detectable sarcocysts (i.e. 0/50 infected c.f. 14/55 for the remainder of this series).

As Pope *et al.*<sup>18</sup> have demonstrated that intramuscular *Toxoplasma* often can be found in infected bandicoots (*I. obesulus* and *P. nasuta*), our tentative diagnosis of the round to ovoid cysts in *P. gunnii* and *P. nasuta* as *T. gondii* probably is justified.

The sarcocysts in the sperm whale are apparently identical with those found in at least one species of baleen whale,<sup>12</sup> *Balaenoptera borealis* suggesting that this parasite may have a wide spectrum of cetacean intermediate hosts. The logical definitive host is the killer whale (*Orcinus orca*) which feeds particularly on the tongue, a heavily infected organ, of the great whales.<sup>11</sup> However, while it is

easy to envisage sieve-feeders (baleen whales) ingesting fecal sporocysts suspended in the sea, it is difficult to explain how squid-feeders (sperm whales) acquire their infections unless squid act as transport hosts.

As no macroscopic sarcocysts were detected in rabbits, and the diameters of the microscopic sarcocysts were less than those of *S. leporum*<sup>5</sup> we believe that the parasite in Australian rabbits is not *S. leporum*. As with other species, such as the sheep,<sup>13</sup> the rabbit may harbor macroscopic and microscopic sarcocysts with different definitive hosts. Although the evidence is as yet tenuous, it could be that the macroscopic sarcocyst, *S. leporum*, has the raccoon as definitive host<sup>6</sup> and, as shown by Fayer and Kradel,<sup>7</sup> Munday *et al.*<sup>16</sup> and Collins (pers. comm.) the microscopic sarcocyst has the domestic cat as definitive host.

The macroscopic *Sarcocystis* in *R. fuscipes* from southern Victoria was very similar to Rzepczyk's type A organism from Queensland<sup>20</sup> rats and *S. orientalis* described in Malaysia<sup>22</sup> (renamed *S. singaporensis*<sup>23</sup>), both of which have pythons as definitive hosts. However, pythons do not occur in southern Victoria and therefore another definitive host may be involved in this region. Also, the thick-walled *Sarcocystis* detected in native rats, *M. fuscus*, *P. higginsi* and *R. lutreolus*, and the introduced rats, *R. rattus* and *R. norvegicus* in Tasmania probably is a distinct species, because it has black tiger snakes (*Notechis ater*) as definitive hosts<sup>16</sup> and has a somewhat different cyst wall when examined under the electron microscope. Indeed, Rzepczyk and Scholtyseck,<sup>20</sup> and Zaman and Colley<sup>22</sup> described their species of *Sarcocystis* as having walls composed of thin villi (6.8 - 8.7  $\mu\text{m} \times 0.8 - 1.4 \mu\text{m}$  and 4  $\mu\text{m} \times 1 \mu\text{m}$  respectively) with a basal neck, whereas the organism in Tasmanian rats had broad villi (approx. 6  $\mu\text{m} \times 4 \mu\text{m}$ ) with no neck.<sup>12</sup> It would seem that a degree of divergence has developed between the parasite in rats in tropical



areas and that found in southern rodents, tempting us to suggest that this could be due to geographic isolation.

We have been unable to relate the thin-walled sarcocyst with large zoites from *R. rattus* to any previously described *Sarcocystis*.

Rzecznyk's type B<sup>20</sup> and Lai's type III<sup>10</sup> *Sarcocystis* bear some similarity to the sarcocysts with thin walls and small zoites which were seen in wild *H. chrysogaster* and *R. lutreolus*, and domiciliated *R. rattus* and *R. norvegicus*. Obviously, more work is required to properly classify these organisms and ascertain their relationship to one another.

Experimental infection studies with these various rat species and sporocysts from owls and snakes have been conducted in attempts to elucidate these cycles. Results of these experiments will

be presented in a separate communication.<sup>16</sup>

The low level of detectable *Sarcocystis* infection in mice was somewhat unexpected as they are preyed upon by many predators. The thin-walled cysts containing large zoites resembled Wallace's<sup>21</sup> type B cyst, a cycle in which cats are the definitive host. The long, thin-walled cyst containing small zoites was almost certainly *S. dispersa*<sup>4</sup> which has larger owls, especially barn owls (*Tyto alba*), as definitive hosts.<sup>3,14</sup>

These observations emphasize the need to elucidate the life cycles of *Sarcocystis* spp. in Australian wildlife because only then will their taxonomy be meaningful. In addition, life cycle studies will help determine the disease potential of these *Sarcocystis* spp. since most of the pathogenicity is associated with the schizogonic stages of these parasites.<sup>3,14,16,19</sup>

#### Acknowledgements

Unfortunately it is not possible to acknowledge every person who has provided specimens or given technical assistance. Special thanks are due to officers of the Tasmanian Department of Agriculture and National Parks and Wildlife Service, Mr. R.H. Green, Queen Victoria Museum, Launceston, Tasmania, Mrs. J. Wright, Sidmouth, Tasmania and Dr. J. Nelson, Monash University, Melbourne, Victoria.

#### LITERATURE CITED

1. BEARUP, A.J. 1954. The coccidia of carnivores in Sydney. *Aust. vet. J.* 30: 185-186.
2. BOX, E.D. and D.W. DUSZYNSKI. 1977. Survey for *Sarcocystis* in the brown-headed cowbird (*Molothrus ater*): A comparison of macroscopic, microscopic & digestion techniques. *J. Wildl. Dis.* 13: 356-359.
3. CERNA, Z. 1976. Relationship of oocysts of "*Isospora buteonis*" from the barn-owl (*Tyto alba*) to muscle cysts of sarcosporidians from the house mouse (*Mus musculus*). *Folia Parasit. (Praha)* 23: 285.
4. ——— and J. SÉNAUD. 1977. Sur un type nouveau de multiplication asexuée d'une Sarcosporidie dans le foie de la souris. *C.R. Acad. Sc. Paris.* 285: 347-349.
5. CRAWLEY, H. 1914. Two new Sarcosporidia. *Proc. Acad. Nat. Sci. Philadelphia.* 66: 214-218. Quoted by Mandour, A.M. 1965. *Sarcocystis garnhami* n.sp. in the skeletal muscle of an opossum, *Didelphis marsupialis*. *J. Protozool.* 12: 606-609.

6. CRUM, J.M. and A.K. PRESTWOOD. 1977. Transmission of *Sarcocystis leporum* from a cottontail rabbit to domestic cats. *J. Wildl. Dis.* 13: 174-175.
7. FAYER, R. and D. KRADEL. 1976. *Sarcocystis leporum* in cottontail rabbits and its transmission to carnivores. *J. Wildl. Dis.* 13: 170-173.
8. GLAZEBROOK, J.S., R.S.F. CAMPBELL and G.W. HUTCHINSON. 1977. The pathology of feral rodents in north Queensland: II Studies on zoonotic infections. *Tropenmed. Parasit.* 28: 545-551.
9. KALYAKIN, V.N. and D.N. ZASUKHIN. 1975. Distribution of *Sarcocystis* (Protozoa: Sporozoa) in vertebrates. *Folia Parasit. (Praha)* 22: 289-307.
10. LAI, P.F. 1977. *Sarcocystis* in Malaysian field rats. *Southeast Asian J. Trop. Med. Pub. Hlth.* 8: 417-418.
11. MARTIN, R.M. 1977. Dolphins and Whales. In: *Mammals of the Oceans*. R.M. Martin, Ed. Hutchinson Group, Melbourne, Australia pp. 44-82.
12. MELHORN, H., W.J. HARTLEY and A.O. HEYDORN. 1976. A comparative ultrastructural study of the cyst wall of 13 *Sarcocystis* species. *Protostologica XII*: 451-467.
13. MUNDAY, B.L. and M.D. RICKARD. 1974. Is *Sarcocystis tenella* two species? *Aust. vet. J.* 50: 558-559.
14. ———. 1977. A species of *Sarcocystis* using owls as definitive hosts. *J. Wildl. Dis.* 13: 205-207.
15. ———, W.J. HARTLEY, K.E. HARRIGAN, P.J.A. PRESIDENTE and D. OBENDORF, 1979. *Sarcocystis* and related organisms in Australian wildlife: II Survey findings in birds and reptiles. *J. Wildl. Dis.* (in press).
16. ———, R.W. MASON and D. OBENDORF. 1979. *Sarcocystis* and related organisms in Australian wildlife: III Life cycle studies. *J. Wildl. Dis.* (in press).
17. OWEN, C.G. and B.A. KAKULAS. 1968. Sarcosporidiosis in the sperm whale. *Aust. J. Sci.* 31: 46-47.
18. POPE, J.H., V.A. BICKS and I. COOK. 1957. *Toxoplasma* in Queensland: II Natural infections in bandicoots and rats. *Aust. J. exp. Biol.* 35: 481-490.
19. RZEPczyk, C.M. 1974. Evidence of a rat-snake cycle for *Sarcocystis* *Int. J. Parasit.* 4: 447-449.
20. ——— and E. SCHOLTYSECK. 1976. Light and electron microscope studies on the *Sarcocystis* of *Rattus fuscipes*, an Australian rat. *Z. Parasitenk.* 50: 137-150.
21. WALLACE, B.D. 1975. Observations on a feline coccidium with some characteristics of *Toxoplasma* and *Sarcocystis*. *Z. Parasitenk.* 46: 167-178.
22. ZAMAN, V. and F.C. COLLEY. 1975. Light and electron microscopic observations on the life cycle of *Sarcocystis orientalis* sp.n. in the rat (*Rattus norvegicus*) and the Malaysian reticulated python (*Python reticulatus*). *Z. Parasitenk.* 47: 169-185.
23. ——— and ———. 1976. Replacement of *Sarcocystis orientalis* Zaman and Colley, by *Sarcocystis singaporensis* sp.n. *Z. Parasitenk.* 51: 137.

*Received for publication 17 April 1978*