



## **PARATUBERCULOSIS (JOHNE'S DISEASE) IN BIGHORN SHEEP AND A ROCKY MOUNTAIN GOAT IN COLORADO**

Authors: WILLIAMS, ELIZABETH S., SPRAKER, TERRY R., and SCHOONVELD, GENEG.

Source: Journal of Wildlife Diseases, 15(2) : 221-227

Published By: Wildlife Disease Association

URL: <https://doi.org/10.7589/0090-3558-15.2.221>

---

BioOne Complete ([complete.BioOne.org](https://complete.BioOne.org)) is a full-text database of 200 subscribed and open-access titles in the biological, ecological, and environmental sciences published by nonprofit societies, associations, museums, institutions, and presses.

Your use of this PDF, the BioOne Complete website, and all posted and associated content indicates your acceptance of BioOne's Terms of Use, available at [www.bioone.org/terms-of-use](http://www.bioone.org/terms-of-use).

Usage of BioOne Complete content is strictly limited to personal, educational, and non - commercial use. Commercial inquiries or rights and permissions requests should be directed to the individual publisher as copyright holder.

---

BioOne sees sustainable scholarly publishing as an inherently collaborative enterprise connecting authors, nonprofit publishers, academic institutions, research libraries, and research funders in the common goal of maximizing access to critical research.

## PARATUBERCULOSIS (JOHNE'S DISEASE) IN BIGHORN SHEEP AND A ROCKY MOUNTAIN GOAT IN COLORADO

ELIZABETH S. WILLIAMS and TERRY R. SPRAKER, Wild Animal Disease Center, Colorado State University, Fort Collins, Colorado 80523, USA.

GENE G. SCHOONVELD, Colorado Division of Wildlife, 317 W. Prospect St., Fort Collins, Colorado 80521, USA.

**Abstract:** Between May, 1972 and February, 1978, six cases of paratuberculosis (Johne's Disease) caused by *Mycobacterium paratuberculosis* were diagnosed in free-ranging Rocky Mountain bighorn sheep (*Ovis canadensis*) and one Rocky Mountain goat (*Oreamnos americanus*) on or near Mt. Evans in Colorado. Diagnosis of paratuberculosis was based on gross and histopathologic examination of the animals and by isolation of *M. paratuberculosis* from three sheep and the goat. The clinical signs and pathologic changes seen in the bighorn sheep resembled those described in cattle, while the lesions in the goat were similar to those described for domestic sheep and goats.

### INTRODUCTION

Paratuberculosis is a specific infectious enteritis of domestic livestock including cattle, sheep, goats, camel (*Camelus bactrianus*) and reindeer (*Rangifer tarandus*). This disease is important to the cattle industry in eastern, midwestern and northwestern areas of the United States,<sup>8</sup> Canada and eastern and central Europe.<sup>3</sup> The disease has been studied extensively in domestic species (cattle, sheep, and goats). *Mycobacterium paratuberculosis*, a small ( $0.5 \times 1.2 \mu\text{m}$ ) acid-fast bacillus, causes chronic disease of the intestinal tract, particularly the distal small intestine, ileocecal valve, cecum, associated mesenteric lymph nodes and afferent lymphatics. Characteristics of the disease in domestic ruminants include a gradual loss of weight to a state of emaciation, intermittent to constant diarrhea in the later stages of the disease in cattle, an incubation period which may last several years, during which time organisms may be shed in the feces, and an annual herd mortality rate of up to 10%.<sup>9</sup> Clinical signs usually are seen only in adult animals greater than two years of age.

Descriptions of paratuberculosis in wild species are incomplete and consist mainly of isolated case reports. The disease has been reported in wild free-ranging species, but is more frequently reported in captive wild species, including white-tailed deer (*Odocoileus virginianus*),<sup>11</sup> roe deer (*Capreolus capreolus*),<sup>4</sup> European red deer (*Cervus elaphus*),<sup>16,6</sup> moose (*Alces alces*),<sup>14</sup> aoudad (*Ammotragus lernia*),<sup>2</sup> mouflon (*Ovis musemon*),<sup>2,6</sup> camel (*Camelus bactrianus*),<sup>15,6</sup> bighorn sheep (*Ovis canadensis*),<sup>15</sup> reindeer (*Rangifer tarandus*),<sup>6</sup> Japanese sika deer (*Pseudaxis sika*),<sup>6</sup> water buffalo (*Bubalus bubalus*),<sup>6</sup> yak (*Bos grunniens*),<sup>6</sup> gnu (*Connochaetes albojubatus*)<sup>6</sup> and llama (*Llama glama*).<sup>1</sup> This report documents six cases of paratuberculosis in a herd of free-ranging Rocky Mountain bighorn sheep and one Rocky Mountain goat (*Oreamnos americanus*) on or near Mt. Evans in Colorado.

### MATERIALS AND METHODS

The animals examined originated either from the Mt. Evans or Grant,

Colorado, bighorn sheep herds. The goat was from the Lincoln Lake goat herd on Mt. Evans. These areas are 22 km apart and movement of sheep from Mt. Evans to Grant has been documented by observation of marked individuals. The Mt. Evans and Grant herds have been estimated at 150 and 80 sheep, respectively, by one of us (G.G.S.).

Cases were presented to the Wild Animal Disease Center (WADC), Colorado State University, by personnel of the Colorado Division of Wildlife. Some animals were presented alive and subsequently euthanized, others were shot or found dead in the field. A thorough post mortem examination was performed and representative tissues fixed in 10% formalin; mesenteric lymph nodes and sections of small intestine were frozen at -70 C for later bacterial culture. Formalin-fixed tissues were processed routinely and stained with hematoxylin and eosin (H&E). Appropriate tissues also were stained by the Kinyon acid fast method.<sup>12</sup> Bacteriology on tissues of bighorn sheep #3, 4, 6 and the mountain goat was performed by Dr. Charles Thoen, Mycobacteriology Section, National Animal Disease Center, Ames, Iowa. Cultures of goat tissues also were performed by the Colorado State Diagnostic Laboratory, Fort Collins, Colorado.

Smears were made of feces from the mountain goat and stained by Truant's auramine rhodamine method for mycobacteria.<sup>10</sup> These slides were ex-

amined under ultraviolet light and bacteria identified by fluorescence.

## CASE REPORTS

### Rocky Mountain bighorn sheep: Clinical cases

The following description of paratuberculosis is based on five clinical cases (Table 1). All of the animals were emaciated and had a rough hair coat. Dried feces were seen on the perineum, hocks and lower rear legs. Marked submandibular edema was present in cases 4 and 6. Gross lesions consisted of marked subserosal edema of the jejunum and ileum. The afferent lymphatics from this area were thickened, opaque and tortuous. Mesenteric lymph nodes of the small intestine were greatly enlarged and edematous. The walls of the jejunum, ileum and cecum were thickened and the mucosa slightly corrugated. On histopathologic examination the walls of the jejunum, ileum, cecum and, in three cases, the spiral colon were thickened by numerous pale eosinophilic, foamy, epithelioid macrophages diffusely distributed throughout the lamina propria and submucosa. Multinucleated giant cells were present in intestinal sections of cases 2 and 3. Villous architecture was destroyed by the cellular infiltrate. Necrosis, caseation or mineralization were not seen. The walls of the lymphatics were thickened by epithelioid macrophages and perilymphatic lymphocytic infiltration. On occasion,

TABLE 1. Cases of Paratuberculosis in Bighorn sheep and a Rocky Mountain goat in Colorado.

Species	Date	Age	Sex	Location
1. Bighorn	5-72	4	male	Mt. Evans
2. Bighorn	1-26-77	4	female	Mt. Evans (subclinical)
3. Bighorn	4-18-77	6	male	Grant
4. Bighorn	5-20-77	4	male	Mt. Evans
5. Bighorn	4-30-77	10	male	Grant
6. Bighorn	1-2-78	7½	female	Grant
7. Rocky Mtn. Goat	2-21-78	2½	male	Mt. Evans

the cellular infiltrate was so great as to nearly occlude the lumen of the lymphatic. Edema, moderate numbers of lymphocytes, epithelioid macrophages and, in case 6, multinucleated giant cells, were seen in the subserosa and adjacent mesentery. Mesenteric lymph nodes were edematous and contained clusters of epithelioid macrophages within the cortex (Fig. 1). The cortex of case 6 also contained multinucleated giant cells. Granulomas were most frequently present adjacent to the subcapsular region. In case 6 a focal granuloma containing acid-fast bacilli was present in the tonsil. Acid-fast stains applied to these sections demonstrated clusters of small bacilli within epithelioid macrophages and giant cells. In all but case 1, large numbers of acid fast bacteria were present in the intestinal sections with fewer in the afferent lymphatics and lymph nodes.

*M. paratuberculosis* was cultured from ileum and mesenteric lymph nodes of cases 3, 4 and 6.

#### Rocky Mountain bighorn sheep: Subclinical case

One subclinical case (case 2) of paratuberculosis was presented for examination (Table 1). This 4 year old ewe had been trapped the day prior to death and at that time was noted to be in shock and showing signs of posterior paralysis. On gross examination a fracture, together with extensive spinal cord damage was found at L<sub>5</sub>. No other significant gross lesions were found. Typical microscopic lesions of paratuberculosis were seen in the ileum and associated lymph nodes and were characterized by mild, diffuse infiltration of epithelioid macrophages into the lamina propria and submucosa of the ileum and cortex of the mesenteric lymph nodes. Occasional giant cells were

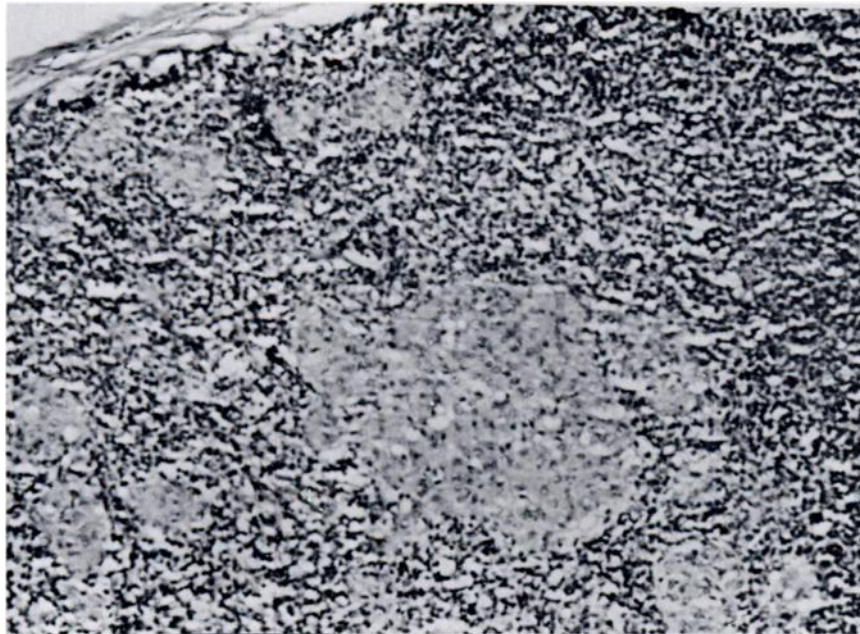


FIGURE 1. Granulomas within the cortex of a mesenteric lymph node of a bighorn sheep. H&E  $\times 100$

seen in the lamina propria. Only a few acid-fast organisms were seen within macrophages of these sections.

#### Rocky Mountain Goat: Clinical Case

An emaciated Rocky Mountain goat, with evidence of diarrhea was sighted on Mt. Evans, was shot and brought to the WADC for necropsy. Dry, dark brown feces were seen on the perineum and the hocks. Submandibular edema was not present. Subserosal edema of the small intestine was minimal. The afferent lymphatics were prominent, but not tortuous. All mesenteric lymph nodes were greatly enlarged. Pale mottling of the lymph nodes was seen through the mesentery. On cut surface the cortex and medulla of the lymph nodes could not be distinguished, and irregular soft yellowish foci were present. The wall of the distal jejunum and ileum was greatly thickened and the mucosal surface

irregular. There was diffuse hyperemia of the intestinal tract, with a fibrinonecrotic membrane in the ileum. This change probably was associated with secondary bacterial infection ( $\alpha$  *Streptococcus*,  $\beta$  *Streptococcus*, and *Escherichia coli* were isolated from the intestine). Fibrous adhesions were present between the ileum and the peritoneal wall. A 3 cm abscess, containing pale yellow debris, was found in the wall of the ileum. On microscopic examination, the entire small intestine and cecum were found to have variable degrees of cellular infiltration of the lamina propria and submucosa. Inflammatory cells included lymphocytes, epithelioid macrophages and multinucleated giant cells. Villous architecture of the majority of the small intestine was disrupted (Fig. 2). In areas of massive cellular infiltrate, necrosis was commonly seen. Focal necrosis associated with bacterial colonies was

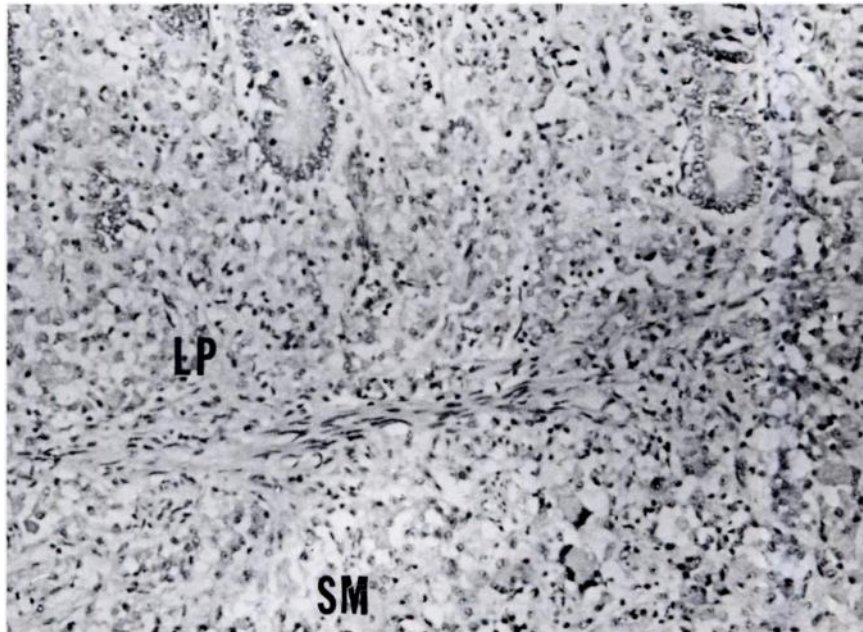


FIGURE 2. Section through the jejunum of a Rocky Mountain goat showing granulomatous infiltrate into the lamina propria (LP) and submucosa (SM). H&E  $\times$  100

seen at the luminal surface in some areas. The afferent lymphatics were variably involved with granulomatous cellular infiltrate. The mesenteric lymph nodes were massively infiltrated with epithelioid macrophages and giant cells. Lymphoid tissue in several nodes had been nearly replaced by granulomatous infiltrate. Necrosis was commonly seen in areas of dense cellularity. Scattered focal granulomas, consisting primarily of epithelioid macrophages, were present in the liver (Fig. 3). Large numbers of small acid-fast bacilli were present within phagocytic cells of the intestinal tract, lymphatics and lymph nodes. Retropharyngeal, bronchial and prescapular lymph nodes contained small numbers of acid-fast bacilli within macrophages at the corticomedullary junction. Acid-fast bacilli also were demonstrated in macrophages associated with lungworm (*Protostrong-*

*ylus stilesi*) granulomas in lung and in focal granulomas in the liver.

Large numbers of fluorescing mycobacteria were demonstrated in the feces using Truant's auramine rhodamine staining technique. Acid fast preparations also showed large numbers of organisms in the feces. *M. paratuberculosis* was cultured from ileum and mesenteric lymph node.

#### DISCUSSION

The clinical and pathologic changes seen in naturally-infected bighorn sheep are similar to those observed in domestic cattle. Microscopically, there was no evidence of caseation or mineralization in the intestinal wall or mesenteric lymph nodes, which is commonly described in domestic sheep.<sup>7,13</sup> Giant cells were seen only rarely in the intestinal mucosa of case 2 and 3, but were

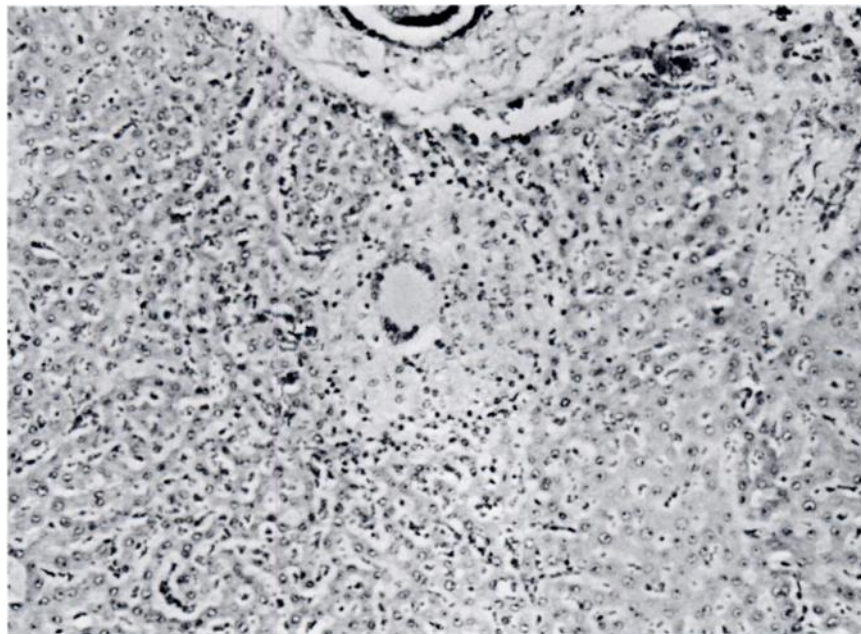


FIGURE 3. Granuloma in the liver of a Rocky Mountain goat consisting of epithelioid macrophages and a giant cell. H&E  $\times 100$

present in greater numbers in the mesentery and perilymphatic region of case 6. Giant cell proliferation in cattle is a common response to *M. paratuberculosis*.<sup>5</sup>

Diagnosis of paratuberculosis in a Rocky Mountain goat represents the first time the disease has been reported in this species. Gross and microscopic lesions were somewhat different than those seen in bighorn sheep, and similar to those described in domestic sheep and goats. While mineralization was not seen, necrosis in areas of dense cellular infiltrate was commonly present. This was the youngest animal recovered to date from the Mt. Evans area and the lesions were more severe and extensive than those observed in bighorn sheep, suggesting a greater susceptibility and severity of paratuberculosis for mountain goats than for bighorn sheep. Quantitative assay of *M. paratuberculosis* in the feces of this goat has not been undertaken as yet; however, because of the extensive intestinal lesions and massive numbers of acid-fast bacteria demonstrated by histology there is little doubt that this animal was passing large numbers of bacteria in the feces. The importance of this to the epizootiology of paratuberculosis on Mt. Evans has not been investigated. There is considerable overlap in the ranges of the mountain goats and bighorn sheep in this area. Four other emaciated goats showing evidence of diarrhea have been seen; unfortunately only this case has been obtained for examination. More cases in the goat are needed to adequately describe the disease.

Of the six cases of paratuberculosis in bighorn sheep from this region, five were clinical and one was subclinical. This also is an important epizootiological factor to consider in paratuberculosis. Domestic animals can be infected with *M. paratuberculosis* and shed organisms in the feces for months prior to developing clinical signs. Duration of the subclinical period, and numbers of bacteria

that may be shed, are not known for bighorn sheep or any other wild species. Studies of the pathogenesis of experimentally induced paratuberculosis in bighorn sheep and mountain goats are needed to clarify the epizootiology of the disease within this herd and are planned for the future.

Several important questions should be considered in regard to the diagnosis of paratuberculosis in free-ranging bighorn sheep and goats in Colorado. First, how did the organisms get established in this herd? Paratuberculosis has not been diagnosed by the Colorado State Veterinary Diagnostic Laboratory in animals from Colorado in more than 20 years; however, the possibility that infected domestic livestock in the area were the source of infection cannot be overlooked. Moreover, mountain goats were transplanted onto Mt. Evans in 1961 and possibly some infected animals were released. The large numbers of bacteria present in the goat feces suggests that goats may be capable of disseminating large numbers of organisms into the environment. As paratuberculosis is a chronic disease with long incubation time, possibly it has taken up to 17 years to become established in these herds.

The second question concerns the importance of a paratuberculosis-infected free-ranging herd of bighorn sheep and mountain goats for other wild free-ranging ruminants. Studies in domestic ruminants indicate the *M. paratuberculosis* from one species readily infects other ruminant species. The importance of this and the likelihood of other wild ruminants as well as domestic stock in the area becoming infected is unknown at this time. Experimental cross-transmission studies into various ruminant species are planned.

Prevalence of the disease in this herd is presently unknown; however, survey work using fecal culture and lymphocyte immunostimulation techniques currently are underway.

**Acknowledgements**

Sincere appreciation is expressed to Mr. Rus Mason, Mr. Bob Davies, Mr. Vic Feuerstein, Dr. Charles Hibler and Dr. Stan Snyder for assistance in this project.

**LITERATURE CITED**

1. APPLEBY, E.C. and K.D. HEAD. 1954. A case of suspected Johne's disease in a llama (*L. glama*) J. Comp. Path. 4: 52-53.
2. BOEVER, W.J. and D. PETERS. 1977. Paratuberculosis in two herds of exotic sheep. J. Am. vet. med. Ass. 170: 987-990.
3. DOYLE, T.M. 1956. Johne's disease. Vet. Rec. 68: 869-878.
4. HELLERMARK, K. 1966. A disease resembling paratuberculosis (Johne's disease) in roe deer (*Capreolus capreolus L*) Acta. Vet. Scand. 7: 330-363.
5. JUBB, K.V.F. and P.C. KENNEDY. 1970. *Pathology of Domestic Animals*. Vol. 2, Academic Press, New York. pp. 697.
6. KATIC, I. 1961. Paratuberculosis (Johne's disease) with special reference to captive wild animals. Nord. Vet. Med. 13: 205-214.
7. KLUGE, J.P., R.S. MERKAL, W.S. MONLUX, A.B. LARSEN, K.E. KOPECKY, F.K. RAMSEY and R.P. LEHMANN. 1968. Experimental paratuberculosis in sheep after oral, intratracheal or intravenous inoculation: lesions and demonstration of etiologic agent. Am. J. Vet. Res. 29: 953-962.
8. KOPECKY, K.E. 1973. Distribution of bovine paratuberculosis in the United States. J. Am. vet. med. Ass. 162: 787-788.
9. LARSEN, A.A. Johne's disease (paratuberculosis). pp. 135-140. In: *Bovine Medicine and Surgery*. 1970. W.J. Gibbons, E.J. Catcott, J.F. Smithcors, Eds. Am. Vet. Pub., Inc., Wheaton, Illinois, pp. 847.
10. LENNETTE, E.H., E.H. SPAULDING, and J.P. TRUANT. (Eds). 1974. *Manual of Clinical Microbiology*. 2nd Ed. American Society for Microbiology. Washington, D.C. pg. 948.
11. LIBKE, K.G. and A.M. WALTON. 1975. Presumptive paratuberculosis in a Virginia white-tailed deer. J. Wildl. Dis. 11: 552-553.
12. LUNA, L.G. (Ed). 1968. *Manual of Histological Staining Methods of the Armed Forces Institute of Pathology*, 3rd Ed. McGraw-Hill Book Co., New York, pg. 218.
13. NISBET, D.F., N.J.L. GILMOUR and J.G. BROTHERSTON. 1962. Quantitative studies of *Mycobacterium johnei* in tissues of sheep. III. intestinal histopathology. J. Comp. Path. 72: 80-91.
14. SOLTYS, M.A., C.E. ANDRESS and A.L. FLETCH. 1967. Johne's disease in a moose (*Alces alces*). Bull. Wildl. Dis. Ass. 3: 183-184.
15. THOEN, C.O., W.D. RICHARDS and J.L. JARNAGIN. 1977. Mycobacteria isolated from exotic animals. J. Am. vet. med. Ass. 170: 987-990.
16. VANCE, M.N. 1961. Johne's disease in a European red deer. Can. Vet. J. 2: 305-307.

Received for publication 8 September 1978