



PATHOMORPHOLOGIC FINDINGS IN SHORT-TAILED VOLES (*Microtus agrestis*) EXPERIMENTALLY- INFECTED WITH *Frenkelia microti*

Authors: GEISEL, O., KAISER, E., VOGEL, O., KRAMPITZ, H.E., and ROMMEL, M.

Source: Journal of Wildlife Diseases, 15(2) : 267-270

Published By: Wildlife Disease Association

URL: <https://doi.org/10.7589/0090-3558-15.2.267>

BioOne Complete (complete.BioOne.org) is a full-text database of 200 subscribed and open-access titles in the biological, ecological, and environmental sciences published by nonprofit societies, associations, museums, institutions, and presses.

Your use of this PDF, the BioOne Complete website, and all posted and associated content indicates your acceptance of BioOne's Terms of Use, available at www.bioone.org/terms-of-use.

Usage of BioOne Complete content is strictly limited to personal, educational, and non - commercial use. Commercial inquiries or rights and permissions requests should be directed to the individual publisher as copyright holder.

BioOne sees sustainable scholarly publishing as an inherently collaborative enterprise connecting authors, nonprofit publishers, academic institutions, research libraries, and research funders in the common goal of maximizing access to critical research.

PATHOMORPHOLOGIC FINDINGS IN SHORT-TAILED VOLES (*Microtus agrestis*) EXPERIMENTALLY-INFECTED WITH *Frenkelia microti*

O. GEISEL,¹ E. KAISER,¹ O. VOGEL,¹ H.E. KRAMPITZ² and M. ROMMEL³

Abstract: Following oral infection of *Microtus agrestis* with sporocysts of *Frenkelia microti*, transient focal necrosis and cellular infiltrations in the liver, hyperplasia of lymphoid organs, and inflammatory infiltrations in the heart, pulmonary veins, skeletal muscles and brain occurred during the first asexual multiplication period of the parasite in the liver. *Frenkelia* cysts were first observed in the brain 23 days after infection.

INTRODUCTION

In previous investigations² the common European buzzard (*Buteo buteo*) was recognized as the final host of *Frenkelia microti*, the lobulated cysts of which develop in the brain of the short-tailed vole (*Microtus agrestis*). Because of this finding systematic investigations into the developmental cycle of *F. microti* in the intermediate host and into its host range became possible.³ Lesions occurring in various organs of short-tailed voles following experimental infections with *F. microti* sporocysts are described in this report.

MATERIALS AND METHODS

Each of 31 voles derived from a laboratory colony was fed 7800 sporocysts isolated from the feces of experimentally-infected buzzards. Six voles were left uninfected as controls. One principal animal was killed per day at daily intervals from day 1 to 12, at two day intervals from day 12 to 20, on day

23, 26, 30 and 35, and at 10 day intervals from day 40 to 100. One additional principal animal was killed on days 4, 5, 6, 7 and 8. The control animals were killed on days 4, 6, 7, 8, 20 and 40. Samples of brain, spinal cord, liver, kidneys, spleen, thymus, lymph nodes, lungs, heart, skeletal muscle, stomach, small and large intestine, urinary bladder, pancreas, adrenal glands, testes, ovaries, uterus and bone marrow were taken for histologic investigations. In addition, squash preparations were made from brain tissue. Histologic sections and squash preparations were stained with haematoxylin-eosin and Giemsa's stain, respectively.

RESULTS

Lesions consisting of periportal infiltrates of lymphocytes, histiocytes and eosinophilic granulocytes were present in the liver two days after infection. The infiltrates increased in size until day nine and gradually decreased thereafter

¹ Institut für Tierpathologie der Universität München, Veterinärstr. 13, D-8000 München 22. Federal Republic of Germany.

² Institut für Vergleichende Tropenmedizin und Parasitologie der Universität München, Leopoldstr. 5, D-8000 München 40. Federal Republic of Germany.

³ Present address: Institut für Parasitologie der Tierärztlichen Hochschule Hannover, Bünteweg 17, D-3000 Hannover 71. Federal Republic of Germany.

until day 18 (Fig. 1). In addition, irregularly disseminated foci of necrosis occurred from the 6th to the 8th day (Fig. 1). Schizogonic stages of the parasite were present in the liver from the 5th to the 8th day. The observed schizonts were in various stages of development from undifferentiated uninuclear cells to mature schizonts with merozoites (Fig. 2).

The spleen was enlarged up to twice its normal size on days 4 to 16 due to proliferation of the secondary follicles and of histiocytic elements in the red pulp. Lymphoid hyperplasia also was observed in some of the lymph nodes during this period.

Circumscribed perivascular lymphohistiocytic infiltrates developed in the myocardium, skeletal muscle and brain of some animals between the 7th and the

10th day. Vasculitis of the large veins of the lungs was present in one case.

A parasitic cyst was first found in the brain of a vole killed at day 23. This cyst was round and contained only a few round merozoites (Fig. 3). Mature cysts which developed later were deeply lobulated and contained large numbers of small banana-shaped cystozoites.

DISCUSSION

In conclusion, it could be stated that the observed lesions were all induced by the development of parasitic stages belonging to the first asexual multiplication period. Cellular infiltrates were present in the liver on day two, when parasitic stages were not yet detectable. Necrotic foci and cellular infiltrates in

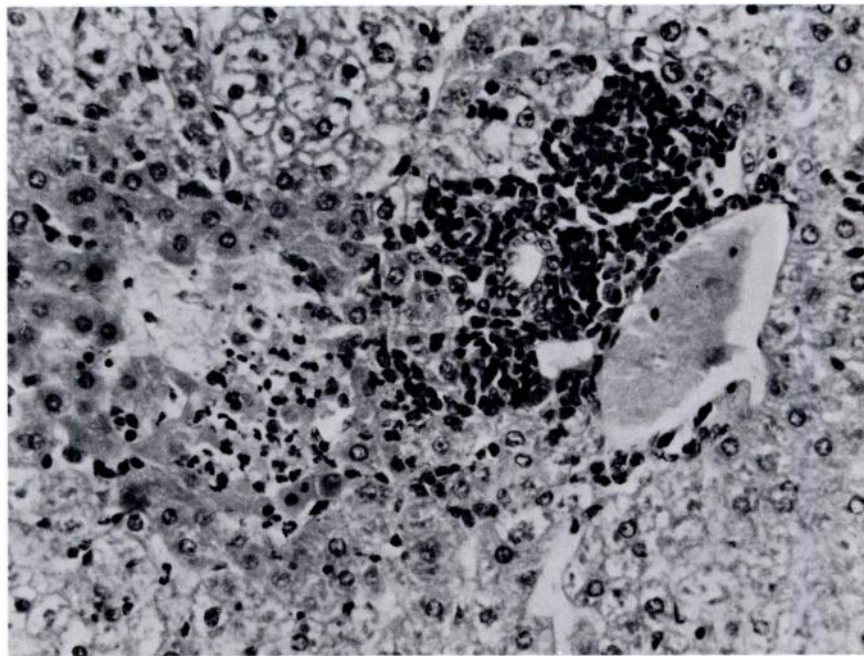


FIGURE 1. Periportal cellular infiltrates and focal necrosis with granulocytic reactions in the liver of *Microtus agrestis*, seven days after infection with *Frenkelia microti*. H&E, $\times 250$

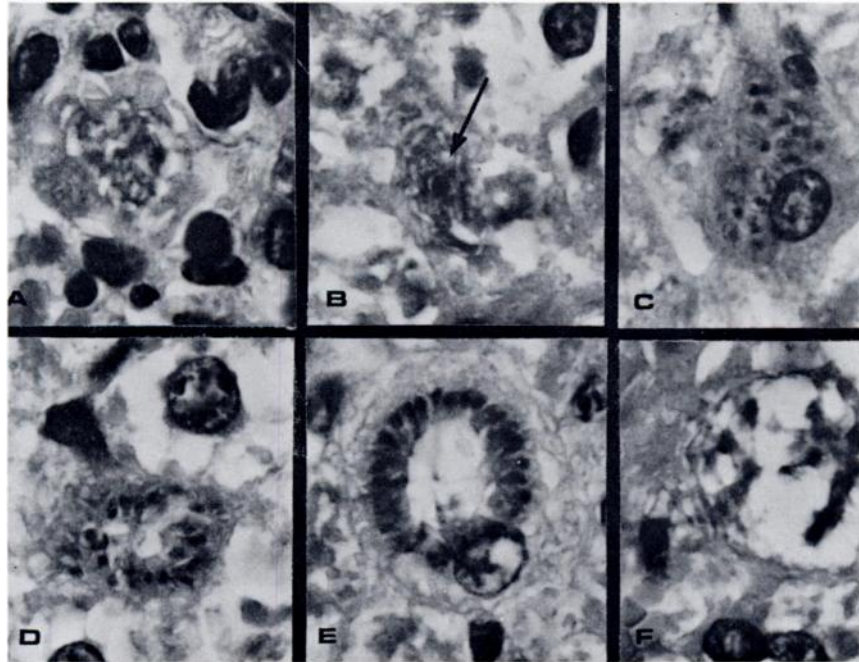


FIGURE 2. Developmental stages of *Frenkelia microti* during the first asexual multiplication phase in the liver of *Microtus agrestis*, seven days after infection. H&E, $\times 1000$

- A: foamy cytoplasm of schizont;
 B: beginning differentiation of the nuclear material (arrow);
 C: numerous nuclei in a liver parenchymal cell;
 D: beginning orientation of the nuclei towards the periphery of the cell;
 E: radial arrangement of merozoites;
 F: empty host cell, the merozoites have already left the site.

the liver, and splenomegaly were the most conspicuous features from day four until complete restoration of the spleen on day 16. Lesions developed in other organs after the mature merozoites had disappeared from the liver and were probably produced by parasitic stages which had reached these organs via the blood stream. No lesions were detectable during the second asexual multiplication period of the parasite leading to the formation of cysts in the brain.

The lesions observed in the present study were similar to those described in

bank voles (*Clethrionomys glareolus*) infected experimentally with *F. glareoli*.¹ In that species, necrotic foci and cellular infiltrates in the liver and reactions of lymphatic tissues also were characteristic for the period of the first asexual multiplication phase of the parasite.¹ However, the infected bank voles developed moderate erythrophagia in various organs as well as immunocytic reactions and necrotic foci in the central nervous system during chronic infections. It is not known why such lesions were not present in short-tailed voles.

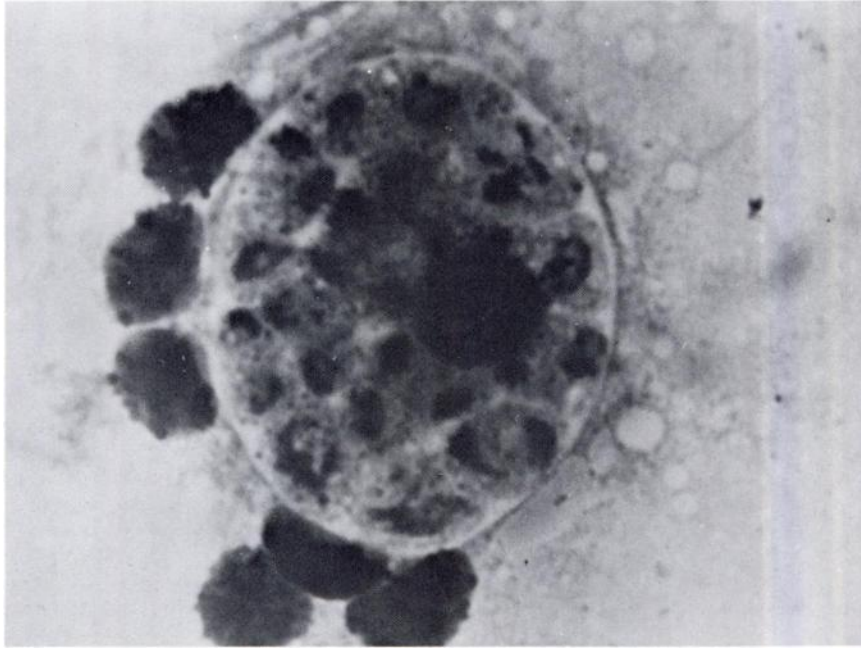


FIGURE 3. Immature *Frenkelia microti* cyst from the brain of *Microtus agrestis* (size about 300 μ m). Twenty-three days after infection, squash preparation, Giemsa's stain, \times 2500

LITERATURE CITED

1. GEISEL, O., E. KAISER, H.E. KRAMPITZ and M. ROMMEL. 1978. Beiträge zum Lebenszyklus der Frenkelien. IV. Pathomorphologische Befunde an den Organen experimentell infizierter Rötelmäuse. *Vet. Pathol.* 15: 621-630.
2. KRAMPITZ, H.E. and M. ROMMEL. 1977. Experimentelle Untersuchungen über das Wirtsspektrum der Frenkelien der Erdmaus. *Berl. Münch. Tierärztl. Wschr.* 90: 17-19.
3. ROMMEL, M. and H.E. KRAMPITZ. 1978. Weitere Untersuchungen über das Zwischenwirtsspektrum und den Entwicklungszyklus von *Frenkelia microti* in der Erdmaus. *Zbl. Vet. Med. B*, 25: 273-281.

Received for publication 3 August 1978