

TONSILLAR CARCINOMA WITH METASTASES IN A CAPTIVE WOLF 1

Authors: RYAN, M. J., and NIELSEN, S. W.

Source: Journal of Wildlife Diseases, 15(2) : 295-298

Published By: Wildlife Disease Association

URL: <https://doi.org/10.7589/0090-3558-15.2.295>

BioOne Complete (complete.BioOne.org) is a full-text database of 200 subscribed and open-access titles in the biological, ecological, and environmental sciences published by nonprofit societies, associations, museums, institutions, and presses.

Your use of this PDF, the BioOne Complete website, and all posted and associated content indicates your acceptance of BioOne's Terms of Use, available at www.bioone.org/terms-of-use.

Usage of BioOne Complete content is strictly limited to personal, educational, and non - commercial use. Commercial inquiries or rights and permissions requests should be directed to the individual publisher as copyright holder.

BioOne sees sustainable scholarly publishing as an inherently collaborative enterprise connecting authors, nonprofit publishers, academic institutions, research libraries, and research funders in the common goal of maximizing access to critical research.

TONSILLAR CARCINOMA WITH METASTASES IN A CAPTIVE WOLF [□]

M. J. RYAN and S. W. NIELSEN, Northeastern Research Center for Wildlife Diseases, College of Agriculture and Natural Resources, University of Connecticut, Storrs, Connecticut 06268, USA.

Abstract: Gross and histopathologic findings of primary tonsillar squamous carcinoma with metastases to lymph nodes of the neck and thorax and to the lung in a captive 13-year-old male wolf are presented.

INTRODUCTION

Squamous cell carcinoma of the tonsil is a frequent neoplasm of older dogs,^{1,6,7,8} and urban dogs have a significantly higher prevalence of this tumor than do rural dogs.^{3,4} This paper describes tonsillar carcinoma in a wolf (*Canis lupus*).

HISTORY

In January, 1978, a 13-year-old wolf was submitted to the Northeastern Research Center for Wildlife Diseases. The wolf had been used for breeding purposes at the Biobehavioral Sciences Department, University of Connecticut since it was obtained from the Brookfield Zoo, Chicago, Illinois, at about 18 months of age. The diet consisted primarily of dry commercial dog food with fresh beef bones weekly. The animal was kept outdoors in an enclosed yard.

The wolf had been clinically normal until the summer of 1977 when depression, anorexia, weight loss, and staggering gait were observed. There was poor hair growth as the weather became colder, except in the neck region where hair growth was normal. In its last few weeks of life there was increased coughing and more severe ataxia, excessive salivation, and a distortion of facial expression. Euthanasia was performed.

GROSS FINDINGS

The right pharyngeal tonsil was greatly enlarged (3.5 × 2.5 × 2.0 cm), and protruded from the tonsillary crypt. On section the right tonsil was creamy-white, soft, but did not have any surface ulceration. The left pharyngeal tonsil and oral cavity appeared normal. The mandibular, medial retropharyngeal, cranial, and caudal deep cervical lymph nodes were greatly enlarged bilaterally. Soft, creamy-white tissue surrounded the hyoid bones and distended the right and left tracheal lymphatic ducts. The cranial mediastinal, and tracheo-bronchial lymph nodes were enlarged and creamy-white on section, and there were several nodules and white discolorations, 8.0 mm in diameter, on the dorsal surface of the cranial lobes of the lungs. There was serous atrophy of cardiac fat and several biliary cysts were present in the liver.

HISTOPATHOLOGY

Deep clefts and nests of squamous cells invaded the lymphoreticular portion of the tonsil. The clefts, cut in cross section, sometimes resembled ducts, but intercellular bridges identified the cell type as an acanthocyte. Keratinization of single cells was infrequent, and "pearls" were not present. Normal lymphoid architecture was obliterated (Fig. 1).

[□] Scientific Contribution No. 721, Storrs Agricultural Experiment Station, University of Connecticut, Storrs, Connecticut 06268, USA.

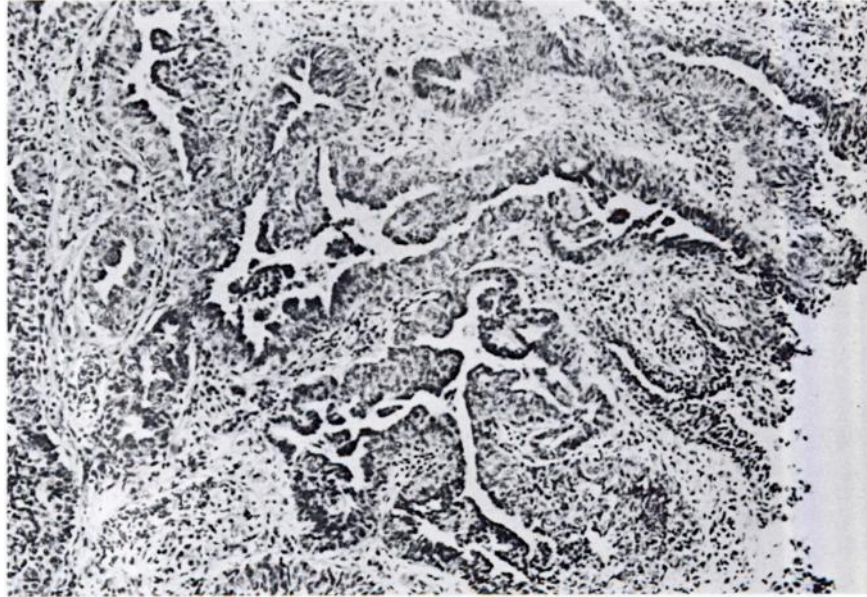

FIGURE 1. Proliferation of squamous tonsillar epithelium and its invasion in deep clefts. H&E $\times 63$.

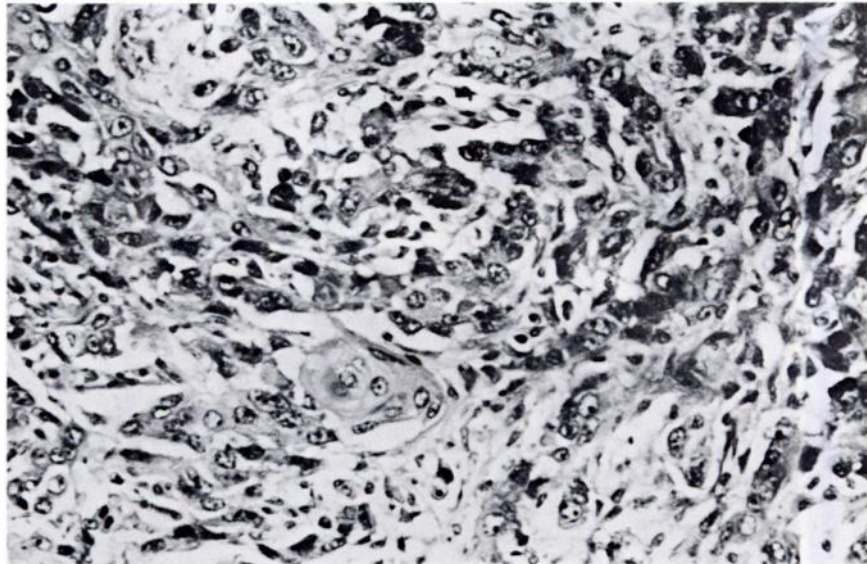


FIGURE 2. Invasion of soft tissue of the neck by nests of anaplastic tumor cells and keratinization. H&E $\times 160$.

The lymph nodes of the thorax and neck were invaded by highly anaplastic carcinomatous cells only showing squamous epithelial differentiation in the form of isolated cells containing kerato-hyalin granules. Solid nests of cells without stromal support or basement membrane, surrounded by lymphocytes, were present in the sinusoids of the lymph nodes. In some nodes no lymphoreticular architecture could be seen.

Fibrous tissue and skeletal muscle of the neck were invaded by multiple bands and nests of squamous cells with incipient "pearls" (Fig. 2). Subpleural metastases were similar to those of the lymph nodes, with similar degree of anaplasia and pleomorphism, and no encapsulation (Fig. 3).

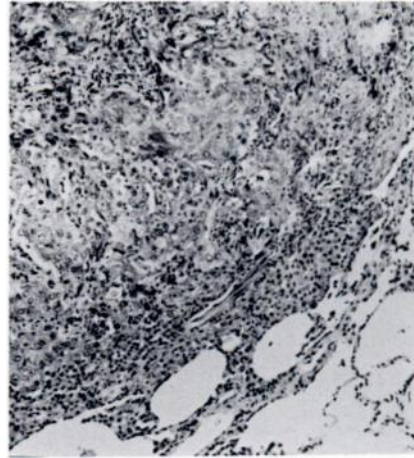


FIGURE 3. Edge of discrete pulmonary nodule of tumor cell invasion. H&E \times 63.

DISCUSSION

Tonsillar carcinoma has been extensively described in the dog and cat.² Generally the mass of metastatic tissue is greater by far than that of the primary tumor.⁸ A similar tonsillar tumor with lymph node metastasis and invasion of the soft tissue of the neck, leading to

ulceration of skin, was reported in a wolf at the London Zoological Gardens in 1928.⁵ The tonsillary origin of the tumor in this case may be consistent with the suggested association between canid tonsillary malignancy and the urban-industrial environment typical of house dogs and animals in captivity.^{3,4}

LITERATURE CITED

1. HEAD, K.W. 1958. The application of biopsy technique to accessible tumours in small animal practice. *Proc. Brit. Sm. An. Vet. Congr.*, pp. 55-62.
2. MOULTON, J.E. 1961. *Tumors in Domestic Animals*. Univ. of Calif. Press, Berkeley, pp. 130-131.
3. RAGLAND, W.L. and J.R. GORHAM. 1967. Tonsillar carcinoma in rural dogs. *Nature (Lond.)* 214: 925-926.
4. REIF, J.S. and D. COHEN. 1971. The environmental distribution of canine respiratory tract neoplasms. *Arch. Environ. Health* 22: 136-140.
5. SCOTT, H.H. 1928. Carcinoma of the tonsil in a common wolf. *Proc. Zool. Soc. Lond.*, pp. 43-47.
6. STÜNZI, H. and P. RUSTERHOLZ. 1958. Zur klinik und Pathologischen Anatomie des Tonsillkarzinoma beim Hund. *Schweiz. Arch. Tierheilkunde* 100: 271-277.
7. WITHERS, F.W. 1939. Squamous-celled carcinoma of the tonsil in the dog. *J. Path. Bact.* 49: 429-432.

-
8. WYERS, M., K. IRGENS and A.L. PARODI. 1969. Le cancer de l'amygdale dans l'espèce canine. Rec. Méd. Vét. Ecole Alfort 145: 333-351.

Received for publication 15 June 1978
