

ADRENAL CORTICAL ADENOMA IN A DAMA GAZELLE (*Gazella dama*)

Authors: SCHMIDT, R. E., and FLETCHER, K. C.

Source: Journal of Wildlife Diseases, 15(2) : 299-301

Published By: Wildlife Disease Association

URL: <https://doi.org/10.7589/0090-3558-15.2.299>

BioOne Complete (complete.BioOne.org) is a full-text database of 200 subscribed and open-access titles in the biological, ecological, and environmental sciences published by nonprofit societies, associations, museums, institutions, and presses.

Your use of this PDF, the BioOne Complete website, and all posted and associated content indicates your acceptance of BioOne's Terms of Use, available at www.bioone.org/terms-of-use.

Usage of BioOne Complete content is strictly limited to personal, educational, and non - commercial use. Commercial inquiries or rights and permissions requests should be directed to the individual publisher as copyright holder.

BioOne sees sustainable scholarly publishing as an inherently collaborative enterprise connecting authors, nonprofit publishers, academic institutions, research libraries, and research funders in the common goal of maximizing access to critical research.

ADRENAL CORTICAL ADENOMA IN A DAMA GAZELLE (*Gazella dama*)

R. E. SCHMIDT, Veterinary Sciences Division, USAF School of Aerospace Medicine, Brooks Air Force Base, Texas 78235, USA.

K. C. FLETCHER, San Antonio Zoo, San Antonio, Texas 78212, USA.

Abstract: An adrenal cortical adenoma found in an aged dama gazelle (*Gazella dama*) is described.

INTRODUCTION

Neoplasms of the adrenal gland have been considered among the most common visceral tumors of cattle^{4,5} and sheep.² Cortical adenomas were most common of the adrenal neoplasms of cattle.⁶ In wild bovids there have been few reports of adrenal tumors. Three adenomas were reported in Bovidae and Cervidae from the Philadelphia Zoo,³ and a cortical adenoma was reported in an European mouflon (*Ovis ammon musimon*) from the San Diego Zoo.¹ Neither of these papers described or illustrated the neoplasms. This report describes an adrenal cortical tumor in a dama gazelle (*Gazella dama*) from the San Antonio Zoo.

CLINICAL FINDINGS

A female gazelle, approximately 12 years of age, appeared weak and was slow to rise from sternal recumbency, particularly on colder mornings. The animal evaded the first attempt at hand capture, but two days later she was very lethargic and was caught and separated from the herd.

She was thin (33.6 kg) and her legs and trunk had multiple linear abrasions. Hydration was normal. The teeth were worn slightly below the gum lines, with many sharp points on the premolars. Rectal body temperature was 38 C; heart rate was 90 with a strong pulse. Auscultation of the thorax was unremarkable.

General supportive therapy was initiated, but the animal died on the second day.

GROSS PATHOLOGY

The lungs were reddened. The pericardial sac was thickened, opaque, and slightly distended with a green-tinged serous fluid. The epicardium had petechial and ecchymotic hemorrhages. The hepatic capsule was covered with multiple radiating dilated capillaries, and the parenchyma had an accentuated lobular pattern. Mesenteric and omental fat depots were minimal, and there was generalized serous atrophy. A mass measuring approximately 6 × 8 cm with a smooth, undulating outline and a thick, firm, white capsule was located on the midline and attached to the dorsal parietal peritoneum, just cranial to the kidneys. The mass surrounded the abdominal aorta and renal arteries and veins, but was not attached to these vessels or to the kidneys. On cross section the mass consisted of clotted blood within a fine trabecular network. Embedded within the large mass was a smaller ovoid mass, approximately 3 × 4 cm, with a smooth white capsule. This structure protruded from the surface of the large mass adjacent to the cranial pole of the right kidney. Neither adrenal gland could be identified. No other tumors were noted in any organ or body cavity.

MICROSCOPIC PATHOLOGY

The mass had a thick fibrous capsule and was very cellular, with several variations of a basic growth pattern. Immediately beneath the capsule was an area resembling normal adrenal cortex with some disorganization of the cords and considerable hemorrhage. The remainder of the mass consisted of variably sized and shaped cords or nests of cells separated by a delicate connective tissue stroma and numerous vascular spaces (Fig. 1). The neoplastic cells had round to ovoid nuclei, small nucleoli, abundant clear or slightly granular cytoplasm and fairly well defined cell membranes. In some areas there was cellular anaplasia and loss of the cord pattern. Large cells with hyperchromatic convoluted nuclei were scattered in these areas (Fig. 2). Sections

stained with Gomori's chromaffin stain were negative for chromaffin granules.

DISCUSSION

The neoplasm described in this report has the histologic characteristics of an adrenal cortical adenoma, and no metastases were found. Adrenal cortical adenomas are common endocrine tumors of domestic Bovidae^{4,5,6} and may be more common in wild animals of the family Bovidae than the few reported cases would indicate. Some of those reported in cattle were considered functional,⁶ but no laboratory tests of adrenal function were made in this case, and the debilitated state of the animal made clinical assessment of adrenal cortical function difficult.

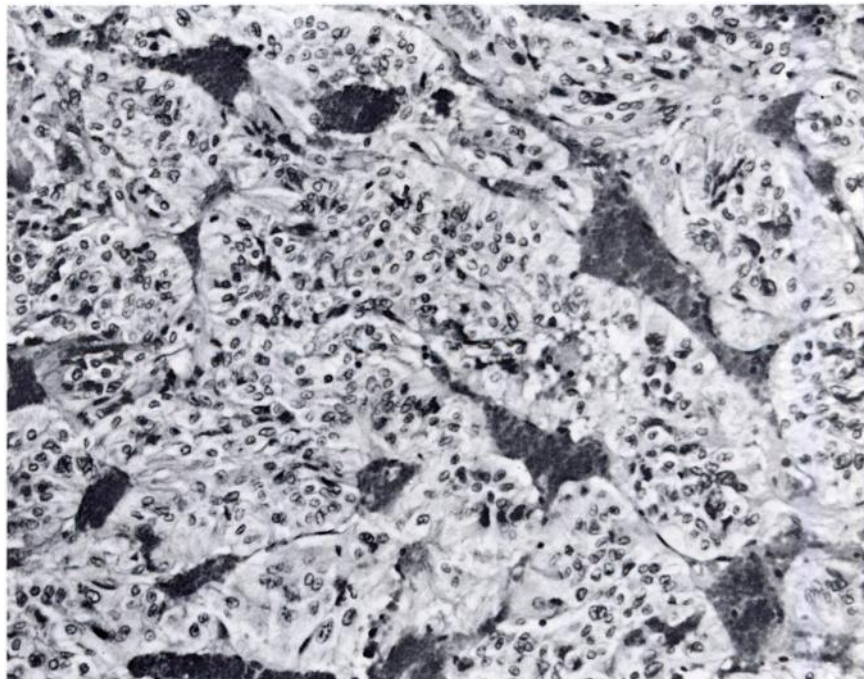


FIGURE 1. Irregularly shaped cords of neoplastic cells separated by vascular spaces in adrenal cortical adenoma from dama gazelle. H&E \times 190.

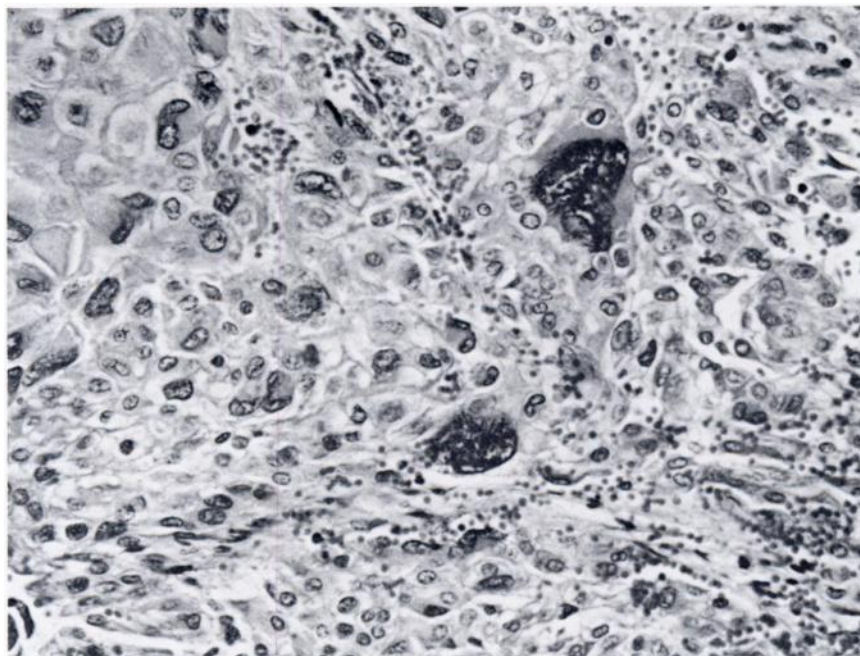


FIGURE 2. Area of cellular anaplasia and loss of cord pattern in adrenal cortical adenoma. Note the occurrence of large cells with hyperchromatic convoluted nuclei. H&E \times 230.

LITERATURE CITED

1. EFFRON, M., L. GRINER and K. PENIRSCHKE. 1977. Nature and rate of neoplasia found in captive wild mammals, birds and reptiles at necropsy. *J. Natl. Cancer Inst.* 59: 185-198.
2. JUBB, K.V.F. and P.C. KENNEDY. 1970. *Pathology of Domestic Animals*, 2nd Ed., Vol. 1, Academic Press, New York. pp 424-427.
3. LOMBARD, L.S. and E.J. WITTE. 1959. Frequency and types of tumors in mammals and birds of the Philadelphia Zoological Garden. *Cancer Res.* 19: 127-141.
4. MOULTON, J.E. 1961. *Tumors in Domestic Animals*, Univ. of Calif. Press, Berkeley and Los Angeles. pp 197-201.
5. SMITH, H.A., T.C. JONES and R.D. HUNT. 1972. *Veterinary Pathology*, 4th Ed., Lea & Febiger, Philadelphia, Pa.
6. WRIGHT, B.J. and G.H. CONNER. 1968. Adrenal neoplasms in slaughter cattle. *Cancer Res.* 28: 251-263.

Received for publication 26 June 1978