



MICROSPORIDAL ENCEPHALITIS IN MUSKRATS

Authors: WOBESER, G., and SCHUH, J. C. L.

Source: Journal of Wildlife Diseases, 15(3) : 413-417

Published By: Wildlife Disease Association

URL: <https://doi.org/10.7589/0090-3558-15.3.413>

BioOne Complete (complete.BioOne.org) is a full-text database of 200 subscribed and open-access titles in the biological, ecological, and environmental sciences published by nonprofit societies, associations, museums, institutions, and presses.

Your use of this PDF, the BioOne Complete website, and all posted and associated content indicates your acceptance of BioOne's Terms of Use, available at www.bioone.org/terms-of-use.

Usage of BioOne Complete content is strictly limited to personal, educational, and non - commercial use. Commercial inquiries or rights and permissions requests should be directed to the individual publisher as copyright holder.

BioOne sees sustainable scholarly publishing as an inherently collaborative enterprise connecting authors, nonprofit publishers, academic institutions, research libraries, and research funders in the common goal of maximizing access to critical research.

MICROSPORIDAL ENCEPHALITIS IN MUSKRATS

G. WOBESER and J. C. L. SCHUH, Department of Veterinary Pathology, Western College of Veterinary Medicine, University of Saskatchewan, Saskatoon, Saskatchewan, Canada. S7N 0W0

Abstract: Microsporida similar morphologically to *Encephalitozoon cuniculi* were found in granulomatous foci in the brain of 5 of 29 wild-caught muskrats (*Ondatra zibethica*) held in captivity for various periods of time, but not in any of 36 free-living muskrats examined. The significance and possible source of this infection are discussed.

INTRODUCTION

Encephalitozoon cuniculi is a common parasite of laboratory rabbits and mice and similar microsporida have been reported in other mammals,¹⁴ including man,^{8,9} and in birds.^{6,12} This report describes the occurrence of microsporida in the nervous system of captive muskrats (*Ondatra zibethica*) and the results of a limited survey of free-ranging muskrats for this parasite.

MATERIALS AND METHODS

Small focal areas of granulomatous encephalitis were encountered during routine histologic examination of the brain of a captive muskrat used for other studies. After microsporida were identified in these foci, a search was made for these parasites in tissues from other muskrats. Tissues were examined from 12 wild-caught muskrats that had been in captivity in indoor cages for from 35 to 270 days prior to necropsy, 17 wild-caught muskrats held in outdoor pens for from 10 to 20 days prior to necropsy, and material available in our files from 36 free-living muskrats examined as diagnostic cases between 1972 and 1977. Paraffin-embedded blocks of formalin-fixed brain, kidney, liver, spleen, lung and intestine from the captive animals, and from brain and kidney of the earlier diagnostic cases were sectioned at 6 μ m and slides were stained with hematoxylin-eosin (H&E) and either

Brown-Brenn Gram stain⁷ or a simple acetone Gram stain for Gram-positive bacteria.⁴ The Ziehl-Neelsen and Giemsa stains and the Periodic-Acid Schiff (PAS) reaction⁷ were used on selected cases. At the suggestion of Dr. J.R. Allen, Department of Veterinary Microbiology, H&E stained slides were examined with the aid of a phase contrast microscope. Ultra-thin sections for electron-microscopic examination were prepared from H&E stained sections of selected cases using a modification of the method of Rossi *et al.*,¹⁵ (epon was used as an embedding medium rather than Diucupan I). Because of a possibility that wild house mice (*Mus musculus*) might have served as a source of infection for the captive muskrats, 26 mice were trapped in and about the indoor holding area and brain and renal tissues were examined histologically using the same techniques.

PATHOLOGY FINDINGS

Foci of granulomatous encephalitis in association with microsporida were found in histologic sections of the brain of 4 of 12 muskrats held in indoor pens, 1 of 17 muskrats held in outdoor pens. None was found in 36 free-ranging muskrats submitted as diagnostic cases or 26 house mice trapped about the indoor cage area. A single tiny focus of granulomatous inflammation was found in the brain of one wild-caught muskrat, but no

organisms were found in serial sections prepared from the animal's brain.

The granulomatous foci consisted of small collections of epithelioid cells together with occasional lymphocytes and plasma cells (Fig. 1). Necrosis was evident in the centre of a few foci. There was limited infiltration by lymphocytes and plasma cells in perivascular spaces and the overlying meninges in association with some foci. The foci were dispersed widely throughout the brain, but were most common in cerebral cortex and none was found in the cerebellum. Small numbers of spores, approximately 1×2 to $2.5 \mu\text{m}$, were visible either free or within cells in some foci. Most spores did not stain with H&E, whereas others were very faintly basophilic, and most were somewhat refractile. The outer surface stained basophilic with either of the Gram stains, and there was a darker central region internally, with one or two polar vacuoles (Fig. 2). The spores were distinctly refractile under phase contrast

and often more spores were evident with this method than in parallel Gram-stained sections. The spores were basophilic with Giemsa stain, had a PAS-positive granule at one end and were variably acid-fast. In addition to the organisms in granulomas, larger accumulations of spores (up to $60 \times 120 \mu\text{m}$), unaccompanied by any inflammatory reaction, were found in the brain of three of the "indoor" muskrats (Fig. 3). Although there was a good deal of artifactual change in the ultra-thin sections, a three-layered wall and a coiled polar filament were clearly evident within the oval spores (Fig. 4).

No spores were found in any other organ, and no other lesions could be associated with microsporidia.

The single infected animal among those maintained in the outdoor pens had been in captivity for 12 days, whereas the infected animals among the group held inside had been in captivity for from 3 to 7 months. The lesion found

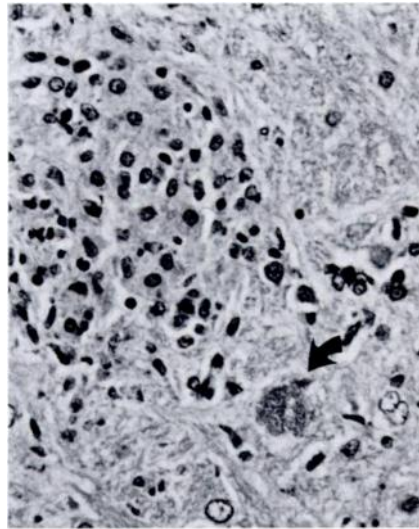


FIGURE 1. Small focus of granulomatous encephalitis in a muskrat brain. A small collection of spores is visible adjacent to the focus. (arrow) H&E $\times 110$

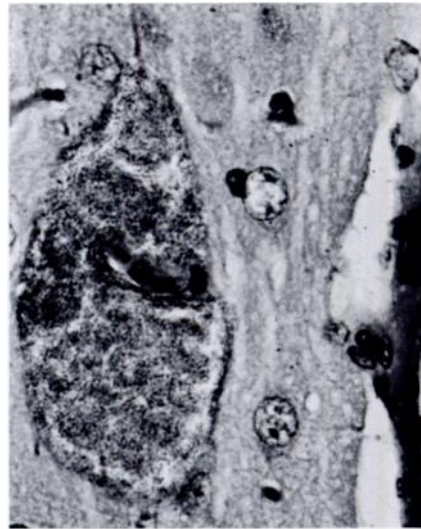


FIGURE 2. Large collection of spores without any attendant inflammatory reaction in the brain of a muskrat. H&E $\times 270$

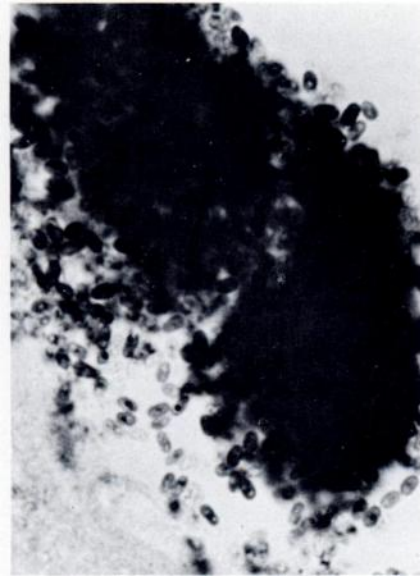


FIGURE 3. Microsporidan spores in the brain of a muskrat. Note that the wall and central area stain intensely and that polar vacuoles are present. Gram $\times 1190$

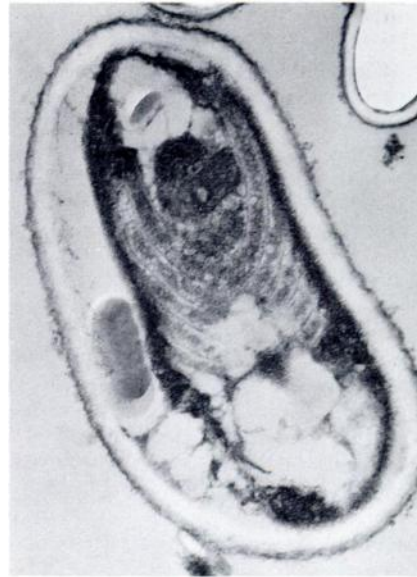

FIGURE 4. Ultraphotomicrograph of spore from muskrat brain. The spore wall appears to have three layers and a coiled polar filament is evident. $\times 29,600$

in the "outdoor" animal was a single well-developed granuloma containing a small number of spores.

DISCUSSION

The spores present in the muskrats can be identified as those of a microsporidan on the basis of the presence of a polar filament. The lesions in the muskrats are similar to those reported in *E. cuniculi* infection of laboratory rabbits and mice; moreover, the staining affinity, size and ultrastructure of the spores correspond to those reported for *E. cuniculi*.^{13,16} The microsporida from mice, rabbits and hamsters are likely of a single species, *E. cuniculi*,¹³ but the relationships among other mammalian microsporida require further study. At least two apparently distinct microsporida have been described: *Nosema connori* from a human,¹⁷ and *Thelohania apodemi* from a

vole (*Apodemus sylvaticus*).⁵ The latter parasite produced lesions resembling those in the muskrats, but the spores of *T. apodemi* were larger and were arranged in groups of eight.

There was no evidence of clinical disease due to the microsporida in the muskrats. The major significance of microsporida in laboratory animals is through interference with the interpretation of experimental results,¹⁶ but *E. cuniculi* may alter the immune responsiveness of rabbits.³ In contrast to the benign nature of infection in rodents and lagomorphs, microsporida can be highly pathogenic for carnivores^{1,10,11,18,19} and infected muskrats might serve as a source of infection for carnivores.

The 33% prevalence of infection in the indoor group of muskrats was similar to the prevalence of *E. cuniculi* infection reported in laboratory rabbits and rodents,¹⁶ and was much higher than

that in the outdoor captive, and free-ranging muskrats, suggesting that infection occurred in captivity. There was no direct contact between the muskrats and conventional laboratory animals; however, at least three possible sources of infection were found. The indoor muskrats were held in a room that had been used previously for laboratory rats, and infective material from rats might have survived cleaning and disinfection of the room. The muskrats were fed commercial pellets obtained from feed bins in a laboratory animal colony in which rabbits were known to be infected and infection might have been transferred in this way. The room in which the muskrats were housed suffered an infestation of house mice at one point due to an ill-fitting door; however, no microsporidia were found in any of the 26 house mice examined.

The presence of a well-established lesion in a muskrat which had been in captivity for only 12 days suggests that infection in that case might have occurred prior to capture. The duration of the life cycle of *E. cuniculi* in a natural infection is unknown, but spores were formed within 2 days in tissue culture,¹³ or 5 days in tumour cells.¹⁴ Thus, spore formation might have occurred within the 12 day period; however, it seems unlikely that infection, spore production and release, and the granulomatous inflammatory response would all have occurred within this period. Administration of cortisone has been shown to increase both the frequency and severity of lesions in mice latently infected with *E. cuniculi*,² and the stress of captivity may have unmasked latent infections and/or promoted new infections in muskrats.

LITERATURE CITED

1. BASSON, P.A., R.M. McCULLY and W.E.J. WARNES. 1966. Nosematosis: report of a canine case in the Republic of South Africa. *J.S. Afr. vet. med. Ass.* 37: 3-9.
2. BISMANNIS, J.E. 1970. Detection of latent murine nose matosis and growth of *Nosema cuniculi* in cell cultures. *Can. J. Microbiol.* 16: 237-240.
3. COX, J.C. 1977. Altered immune responsiveness associated with *Encephalitozoon cuniculi* infection in rabbits. *Inf. and Immun.* 15: 392-395.
4. CULLING, C.F.A. 1963. *Handbook for Histopathological Techniques*. Butterworths, London. 553 p.
5. DOBY, J.M., A. JEANNES and B. RAULT. 1963. *Thelohania apodemi* n. sp., premiere microsporidie du genre *Thelohania* observee chez un mammifere. *C.R. Acad. Sci. (Paris)* 257: 248-251.
6. KEMP, R.L. and J.P. KLUGE. 1975. *Encephalitozoon* sp. in the Blue-masked lovebird (*Agapornis personata* Reichenow): first confirmed report of microsporidan infection in birds. *J. Protozool.* 22: 489-491.
7. LUNA, L.G. 1968. *Manual of Histologic Staining Methods of the Armed Forces Institute of Pathology*. 3rd ed. McGraw-Hill. Toronto. 258 p.
8. MARGILETH, A.M., A.J. STRANO, R. CHANDRA, R. NEAFIE, M. BLUM and R.M. McCULLY. 1973. Disseminated nose matosis in an immunologically compromised infant. *Arch. Pathol.* 95: 145-150.
9. MATSUBAYASHI, H., T. KOIKE, I. MIKATA, H. TAKAI and S. HAGIWARA. 1959. A case of *Encephalitozoon*-like body infection in man. *Arch. Pathol.* 67: 181-185.
10. NORDSTOGA, K. 1972. Nosematosis in blue foxes. *Nord Vet-Med.* 24: 21-24.

11. ——— and K. WESTBYE. 1976. Polyarteritis nodosa associated with nosematosis in blue foxes. *Acta. Path. Microbiol. Scand.* A84: 291-296.
12. NOVILLA, M.N. and R.P. KWAPIEN. 1978. Microsporidian infection in the Pied Peach-faced Lovebird (*Agopornis roseicollis*). *Av. Dis.* 22: 198-204.
13. PAKES, S.P., J.A. SHADDUCK and A. CALI. 1975. Fine structure of *Encephalitozoon cuniculi* from rabbits, mice and hamsters. *J. Protozool.* 22: 481-488.
14. PETRI, M. 1969. Studies on *Nosema cuniculi* found in transplantable ascites tumors with a survey of microsporidiosis in mammals. *Acta. Path. Microbiol. Scand., Suppl.* 204: 1-91.
15. ROSSI, G.L., H. LUGINBUHL and D. PROBST. 1970. A method for ultrastructural study of lesions found in conventional histological sections. *Virchow. Arch. Abt. A. Path. Anat.* 350: 216-244.
16. SHADDUCK, J.A. and S.P. PAKES. 1971. Encephalitozoonosis (Nosematosis) and Toxoplasmosis. *Am. J. Pathol.* 64: 657-671.
17. SPRAGUE, V. 1974. *Nosema connori* n. sp., a microsporidian parasite of man. *Trans. Am. Micros. Soc.* 93: 400-402.
18. VAN RENSBURG, I.B.J. and J.L. DU PLESSIS. 1971. Nosematosis in a cat: a case report. *J. S. Afr. vet. med. Ass.* 42: 327-331.
19. VAVRA, J., K. BLAZEK, N. LAVICKA, I. KOEZKOVA, S. KALAFKA and M. STEHLIK. 1971. Nosematosis in carnivores. *J. Parasit.* 57: 923-924.

Received for publication 7 February 1979
