

PATHOGENICITY ATTRIBUTED TO MASSIVE INFECTION OF *Nanophyetus salmincola* IN A COUGAR 1

Authors: KISTNER, T. P., WYSE, DELORES, and SCHMITZ, J. A.

Source: Journal of Wildlife Diseases, 15(3) : 419-420

Published By: Wildlife Disease Association

URL: <https://doi.org/10.7589/0090-3558-15.3.419>

The BioOne Digital Library (<https://bioone.org/>) provides worldwide distribution for more than 580 journals and eBooks from BioOne's community of over 150 nonprofit societies, research institutions, and university presses in the biological, ecological, and environmental sciences. The BioOne Digital Library encompasses the flagship aggregation BioOne Complete (<https://bioone.org/subscribe>), the BioOne Complete Archive (<https://bioone.org/archive>), and the BioOne eBooks program offerings ESA eBook Collection (<https://bioone.org/esa-ebooks>) and CSIRO Publishing BioSelect Collection (<https://bioone.org/csiro-ebooks>).

Your use of this PDF, the BioOne Digital Library, and all posted and associated content indicates your acceptance of BioOne's Terms of Use, available at www.bioone.org/terms-of-use.

Usage of BioOne Digital Library content is strictly limited to personal, educational, and non-commercial use. Commercial inquiries or rights and permissions requests should be directed to the individual publisher as copyright holder.

BioOne is an innovative nonprofit that sees sustainable scholarly publishing as an inherently collaborative enterprise connecting authors, nonprofit publishers, academic institutions, research libraries, and research funders in the common goal of maximizing access to critical research.

PATHOGENICITY ATTRIBUTED TO MASSIVE INFECTION OF *Nanophyetus salmincola* IN A COUGAR [□]

T. P. KISTNER, [□] DELORES WYSE [□] and J. A. SCHMITZ [□]

Abstract: An estimated 650,000 *Nanophyetus salmincola* were recovered from the small intestine of a wild female cougar kitten (*Felis concolor*). The trematodes stimulated marked mucosal thickening in the duodenum and jejunum and caused a marked enteritis. Malnutrition was listed as the cause of death due to impaired nutrient absorption resulting from the combined effects of the diarrhea and thickening of the intestine.

INTRODUCTION

Nanophyetus salmincola is a ubiquitous intestinal trematode which infects a wide range of piscivorous avian and mammalian hosts in a limited geographic area. The life cycle and geographical distribution of *N. salmincola* have been described in detail.²

Following discovery of the relationship between *N. salmincola* and salmon poisoning disease of dogs, primary emphasis has been directed toward determining the pathogenicity of the disease agents *Neorickettsia helminthoeca* and *N. elokominia*. Pathogenicity studies on the adult trematode in the definitive host are lacking, but cercariae are reported to be pathogenic in salmonid fishes.¹ The purpose of this paper is to report the first documented case of *N. salmincola* infection in the cougar (*Felis concolor*) and the first case of pathogenicity resulting from massive infection of adult *N. salmincola*.

CASE HISTORY

The female cougar kitten was observed for a few weeks feeding on dead salmon in the vicinity of Fall Creek Fish

Hatchery in Lane County, Oregon. She subsequently entered a chicken house in the vicinity, was live-trapped by the owner and then transferred to Corvallis, Oregon, where she was placed in a pen and fed daily until death, five days later. The carcass was examined at this laboratory.

The hair coat was rough and matted and the carcass emaciated. There was a brownish discharge from the nostrils, and the perineum was stained with fluid fecal material. All four canine teeth were broken.

The lungs were mildly emphysematous, with all lobes affected. The heart was flaccid. Catarrhal gastritis and colitis were present and the stomach contained bile. The small intestine was thickened and turgid. Splenic lymphoid follicles were prominent.

Representative somatic tissues were collected, fixed in 10% buffered formalin, processed routinely and stained with hematoxylin and eosin (H&E). The intestine was ligated at the pylorus and rectum, removed from the carcass and injected with buffered 10% formalin. Subsequently, a series of sections were made of the small intestine and colon and

[□] Oregon Agricultural Experiment Station Technical Paper No. 4817.

[□] Department of Fisheries and Wildlife, Oregon State University, Corvallis, Oregon 97331, USA.

[□] School of Veterinary Medicine, Oregon State University, Corvallis, Oregon 97331, USA.

stained with either H&E or Masson's trichrome.

Histopathologic examination of the lungs revealed emphysema, interstitial pneumonia and congestion. The splenic lymphoid follicles were hyperplastic and the parenchyma was unusually dense. The mucosa of the small intestine was markedly thickened due to fibrous proliferation of the lamina propria with numerous *N. salmincola* distributed superficially and midzonally (Fig. 1A). Trematodes were situated in intervillus spaces or dilated crypts of Lieberkuhn with flattened epithelial linings (Fig. 1B). Small foci of necrosis were present in the lamina propria adjacent to trematodes and some crypts contained small amounts of necrotic debris. The superficial lamina propria contained a mild mixed leukocytic infiltrate.

This is believed to be the first documented case of *N. salmincola*

infection in the cougar and the first case of pathogenicity attributed to adult trematodes of this species. Lesions of "salmon poisoning" were not present, which is not surprising since only canids and the black bear apparently are susceptible to the rickettsiae.

The kitten, probably an orphan, was forced to fend for herself and, starving, she fed on dying salmon. Salmon usually are heavily infected with metacercariae of *N. salmincola*. The metacercariae would have reached maturity in the cougar's gut in 5 to 7 days.² An estimated 650,000 adult trematodes were recovered. The actual count probably was higher since an undetermined quantity of intestinal contents was lost during necropsy. The massive infection of trematodes caused thickening of the intestinal wall which probably interfered with nutrient absorption and caused diarrhea, with death resulting from malnutrition.

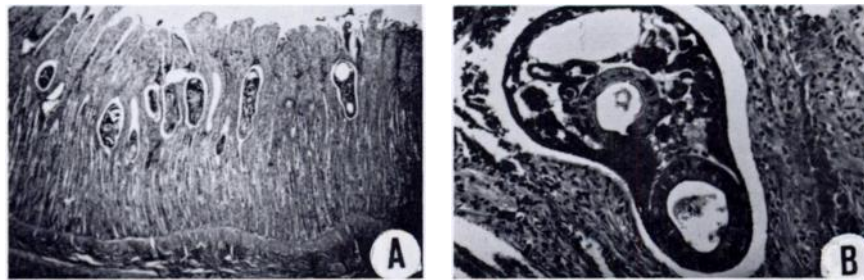


FIGURE 1. Photomicrographs of cougar intestine. A. Section through small intestine showing marked thickening of the lamina propria and several trematodes in situ (10 \times). B. Enlargement of a sectioned trematode (160 \times).

LITERATURE CITED

1. BUTLER, J.A. and R.E. MILLEMANN. 1971. Effect of the "Salmon Poisoning" trematode, *Nanophyetus salmincola*, on the swimming ability of juvenile salmonid fishes. *J. Parasit.* 57: 860-865.
2. MILLEMANN, R.E. and S.E. KNAPP. 1970. Biology of *Nanophyetus salmincola* and "Salmon Poisoning" disease. *Adv. Parasit.* 8: 1-39.

Received for publication 19 April 1978