

## **MORPHOLOGIC EVIDENCE OF POXVIRUS IN “TATTOO” LESIONS FROM CAPTIVE BOTTLENOSED DOLPHINS 1**

Authors: FLOM, JAMES O., and HOUK, EDWARD J.

Source: Journal of Wildlife Diseases, 15(4) : 593-596

Published By: Wildlife Disease Association

URL: <https://doi.org/10.7589/0090-3558-15.4.593>

---

BioOne Complete ([complete.BioOne.org](https://complete.BioOne.org)) is a full-text database of 200 subscribed and open-access titles in the biological, ecological, and environmental sciences published by nonprofit societies, associations, museums, institutions, and presses.

Your use of this PDF, the BioOne Complete website, and all posted and associated content indicates your acceptance of BioOne's Terms of Use, available at [www.bioone.org/terms-of-use](http://www.bioone.org/terms-of-use).

Usage of BioOne Complete content is strictly limited to personal, educational, and non - commercial use. Commercial inquiries or rights and permissions requests should be directed to the individual publisher as copyright holder.

---

BioOne sees sustainable scholarly publishing as an inherently collaborative enterprise connecting authors, nonprofit publishers, academic institutions, research libraries, and research funders in the common goal of maximizing access to critical research.

## MORPHOLOGIC EVIDENCE OF POXVIRUS IN "TATTOO" LESIONS FROM CAPTIVE BOTTLENOSED DOLPHINS<sup>□</sup>

JAMES O. FLOM and EDWARD J. HOUK, Naval Biosciences Laboratory, Naval Supply Center, Oakland, California 94625, USA.

**Abstract:** Skin lesions known as "tattoos", were observed in several captive Atlantic bottlenosed dolphins (*Tursiops truncatus*) maintained at the Naval Ocean Systems Center, San Diego, California. Biopsy of typical lesions and subsequent ultrastructural examination revealed intracytoplasmic particles with poxvirus morphology.

### INTRODUCTION

"Tattoo" lesions, in dolphin skin, appear as irregular circumscribed discolorations, consisting of numerous small pigmented dots (1 mm).<sup>1</sup> The head is the most frequent site for lesions, although they may occur on any portion of the body.<sup>9</sup> Horizontal transmission is uncommon, but small epidemics have been recorded.<sup>3</sup> The lesions may remain months or years without causing any apparent ill effects to the animal; however, one dolphin died after developing generalized lesions.<sup>9</sup> The causative agent has not been identified in previous studies.<sup>2,7,9</sup>

The observation of intracytoplasmic particles, morphologically characteristic of poxvirus, in "tattoo" lesions from captive Atlantic bottlenosed dolphins (*Tursiops truncatus*) is reported herein.

### MATERIALS AND METHODS

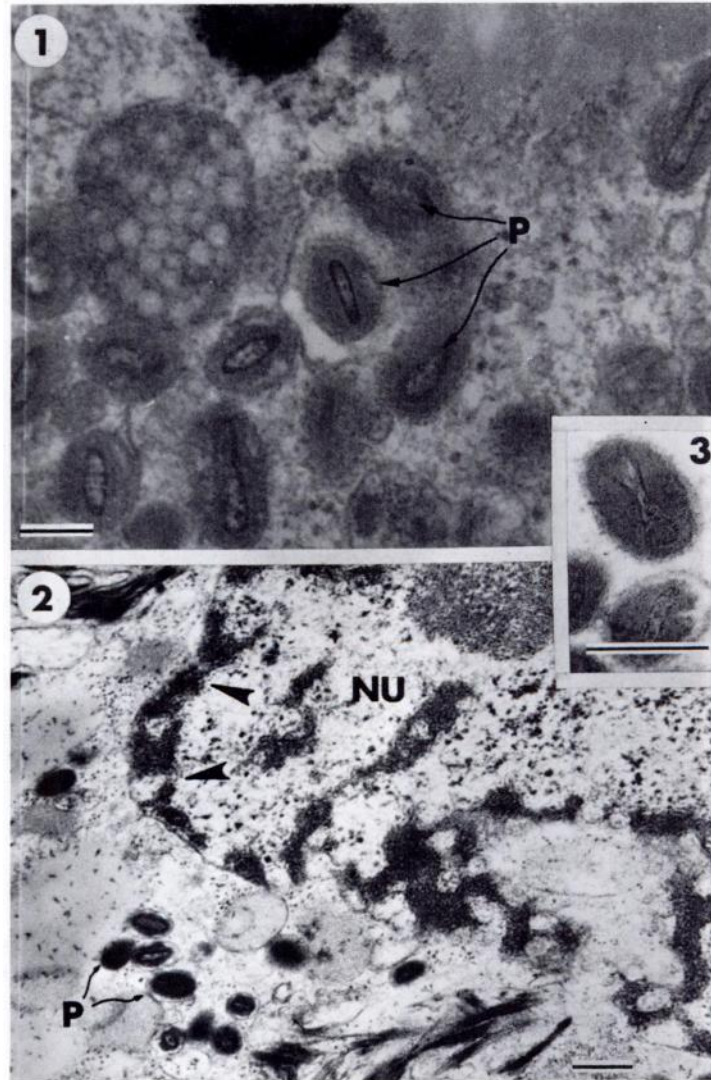
Three mature Atlantic bottlenosed dolphins, designated as 1, 2 and 3, were maintained as part of a group of dolphins at the Naval Oceans Systems Center, San Diego, California. Each dolphin was originally caught in the Gulf of Mexico and had been in captivity for several years. Dolphin one was maintained separately, but dolphins two and three

occupied the same tank; biopsies from the latter two animals were taken several months following biopsy of animal one. Except for the "tattoo" lesions, each appeared to be in good health at the time of biopsy. Epidermal portions of "tattoo" lesions were surgically removed from each animal and immediately fixed in 5% glutaraldehyde.<sup>6</sup> Once the tissues were returned to the laboratory, they were sliced into sections of about 1 mm thickness and fixation in glutaraldehyde was allowed to continue for at least 2 h at 5 C. Subsequent post-osmication, dehydration, embedding and staining are described elsewhere.<sup>4</sup> Thin sections were examined in a Siemens Elmiskop 1A at 80 KV.

### RESULTS

Intracytoplasmic particles were observed in epithelial fragments from lesions in dolphin one and dolphin two (Figs. 1 and 2). The particles, in both samples, were morphologically identical and their physical dimensions averaged 220 nm × 105 nm. Probably examination of additional thin sections from the third dolphin also would have revealed the intracytoplasmic particles. Some particles had the characteristic poxvirus dumbbell-shaped core (nucleoid) compressed between two elliptical bodies and

<sup>□</sup> This study was supported by the Office of Naval Research.



**FIGURE 1.** Epithelial cell from dolphin one "tattoo" illustrating intracytoplasmic particles (P). Mark = 150 nm.

**FIGURE 2.** Epithelial cell from dolphin two "tattoo" illustrating intracytoplasmic particles (P); nucleus (NU) demonstrates membrane irregularity along with margination and clumping of chromatin (arrows). Mark = 250 nm.

**FIGURE 3.** Particle with typical poxvirus morphology. Note the dumbbell-shaped core surrounded by two lateral bodies and an outer enclosing membrane. Mark = 200 nm.

enclosed by an outer envelope (Fig. 3).<sup>1</sup> Changes in affected cells included irregularity of nuclear membranes and clumping and margination of nuclear chromatin (Fig. 2).<sup>1</sup> Insufficient biopsy tissue prevented standard histologic examination for inclusion bodies.

## DISCUSSION

"Tattoo" lesions have been recognized for several years, particularly in captive *T. truncatus* from the Gulf of Mexico.<sup>2</sup> Systematic inquiry has not been followed in most cases since the lesions do not usually spread between animals nor become pathologically significant. Standard histologic examination of "tattoos" has revealed each pigmented dot within the lesion to be a concentration of epidermal cells, characterized by fragmented nuclei and clear cytoplasm.<sup>7</sup> Inclusion bodies have not been observed in previous "tattoo" studies.<sup>2,7</sup> The intracytoplasmic particles observed in the thin sections of this study are typical of poxviruses. The size and shape of the particles seen in the "tattoo" lesions suggest a similarity to the sheep pox sub-

group,<sup>1</sup> although further studies are needed before classification is attempted.

Poxviruses have been reported in a wide variety of birds and mammals<sup>10</sup> including seals.<sup>7,11,12</sup> However, while seals and dolphins share the marine environment, the lesions and virus particles of sealpox differ from those seen in dolphin "tattoos". The usual quiescent and non-contagious nature of "tattoo" lesions<sup>2</sup> is unlike the contagious and progressive development characteristic of lesions of sealpox.<sup>12</sup> Properties unique to dolphin skin<sup>3</sup> may contribute to these differences. The extremely high rate of turnover in dolphin epidermal cells causes rapid disappearance of superficial scratches or marks. In fact, clean superficial wounds often heal within 48 h and even deep wounds within seven days.

Additional studies, employing techniques in virus propagation, immunology, standard histopathology and further investigation with electron microscopy are needed before conclusive statements can be made regarding pox disease in dolphins. This finding is also notable as the first supportable evidence of a virus disease in cetaceans.

## Acknowledgements

The authors extend their thanks to Dr. Sam Ridgway and the personnel at the Naval Ocean Systems Center, San Diego, California, for furnishing the dolphin "tattoo" lesions, and to Mr. Robert Chiles at the Naval Biosciences Laboratory, Oakland, California, for his technical assistance in the preparation of the electron micrographs.

## LITERATURE CITED

1. FENNER, F., B.R. McAUSLAN, C.A. MIMS, J. SAMBROOK and D.O. WHITE. 1974. *The Biology of Animal Viruses*. 2nd ed., Academic Press, Inc., New York.
2. GREENWOOD, A.G., R.J. HARRISON and H.W. WHITTING. 1974. Functional and pathological aspects of the skin of marine mammals, pp. 73-111. In: *Functional Anatomy of Marine Mammals*. R.J. HARRISON, Ed. Academic Press, Inc., London.
3. HARRISON, R.J. and K.W. THURLEY. 1974. Structure of the epidermis in Tursiops, Delphinus, Orcinus and Phocena, pp. 45-73. In: *Functional Anatomy of Marine Mammals*. R.J. Harrison, Ed. Academic Press, London.

4. HOUK, E.J. 1976. Midgut ultrastructure of *Culex tarsalis* (Diptera: Culicidae) before and after a bloodmeal. *Tissue and Cell*. 9: 103-118.
5. LING, J.K. 1974. The integument of marine mammals, pp. 1-45. In: *Functional Anatomy of Marine Mammals*. R.J. Harrison, Ed. Academic Press, London.
6. McLEAN, D.L. and E.J. HOUK. 1973. Phase contrast and electron microscopy of the mycetocytes and symbiotes of the pea aphid, *Acyrtosiphon pisum* (Harris). *J. Insect Phys.* 19: 625-632.
7. SIMPSON, J.G. and M.B. GARDNER. 1972. Comparative microscopic anatomy of selected marine mammals, pp. 363-377. In: *Mammals of the Sea*, S.H. Ridgway, Ed. Charles C. Thomas, Springfield, Ill.
8. SWEENEY, J.C. 1974. Common diseases of pinnipeds. *J. Am. vet. med. Assoc.* 165: 805-810.
9. RIDGWAY, S.H. 1975. Common diseases of small cetaceans. *J. Am. vet. med. Ass.* 167: 533-539.
10. WILNER, B.I. 1969. *A Classification of the Major Groups of Human and Other Animal Viruses*. Burgess Publishing, Minneapolis, Minnesota.
11. WILSON, T.M. and P.R. SWEENEY. 1970. Morphological studies of seal poxvirus. *J. Wildl. Dis.* 6: 94-96.
12. DYKES, R.W. and K.S. TSAI. 1972. Pox in young, captive harbor seals. *J. Am. vet. med. Ass.* 161: 611-617.

*Received for publication 15 December 1978*

---