



POX INFECTION AMONG CAPTIVE PEACOCKS

Authors: AL FALLUJI, M. M., TANTAWI, H. H., ALBANA, A., and AL SHEIKHLY, S.

Source: Journal of Wildlife Diseases, 15(4) : 597-600

Published By: Wildlife Disease Association

URL: <https://doi.org/10.7589/0090-3558-15.4.597>

BioOne Complete (complete.BioOne.org) is a full-text database of 200 subscribed and open-access titles in the biological, ecological, and environmental sciences published by nonprofit societies, associations, museums, institutions, and presses.

Your use of this PDF, the BioOne Complete website, and all posted and associated content indicates your acceptance of BioOne's Terms of Use, available at www.bioone.org/terms-of-use.

Usage of BioOne Complete content is strictly limited to personal, educational, and non - commercial use. Commercial inquiries or rights and permissions requests should be directed to the individual publisher as copyright holder.

BioOne sees sustainable scholarly publishing as an inherently collaborative enterprise connecting authors, nonprofit publishers, academic institutions, research libraries, and research funders in the common goal of maximizing access to critical research.

POX INFECTION AMONG CAPTIVE PEACOCKS

M. M. AL FALLUJI, H. H. TANTAWI, A. AL-BANA and S. ALSHEIKHLY, Department of Microbiology, College of Veterinary Medicine, Baghdad University, Iraq.

Abstract: An outbreak of avian pox was detected among captive peacocks (*Pavo cristatus*) at Baghdad Zoological Park during spring, 1978. A total of 45 of the 60 birds in the aviary developed pox lesions around the beaks and eyes. Morbidity was 75% and mortality was 13%. A virus isolated from the skin lesions produced large plaques on the chorioallantoic membrane of developing chicken embryos and induced cytopathic effect characteristic for pox viruses in chicken embryo cell cultures. The virus neither haemagglutinated nor haemadsorbed to chicken erythrocytes. It was ether resistant and chloroform sensitive. Chickens inoculated with the virus by scarification developed localized pox-like lesions, while turkeys had only transient swelling of feather follicles at the site of inoculation. Virus partially purified with Genetron 113 was precipitated by antisera to fowlpox and pigeon pox viruses.

INTRODUCTION

During the spring of 1978, 45 of 60 peacocks (*Pavo cristatus*) in the Baghdad Zoological Park had skin lesions resembling those of fowlpox. These birds had been vaccinated against fowlpox with a chicken embryo-adapted Canadian strain of fowlpox virus vaccine. Peacocks were the only birds affected among other wild and domestic birds in the aviary.

Avian pox occurs commonly in fowls, turkeys, pigeons, guinea fowl, quail, pheasants, hawks, buntings, canaries, sparrows and other wild birds.⁴ Spontaneous pox infection also has been recorded in starlings.⁵

Bi-pathogenic strains of Avipox virus affecting pigeons, chickens and other birds have been reported.³

Although close antigenic relationships between the Avipox viruses has been reported, cross immunity in avian pox has been found to be highly variable.^{2,4}

This communication deals with the isolation and identification of the causative agent of a pox-like disease naturally occurring in captive peacocks.

MATERIALS AND METHODS

Virus isolation

Skin lesions collected from naturally-infected peacocks were kept at -70 C, 10 percent suspensions of the lesions were prepared in phosphate buffered saline (pH 7.2) containing 100 IU of penicillin and 100 ug/ml of streptomycin. The suspensions were checked for sterility and kept at -70 C. This material was inoculated for virus isolation onto the chorioallantoic membrane of II-13 day old specific-pathogen-free (SPF) chicken embryos. The inoculated embryos were incubated at 37 C for 5 days with regular daily examination. Membranes with pock lesions were collected for further passage of the virus. Three successive passages of the virus were carried out and virus titres were calculated and expressed by pock forming units (PFU).

Chorioallantoic membranes (CAM) for histopathologic examination were sectioned at 4-6 μ m and stained with haematoxylin-eosin and Giemsa.

Ether and chloroform sensitivity was determined by the methods of Andrewes and Horstmann¹ and Feldman and Wang.² Chicken embryo fibroblastic cell

cultures were used to grow the virus, to study its cytopathic effect, and to test the capability of infected cells to haemadsorbe chicken erythrocytes.

Virus haemagglutinating activity was tested against chicken, turkey and pigeon erythrocytes using conventional methods.

Host range specificity

Chickens, turkeys and pigeons were used to study the host range specificity of the isolated virus. Eleven 4-week-old chicks were inoculated with 0.2 ml (12×10^4 PFU) of the virus by scarification on the comb and wattles. Another 4 chicks were inoculated intravenously. All chicks used had no previous exposure to pox agents. Three 2 to 3 month old turkeys were exposed by skin scarification and by inoculation into the feather follicles. Two more turkeys were inoculated by intravenous route and by intrafollicular injection. The virus inoculum was 0.5 ml. (12×10^4 PFU/0.2 ml per bird) in both groups of turkeys. Ten pigeons were exposed by skin scarification only with 0.2 ml of the stock virus (12×10^4 PFU).

Virus purification

A virus suspension prepared from infected chorioallantoic membranes was treated with an equal amount of trichlorotrifluoroethane[□] for 5 min then centrifuged at 1500 x g for 10 min. The aqueous fraction was collected.

Antisera against fowlpox and pigeon pox viruses were used against the partially purified viral antigen in immunodiffusion tests using 1% agarose in distilled water.

RESULTS

Virus isolation

A virus isolated from the skin lesions on the CAM of the developing chick

embryos produced small haemorrhagic plaques 4 to 5 days after inoculation. The plaques gradually increased in diameter by serial passages on CAM. The virus produced large discrete elevated white plaques 3-5 mm in diameter (Figure 1) after the third and fourth passages. Although titres reached 12×10^4 PFU/0.2 ml, the virus was not lethal to embryos. Histopathology of infected CAM revealed proliferation of the ectodermal layer as much as two to three cell layers thicker than normal CAM. The ectodermal cells showed hydropic degeneration and some of them were associated with small inclusion bodies. In the mesoderm, congestion, extensive exudation and marked emigration of polymorphonuclear leucocytes from blood vessels was observed.

The virus grew in chicken embryo fibroblast cells producing syncytia and cell rounding, with complete destruction of the monolayer by 4 days after inoculation. Infected cells failed to adsorb chicken erythrocytes. Virus suspensions of infected CAM and tissue culture origin failed to agglutinate erythrocytes of

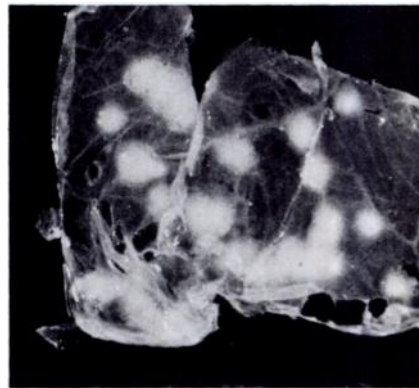


FIGURE 1. Lesions on the chorioallantoic membrane 5 days after inoculation with virus.

[□] Arcton 113, Fluka AG Chemische Fabrik, CH-9470 Buschs SG, Schweiz.

chicken, turkey and pigeon. The virus titre was reduced moderately (1×10^4 PFU/0.2 ml) after treatment with ether, while treatment with chloroform resulted in complete loss of infectivity.

In chickens infected by scarification the virus produced a cutaneous form of pox on day 4 and a diphtheretic form on days 12 to 14. No lesions were detected in chickens infected by intravenous inoculation. The virus produced skin lesions in only one of 10 pigeons infected by scarification. Turkeys inoculated with the virus showed only transient swelling of the feather follicles but no pox lesions (Table 1).

Agar gel diffusion test

The tissue culture and CAM virus as well as the Genetron partially purified viral antigens were all precipitated in agar gel by antisera against fowlpox and pigeon pox viruses.

DISCUSSION

Earlier work on pox viruses has shown that domestic and wild birds are affected by members of the Avipox virus group. The work presented here has shown that the pox virus isolated from peacocks was related to the Avipox virus group and was highly pathogenic to chickens. Peacocks may be reservoirs for a pox virus that could cause epidemics in chickens. The failure of the virus to produce pox lesions in turkeys may be related to previous exposure as they were obtained from the market.

The infected birds were all vaccinated against fowlpox two months before the onset of the outbreak. The apparent vaccine failure may be due to unsuccessful vaccination or ineffective vaccine. It is also possible that the peacock virus is a different virus in the Avipox virus group. Further work is required to compare the peacock pox virus with fowlpox, turkeypox and pigeon pox viruses.

TABLE 1. Experimental inoculation of birds with the virus isolated from peacocks.

Species	number	route of inoculation	results
Chickens	11	Scarification	All birds showed cutaneous and diphtheritic pox lesions.
	4	I/V*	No lesions
Pigeons	10	Scarification	Only one bird showed cutaneous form of the disease.
Turkeys	3	Scarification and I/F•	Transient swelling of the feather follicles.
	2	I/V and I/F	Transient swelling of the feather follicles.

* = intravenous

• = intrafollicular

LITERATURE CITED

- ANDREWES, C.H. and D.M. HORSTMANN. 1949. The susceptibility of viruses to ethyl ether. *J. Gen. Microbiol.* 3: 290-292.
- FELDMAN, H.S. and S.S. WANG. 1961. Sensitivity of various viruses to chloroform. *Proc. Soc. Exptl. Biol. Med.* 106: 737-738.
- IRONS, V. 1934. Cross species transmission studies with different strains of bird pox. *Am. J. Hyg.* 20: 329-351.
- KIRMSE, P. 1969. Host specificity and pathogenicity of pox viruses from wild birds. *Bull. Wildl. Dis. Ass.* 5: 376-386.

5. MARSHA, L. and M.K. RICHARD. 1976. Transmission of avian pox from starlings to rothchilds nynahs. *J. Wildl. Dis.* 12: 353-356.
6. McGAUGHEY, C.A. and F.M. BURNET. 1945. Avian pox in wild sparrows. I. A note on spontaneous outbreak. II. A note on the activity of sparrow pox virus in the canary. *J. Comp. Path.* 55: 201-205.
7. TRIPATHY, D.H., L.E. HANSON and A.H. KILLINGER. 1973. Studies on differentiation of avian pox viruses. *Avian Dis.* 17: 325-333.

Received for publication 13 March 1979
