

Lagochilascaris major IN A RACCOON

Authors: CRAIG, T. M., ROBINSON, R. M., McARTHUR, N. H., and
WARD, R. D.

Source: Journal of Wildlife Diseases, 16(1) : 67-70

Published By: Wildlife Disease Association

URL: <https://doi.org/10.7589/0090-3558-16.1.67>

The BioOne Digital Library (<https://bioone.org/>) provides worldwide distribution for more than 580 journals and eBooks from BioOne's community of over 150 nonprofit societies, research institutions, and university presses in the biological, ecological, and environmental sciences. The BioOne Digital Library encompasses the flagship aggregation BioOne Complete (<https://bioone.org/subscribe>), the BioOne Complete Archive (<https://bioone.org/archive>), and the BioOne eBooks program offerings ESA eBook Collection (<https://bioone.org/esa-ebooks>) and CSIRO Publishing BioSelect Collection (<https://bioone.org/csiro-ebooks>).

Your use of this PDF, the BioOne Digital Library, and all posted and associated content indicates your acceptance of BioOne's Terms of Use, available at www.bioone.org/terms-of-use.

Usage of BioOne Digital Library content is strictly limited to personal, educational, and non-commercial use. Commercial inquiries or rights and permissions requests should be directed to the individual publisher as copyright holder.

BioOne is an innovative nonprofit that sees sustainable scholarly publishing as an inherently collaborative enterprise connecting authors, nonprofit publishers, academic institutions, research libraries, and research funders in the common goal of maximizing access to critical research.

Lagochilascaris major IN A RACCOON

T. M. CRAIG, Department of Veterinary Microbiology and Parasitology, Texas A&M University, College Station, Texas 77843, USA.

R. M. ROBINSON, Texas Veterinary Diagnostic Laboratory, College Station, Texas 77843, USA.

N. H. McARTHUR, Department of Veterinary Anatomy, Texas A&M University, College Station, Texas 77843, USA.

R. D. WARD, Harris County Health Department, Houston, Texas 77055, USA.

Abstract: A granulomatous mesenteric mass containing numerous adult *Lagochilascaris major* was found in a raccoon near Houston, Texas. This is the first report of a *Lagochilascaris* in a species other than the opossum in North America.

INTRODUCTION

Lagochilascaris spp. have been found in lions in central Africa,⁵ the stomach, esophagus and trachea of a cat in Argentina,^{3,6} the larynx of an ocelot in Costa Rica,¹ the stomachs of opossums in the United States^{2,7} and Brasil,⁵ and from purulent draining tracts in the region of the head and neck of man in Brasil, Surinam, Trinidad, Tobago and Costa Rica.⁵ A mesenteric mass containing numerous adult *Lagochilascaris major* was observed in a raccoon (*Procyon lotor*) captured in Bear Creek Park, Harris County, Texas.

CASE HISTORY

Bear Creek Park is a popular picnic area just west of Houston, Texas, where a large flood control reservoir is located. A raccoon attracted to the area by picnic detritus was caught and handled by a teenage boy who was bitten. As a result of this bite 2 raccoons were captured in the area and heads submitted for rabies examination. A third, obviously sick, was submitted to the Texas Veterinary Medical Diagnostic Laboratory, College Station, Texas.

The raccoon was submitted in a comatose state and subsequently was euthanized. Gross post mortem findings

consisted of a large granulomatous mass approximately 4 × 5 cm in size situated on the mesentery between the stomach and duodenum. This mass consisted of purulent centers surrounded by granulomatous tissue. There was no apparent tract from the mass into the lumen of the intestine or stomach. The parasites were detected grossly within the purulent centers. Adult worms (Fig. 1) were teased from the granuloma for identification. A single *Gnathostoma* sp. and a number of *Lagochilascaris major* □ were recovered. The males were from 10.3 to 11.2 mm in length .52 to .57 mm wide with spicules from 408 to 478 mm in length. Females were 11.4 to 15.1 mm by .47 to .57 mm. The eggs 55-60 × 48-60 mm with 26 to 36 pits around the circumference of each egg. Diagnosis of *Lagochilascaris* sp. was made by Drs. V. F. Nettles and R. Davidson of the Southeastern Cooperative Wildlife Disease Study, Athens, Georgia. Specimens examined by professor J. F. A. Spret of the University of Queensland, Brisbane, Queensland, Australia were tentatively identified as *L. major*. Microscopically, nematodes were found in the purulent centers, which contained a large amount of necrotic tissue, and thick-shelled eggs were found scattered through this material. The granuloma was composed

□ Specimens deposited in the U.S. National Museum Helminthological Collection, accession #75402.

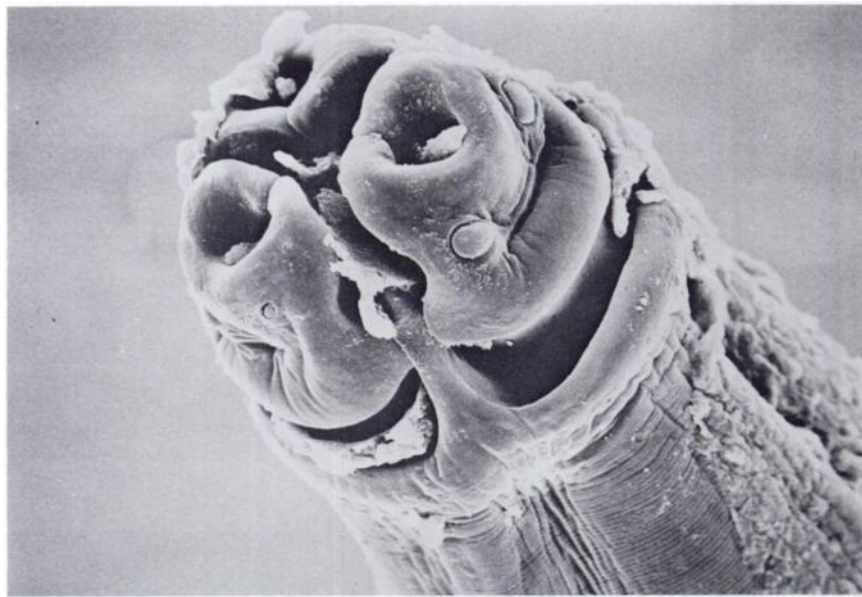


FIGURE 1. Scanning electron micrograph of the head of an adult *Lagochilascaris major* 564 \times .

of a thick fibrous tissue capsule diffusely infiltrated with eosinophils, lymphocytes and reticuloendothelial cells. An occasional egg of *Heterobilharzia americanum* was found in the fibrous capsule, as well as in the pancreatic tissue. These parasites also had elicited an eosinophilic response, but did not have the abundant necrotic-neutrophil response that characterized the *Lagochilascaris* lesion. (Fig. 2, 3). A diagnosis of distemper was also made, based on histological and fluorescent antibody test findings.

DISCUSSION

This is the only observation of a *Lagochilascaris* sp. in North America other than that of *L. turgida*² and as yet unspciated *Lagochilascaris*² in

opossums. The life cycle is apparently indirect with tissue migration and development occurring in the intermediate host.^{3,7} Since all human infections have been associated with purulent draining tracts around the head and neck, that specimens from felids are from the upper respiratory and gastrointestinal tracts and the present case indicate that tissue migration may also occur in the definitive host.

Because of the apparently close relationship between the various species within this genus, the possibility that this parasite is a zoonotic agent cannot be ruled out. The park area where the raccoon was captured is one in which a number of wild and feral animals roam. The source of infection to the raccoon is unknown. Several raccoons and opossums from this area subsequently

² Specimens examined by Dr. M. D. Little, Tulane University, New Orleans, Louisiana, USA, were similar to the *Lagochilascaris* recovered from Louisiana opossums.

have been examined, but no additional animals infected with *L. major* have been found. Studies to determine the prevalence of this parasite should give insight as to its host and geographic range.

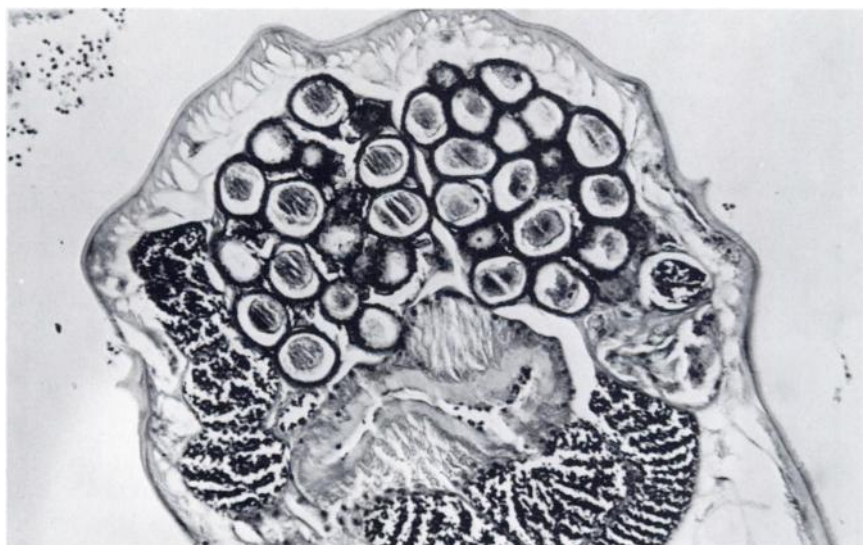

FIGURE 2. Cross section of *Lagochilascaris major* within granuloma, H&E $\times 25$.

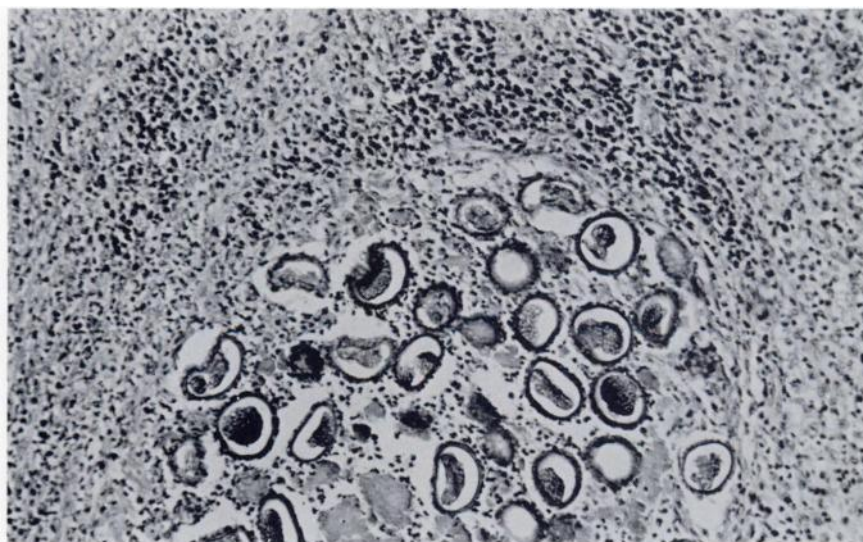


FIGURE 3. Mesenteric granuloma containing *Lagochilascaris major* eggs, H&E $\times 25$.

LITERATURE CITED

1. BRENES-MADRIGAL, R.R., A. RUIZ and J.K. FRANKEL. 1972. Discovery of *Lagochilascaris* sp. in the Larynx of a Costa Rican Ocelot (*Felis pardalis mearnsi*). J. Parasitol. 48: 978.
2. CANAVAN, W.P.N. 1931. Nematode Parasites of Vertebrates in the Philadelphia zoological garden and vicinity. Parasitology 23: 196-229.
3. LED, J.E., E.G. COLUMBO and E. BARABOGLIA. 1968. Primera comprobacion en Argentina de parasitismo en gato (*Felis catus domesticus*) por nematode del genero *Lagochilascaris*, Leiper 1909. Gaceta Vet, 30: 407-410.
4. LITTLE, M.D. 1964. Life cycle of *Lagochilascaris minor*. J. Parasitol. 50 (sec. 2) 34.
5. SPRENT, J.F.A. 1971. Speciation and development in the genus *Lagochilascaris*. Parasitology 62: 71-112.
6. ———. 1971. A note on *Lagochilascaris* from the cat in Argentina. Parasitology 63: 45-48.
7. SMITH, J.L., D.D. BOWMAN and M.D. LITTLE. 1978. Life cycle of a *Lagochilascaris* species (Nematoda) from the opossum in Louisiana, Abs. 53rd Ann. Meet. Am. Soc. Parasitol. 73.

Received for publication 22 May 1978
