

CHRONIC WASTING DISEASE OF CAPTIVE MULE DEER: A SPONGIFORM ENCEPHALOPATHY 1

Authors: WILLIAMS, E. S., and YOUNG, S.

Source: Journal of Wildlife Diseases, 16(1) : 89-98

Published By: Wildlife Disease Association

URL: <https://doi.org/10.7589/0090-3558-16.1.89>

The BioOne Digital Library (<https://bioone.org/>) provides worldwide distribution for more than 580 journals and eBooks from BioOne's community of over 150 nonprofit societies, research institutions, and university presses in the biological, ecological, and environmental sciences. The BioOne Digital Library encompasses the flagship aggregation BioOne Complete (<https://bioone.org/subscribe>), the BioOne Complete Archive (<https://bioone.org/archive>), and the BioOne eBooks program offerings ESA eBook Collection (<https://bioone.org/esa-ebooks>) and CSIRO Publishing BioSelect Collection (<https://bioone.org/csiro-ebooks>).

Your use of this PDF, the BioOne Digital Library, and all posted and associated content indicates your acceptance of BioOne's Terms of Use, available at www.bioone.org/terms-of-use.

Usage of BioOne Digital Library content is strictly limited to personal, educational, and non-commercial use. Commercial inquiries or rights and permissions requests should be directed to the individual publisher as copyright holder.

BioOne is an innovative nonprofit that sees sustainable scholarly publishing as an inherently collaborative enterprise connecting authors, nonprofit publishers, academic institutions, research libraries, and research funders in the common goal of maximizing access to critical research.

CHRONIC WASTING DISEASE OF CAPTIVE MULE DEER: A SPONGIFORM ENCEPHALOPATHY [□]

E. S. WILLIAMS and S. YOUNG, Wild Animal Disease Center and Department of Pathology, College of Veterinary Medicine and Biomedical Sciences, Colorado State University, Fort Collins, Colorado 80523, USA.

Abstract: In the past 12 years (1967-79) a syndrome we identify as chronic wasting disease has been observed in 53 mule deer (*Odocoileus hemionus hemionus*) and one black-tailed deer (*Odocoileus hemionus columbianus*) held in captivity in several wildlife facilities in Colorado and more recently in Wyoming. Clinical signs were seen in adult deer and included behavioral alterations, progressive weight loss and death in 2 weeks to 8 months. Gross necropsy findings included emaciation and excess rumen fluid admixed with sand and gravel. Consistent histopathologic change was limited to the central nervous system and characterized by widespread spongiform transformation of the neuropil, single or multiple intracytoplasmic vacuoles in neuronal perikaryons and intense astrocytic hypertrophy and hyperplasia. Presented is a clinical characterization of chronic wasting disease and pathologic evidence supporting the conclusion that the disease is a specific spontaneously occurring form of spongiform encephalopathy.

INTRODUCTION

The purpose of this report is to characterize the clinical aspects and pathology of chronic wasting disease (CWD) a hitherto undescribed encephalopathic disease of mule deer (*Odocoileus hemionus hemionus*).

CWD has been observed in captive mule deer in a wildlife facility in Colorado for the past 12 years (1967-79), and more recently in a similar facility in Wyoming. The disease has a high morbidity in young adult animals which have been maintained in captivity for periods of 2.5 to 4 years. In the period 1974-79, CWD affected 53 of 67 mule deer and one black-tailed deer (*Odocoileus hemionus columbianus*) held captive for more than 2 years.

The wildlife facilities in which the disease has been observed subserve experimental nutritional, metabolic and disease studies of deer and other non-domesticated ruminants. The majority (approximately 90%) of mule deer were

hand raised from infancy after they received colostrum and were separated from does at 1-5 days of age. Most were born to does trapped in the wild during pregnancy, brought to the facility, and released after parturition. The remainder were either born to resident does bred in captivity or orphan fawns captured in the wild. Fawns were bottle fed cow's milk supplemented with vitamins and weaned at 70-80 days of age. Thereafter, groups of 2 to 10 deer occupied pens approximately 0.1 to 1.0 ha in size and received rations of alfalfa hay, commercially mixed grains supplemented with minerals and vitamins, and fresh water. Over the years a variety of grain mixes have been used with protein content ranging from 12 to 20%. From time to time a few young adult deer trapped in the wild have been added to the permanent captive populations.

Within the facilities, deer have had irregular and discontinuous contact with other wild ruminants[□] and with

[□] This study was supported in part by N.I.H. (BRSG) Grant 5S07-RR-05458-17.

[□] Elk (*Cervus canadensis*), white-tailed deer (*Odocoileus virginianus*), pronghorn antelope (*Antilocapra americana*), Rocky Mountain bighorn sheep (*Ovis canadensis*), mouflon (*Ovis musimon*).

domestic cattle, goats and sheep. In addition, other feral mammalian species[□] either reside within or traverse the facilities' pens.

CLINICAL SIGNS

Clinical signs of CWD occurred only in mule deer maintained in captivity for a period of 2.5 to 4 years, whether raised from infancy by hand or captured in the wild as young adults. The disease affected males, females and castrates. Listlessness, progressive weight loss and depression with insidious onset and protracted course occurred over 2 weeks to 8 months, leading to emaciation (Fig. 1) and death. Onset occurred during all seasons. The majority of affected deer developed signs of polydipsia, polyuria, excessive salivation, grinding of the teeth, flaccid hypotonia of facial

muscles, lowering of the head, drooping of the ears and terminal anorexia. In some affected animals esophageal hypotonia and dilatation, difficulty in swallowing, regurgitation of rumenal fluid and ingesta, and depraved appetite occurred. Behavioral changes included episodes of apparent lack of awareness. Affected deer often stood for several minutes with lowered head and a fixed stare, and then reverted to a more normal state of alertness. Decreased interactions with unaffected deer in the group, occasional abnormal response to restraint and hyperexcitability were noted. Although behavioral changes were a consistent feature of CWD, specific motor or sensory neurologic signs were not identified. Equivocal visual deficits occasionally were suspected. In many instances, the disease was interrupted or terminated by secondary complications,



FIGURE 1. Female mule deer, 3 years of age, with late clinical signs of chronic wasting disease. Excess salivation, depression and emaciation are present.

[□] Mice (*Peromyscus* sp., *Mus musculus*), rabbit (*Lepus* sp., *Sylvilagus* sp.), raccoon (*Procyon lotor*), skunk (*Mephitis mephitis*), several species of ground squirrel (*Citellus* spp.), dogs and cats.

notably pneumonia, or by euthanasia. A summary of clinical signs is presented in Table 1.

CLINICAL PATHOLOGY

Blood samples in EDTA were obtained from 11 affected deer for hematologic evaluation and serum from 10 deer for chemistry and electrolyte levels prior to death. Deer were restrained manually or sedated with xylazine hydrochloride[Ⓜ] during sample collection. Samples usually were analyzed within 24 h of collection. Erythrocyte and white blood cell counts were performed on a Coulter Counter.[Ⓜ] Hemoglobin content was determined using a Coulter hemoglobinometer.[Ⓜ] A Hycel-17 autoanalyzer[Ⓜ] was used for analysis of blood urea nitrogen (BUN), creatinine, cholesterol, bilirubin, sodium, inorganic phosphorus, chloride, potassium, creatinine phosphokinase (CPK), serum glutamic oxaloacetic transaminase (SGOT) and alkaline phosphatase. Data are shown in Tables 2 and 3. Alterations from normal values were noted only in deer in which secondary intercurrent disease existed, however consistent changes were not identified.

Cerebrospinal fluid (CSF) was collected from five affected deer immediately following electrocution. Cell counts, protein content, specific gravity, pH, and CPK levels (Biodynamics[Ⓜ] enzymatic U-V method) were determined within 24 h (Table 4). CPK values ranged from 16-102 U/l which are elevated from normal levels; however, in these cases the elevation was felt to be due to the method of euthanasia.¹

Urinalysis was performed on urine collected from the bladder of 6 deer at necropsy. Urine specific gravity ranged from 1.002 to 1.018 with 3 values below 1.006. These levels were lower than expected and considered significantly decreased in animals which were mildly to moderately dehydrated.

Sera from 1 to 5 affected deer were tested for antibody titers to *Toxoplasma* (indirect hemagglutination), *Leptospira* (slide agglutination), *Brucella abortus* (slide agglutination), infectious bovine rhinotracheitis virus (serum neutralization), bovine virus diarrhea virus (serum neutralization) and blue-tongue virus (immunodiffusion).[Ⓜ] All reactions were judged to be insignificant except for two deer with titers of 1:16 and 1:64 to bovine virus diarrhea virus.

Samples of liver and kidney from two deer were analyzed by atomic absorption spectrometry for selenium, lead, copper, mercury and molybdenum.[Ⓜ] Levels were considered to be within normal limits.

GROSS PATHOLOGY

Since 1974, 41 mule deer affected with CWD have been examined post-mortem. Gross pathologic findings consistently included emaciation and in 28 (68%) the rumen contained a marked excess of fluid admixed with sand or gravel. In 18 (44%) no gross lesion was found, while in 23 (56%) various other inconsistent gross lesions were observed and presumed to be the non-specific result of secondary disease processes. These included pneumonia, abscesses, enteritis, focal

[Ⓜ] Rompun, Haver Lockhart, Shawnee, Kansas, USA.

[Ⓜ] Coulter Electronics Inc., Hialeah, Florida, USA.

[Ⓜ] Hycel Inc., Houston, Texas, USA.

[Ⓜ] Biodynamics, Inc., Indianapolis, Indiana, USA.

[Ⓜ] Tests were performed by the Colorado State University Veterinary Diagnostic Laboratory.

[Ⓜ] Selenium (dry weight) - kidney 2.9 and 0.2 ppm, liver 1.3 and 0.8 ppm, lead (wet weight) - less than 8 ppm kidney and 2 ppm liver, copper (dry weight) - liver 14.4 and 19.7 ppm, mercury (wet weight) - less than 1 ppm, molybdenum (dry weight) - liver 3.3 and 3.3 ppm.

TABLE 1. Summary of clinical features and gross pathologic findings in deer with histopathologically confirmed CWD.

Sex	Duration of Clinical Signs (months)	Clinical Features							Gross Pathologic Findings		
		Emaciation	Behavioral Changes	Polydipsia/Polyuria	Excessive Salivation	Grinding of Teeth	Esophageal Dilatation	Regurgitation of Rumen Contents	Increased Rumen Fluid	Rumen Sand and Gravel	Significant Intercurrent Pathology
Female	0.5-6	100% (17/17)	100% (17/17)	77% (10/13)	50% (7/14)	58% (7/12)	13% (2/16)	15% (2/13)	59% (10/17)	59% (10/17)	35% (6/17)
Male	1-8	100% (5/5)	100% (5/5)	100% (3/3)	50% (1/2)	0% (0/2)	20% (1/5)	0% (0/5)	100% (5/5)	60% (3/5)	60% (3/5)
Castrates	0.5-8	100% (7/7)	100% (7/7)	71% (5/7)	80% (4/5)	75% (3/4)	0% (0/4)	0% (0/7)	100% (4/4)	25% (1/4)	43% (3/7)
Total	0.5-8	100% (29/29)	100% (29/29)	78% (18/23)	57% (12/21)	56% (10/18)	12% (3/25)	8% (2/25)	73% (19/26)	54% (14/26)	41% (12/29)

^aFractions refer to the number of deer showing a particular feature over the number of animals which were examined for that feature.

TABLE 2. Hematologic values for mule deer with histopathologically confirmed CWD.

Deer number	Date of Sample Collection	Age (years)	Sex ^a	PCV%	Hb g/dl	Serum Protein g/dl	WBC's per mm ³	Neutrophils	Lymphocytes	Monocytes	Eosinophils	Basophils	Significant Intercurrent Pathology
77W577	5/4/77	3.0	CM	38	13.6	6.5	2,300	70	24	4	1	1	None
78W23	2/18/78	3.7	F	37	12.6	6.0	3,200	69	26	2	1	1	Typhilitis
78W68	5/14/78	3.0	CM	53	17.6	8.4	7,000	70 ^b	24	6	0	0	Bronchopneumonia
78W180	10/12/78	3.3	CM	12 ^{c,d}	4.0 ^c	6.2	18,000	81	18	1	0	0	Suppurative arthritis
79W93	2/26/79	3.7	F	35	12.6	5.9	3,900	52	46	2	0	0	Aspiration pneumonia
79W193	3/5/79	3.8	F	37	14.4	8.5	14,000	82	14	2	1	0	Multiple abscesses
79W200	3/9/79	3.8	F	40	15.4	7.2	5,800	81	13	4	2	0	None
79W203	3/13/79	2.8	CM	59	22	7.0	8,000	83	17	0	0	0	Enteritis
79W238	5/4/79	2.9	F	43	18	5.9	7,100	72	28	0	0	0	None
79W258	5/16/79	4.0	F	37	12.6	5.7	40,600 ^c	73	26	1	0	0	Abomasal ulcer
79W314	8/17/79	3.1	F	31	10.8	5.1	3,400	70	28	2	0	0	None
	Mean	3.4		41	15.0	6.6	7,300	73	24	2.2	0.5	0.2	
	Range	2.8-4.0		31-59	10.8-22	5.1-8.5	2,300-40,600	52-83	13-46	0-6	0-2	0-1	

^aF=female, CM=castrated male^b23% immature neutrophils^cexcluded from mean calculations^dregenerative anemia

TABLE 3. Serum chemistry and electrolyte profile of mule deer with histopathologically confirmed CWD.

Deer number	BUN g/dl	Globulin g/dl	Cholesterol mg/dl	Total bilirubin mg/dl	Creatinine mg/dl	Alk. phos. U ^a /l	SGOT U ^a /l	CPK U ^a /l	Inorganic phosphorous mg/dl	Calcium mg/dl	Chloride meq/dl	Sodium meq/dl	Potassium meq/dl	Significant Intercurrent Pathology
77W577	23	4.2	70	0.2	1.6	5	100	156	5.5	9.4	106	144	5.3	None
78W32	18	3.4	57	0.4	1.7	8	100	48	6.2	9.4	100	143	4.5	Bronchopneumonia
78W68	115	5.4	100	0.8	4.2	18	160	ND ^b	11.0	10.0	100	146	5.4	Bronchopneumonia
78W180	18	4.1	50	0.6	1.0	12	190	ND	7.2	7.5	104	142	3.7	Suppurative arthritis
79W193	16	5.1	50	0.2	2.2	12	130	44	8.8	8.8	107	142	5.6	Multiple abscesses
79W200	36	4.0	50	0.3	1.8	11	80	34	2.7	10.6	116	144	4.6	None
79W203	44	4.9	50	0.6	2.2	38	1420	147	7.6	9.4	110	147	9.0	Enteritis
79W238	53	3.1	40	0.3	1.8	5	160	280	9.2	8.2	103	143	4.6	None
79W256	47	2.9	50	0.2	2.2	7	150	150	5.8	9.4	100	143	7.2	Abomasal ulcer
79W314	70	3.1	35	0.4	1.8	13	140	59	6.4	7.6	113	145	5.0	None
Mean	44	4.0	55	0.4	2.0	12.9	261	114	7.0	9.0	106	144	5.5	
Range	16-115	2.9-5.4	35-100	0.2-0.8	1.0-4.2	5-38	60-1420	34-280	2.7-11.0	7.5-10.6	100-116	142-147	3.7-9.0	

^aInternational units^bND = Not determined

alopecia and external or internal parasitism (Table 1).

HISTOPATHOLOGY

An extensive selection of formalin-fixed tissues examined by light microscopy of hematoxylin-eosin stained sections from 41 affected deer did not result in identification of consistent pathologic changes in extra-neural organs or systems. Brain or other tissues of the central nervous system (CNS) were removed from 29 of these cases and fixed in neutral buffered 10% formalin solution or in formalin-ammonium bromide (FAB). Tissue sections representing various regions of the CNS were processed for paraffin embedment, sectioned at 6-7 μ m and stained with hematoxylin-eosin, periodic acid-Schiff, luxol fast blue-cresyl echt violet, oil red-O, Holzer's or Weil-Weigert methods. Selected FAB-fixed tissues were sectioned at 15-20 μ m on a freezing microtome and stained by the Ramon Y Cajal's gold sublimate method⁷ for astrocytes.

Neurohistopathologic changes were characterized by widespread microcavitation or spongiform transformation of the neuropil, predominantly of gray matter (Fig. 2), single or multiple intracytoplasmic vacuoles in neuronal perikaryons (Fig. 3) and by neuronal degeneration. Spongiform change of varying severity was found in the gray matter of spinal cord, medulla oblongata, pons, mesencephalon, thalamus, hypothalamus and cerebellar cortex. Focal lesions occurred in cerebral cortex, particularly in olfactory regions of the frontal lobes. Specific nuclei of thalamus, mesencephalon and medulla oblongata were consistently and severely affected. In such areas, astrocytic hypertrophy and fibrillary hyperplasia were demonstrable in gold sublimate stained sections (Fig. 4). These were matched for comparison with identical regions of the brains of unaffected mule deer of similar age in which these changes were absent.

TABLE 4. Cerebrospinal fluid (CSF) values for mule deer with histopathologically confirmed CWD^a.

Deer number	Color	Appearance	Specific gravity	pH	Total protein (mg)	Cells
77W577	Colorless	Clear	1.005	6.5	22	8 lymphs
79W200	Slightly bloody	Clear	1.008	8.0	ND ^b	10 cells
79W238	Colorless	Clear	1.005	7.0	10	1 lymph
79W258	Slightly bloody	Clear	1.006	8.0	113	3 monocytes
79W314	Colorless	Clear	1.006	8.0	27	No cells
						No inflammatory cells

^aCSF sample taken immediately following euthanasia by electrocution

^bND = not determined

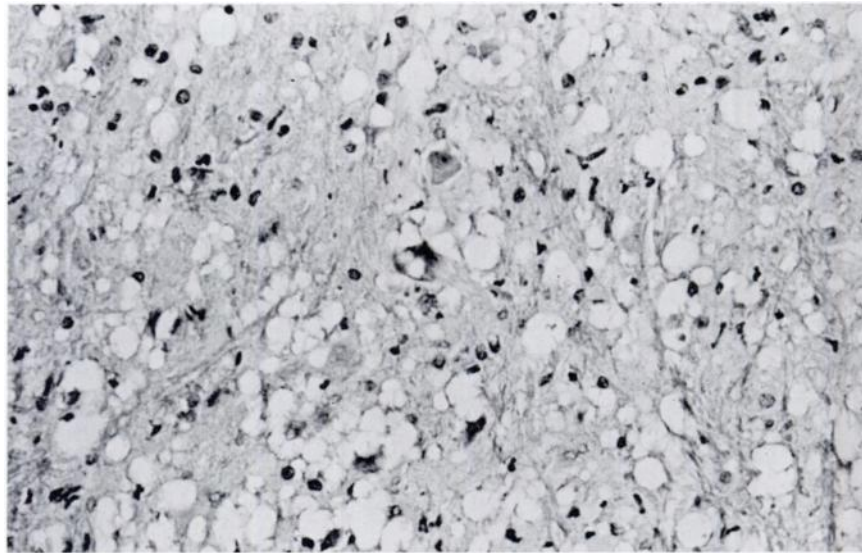


FIGURE 2. Diffuse spongiform change in neuropil of dorsal motor nucleus of vagus ($\times 63$, 7 μm section, HE).

CNS tissues of 27 captive or free-ranging mule deer from 1 to 8 years of age and unaffected clinically with CWD were examined microscopically. These deer included normal animals, deer affected with a variety of other disease conditions and six deer emaciated as a result of malnutrition imposed by severe winter conditions. In none of these CNS tissues was spongiform change or multiple neuronal vacuolation discovered and on this basis the CNS lesion of spongiform encephalopathy was considered specific for CWD.

DISCUSSION

Morbidity and mortality from CWD have not been accurately recorded among mule deer in these facilities during the period 1967-74. From 1974-79 when accurate records are available, 54 (80%) of a total population of 67 mule deer and black-tailed deer held or presently in captivity for more than 2 years have shown typical clinical features of CWD

and died or were euthanatized as a consequence of the disease.

The only alteration in clinical pathologic values for deer affected with CWD which we consider significant is low urine specific gravity. Degenerative encephalopathic changes are consistently identified in the hypothalamus, which is important in the regulation of antidiuretic hormone,⁵ and may be responsible for the diabetes insipidus-like clinical syndrome.

The insidious onset, protracted clinical course, fatal outcome and characteristic encephalopathic features of CWD of mule deer are qualitatively comparable to other established spongiform encephalopathies of animals and man. Spontaneously occurring diseases of this group include scrapie of sheep and goats, transmissible encephalopathy of mink, and kuru and Creutzfeld-Jakob disease of man.^{5,7} These represent widely acknowledged and demonstrably transmissible examples of "slow virus" infections which result in classical

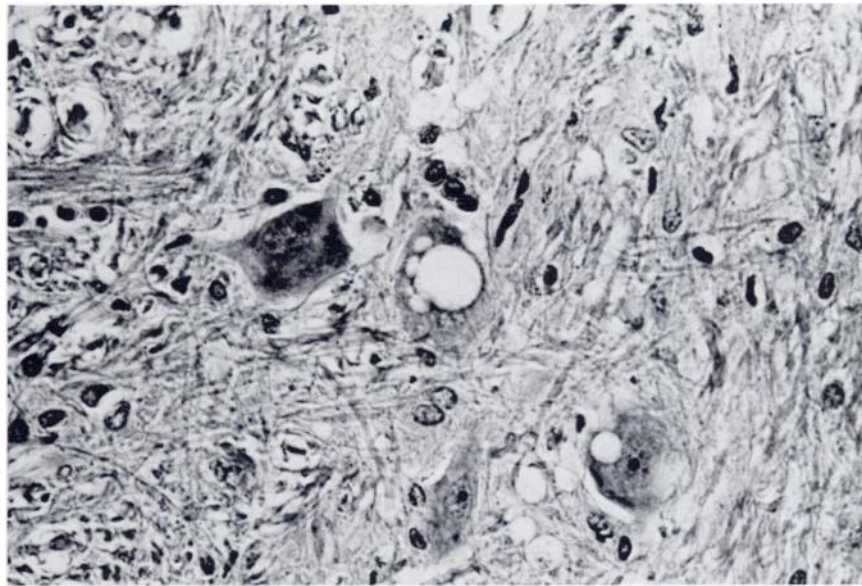


FIGURE 3. Intracytoplasmic vacuolation of neuronal perikaryons in the pons ($\times 100$, 7 μm section, HE).

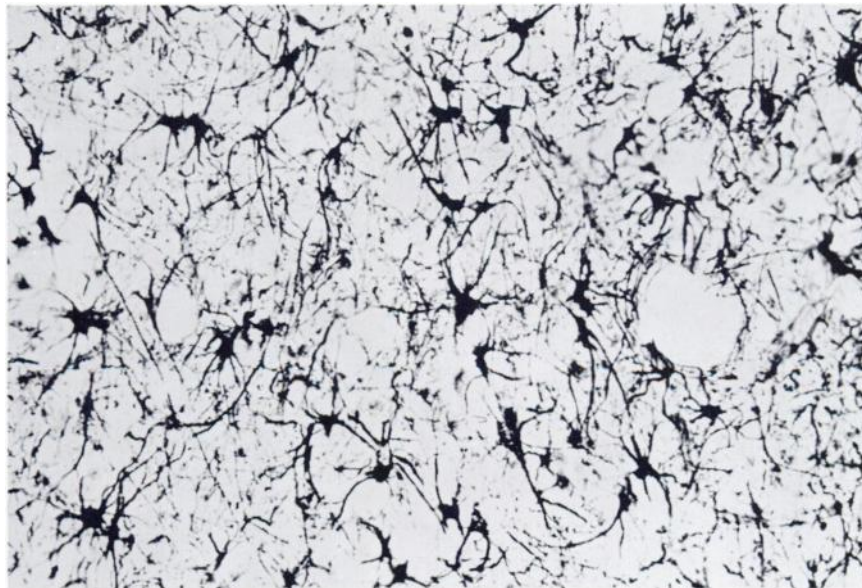


FIGURE 4. Astrocytic hypertrophy and fibrillary hyperplasia ($\times 160$, 15 μm frozen section, Cajal's gold chloride impregnation).

spongiform encephalopathy. Recently a neurotropic retrovirus has been identified in wild mice which is associated with similar noninflammatory spongiform polio encephalopathy.^{2,3,8}

Currently, studies are underway to characterize fully the clinical and pathologic features of CWD of mule deer, and to determine its epizootiology and transmissibility.

Acknowledgements

We thank P.H. Neil, A.W. Alldredge, E.T. Thorne, C.P. Hibler, M.W. Fischer and members of the Wild Animal Disease Center and Department of Pathology, Colorado State University for assistance and case material.

LITERATURE CITED

1. AIRD, R.B., L.A. STRAIT, J.W. PACE, M.K. HRENOFF and S.C. BOWDITCH. 1956. Neurophysiologic effects of electrically induced convulsions. *Am. Med. Assoc. Arch. Neurol. Psych.* 75: 371-378.
2. BROOKS, B.R., J.R. SWARZ, O. NARAYAN and R.T. JOHNSON. 1979. Murine neurotropic retrovirus spongiform polioencephalomyelopathy: Acceleration of disease by virus inoculum concentration. *Infect. and Immun.* 23: 540-544.
3. GARDNER, M.B. 1978. Type C viruses of wild mice: characterization and natural history of amphotropic, ecotropic, and xenotropic MuLV. *Current Top. Microbiol. Immunol.* 79: 215-239.
4. GIBBS, C.J. and D.C. GAJDUSEK. 1978. Atypical viruses as the cause of sporadic, epidemic, and familial chronic diseases in man: slow viruses and human diseases. *Perspect. in Virol.* 10: 161-194.
5. GUYTON, A.C. 1971. *Textbook of Medical Physiology*, 4th edition, p. 883. W.B. Saunders Company, Philadelphia. 1032 pp.
6. KIMBERLIN, R.H. (ed). 1976. *Slow Virus Diseases of Animals and Man*, Part IV, pp. 209-378. American Elsevier, New York. 404 pp.
7. LILLIE, R.D. and H.M. FULLMER. 1976. *Histopathologic Technique and Practical Histochemistry*, 4th edition, McGraw-Hill Book Company. 942 pp.
8. OLDSTONE, M.B.A., P.W. LAMPERT, S. LEE and F.J. DIXON. 1977. Pathogenesis of the slow disease of the central nervous system associated with VM 1504E virus. *Am. J. Pathol.* 88: 193-212.

Received for publication 11 September 1979