



## **EPIZOOTIOLOGY AND HISTOPATHOLOGY OF *Chloromyxum trijugum* (MYXOSPORA: MYXOSPORIDA) IN CENTRARCHID FISHES FROM IOWA**

Authors: MITCHELL, LAWRENCE G., LISTEBARGER, JAMES K., and  
BAILEY, WAYNE C.

Source: Journal of Wildlife Diseases, 16(2) : 233-236

Published By: Wildlife Disease Association

URL: <https://doi.org/10.7589/0090-3558-16.2.233>

---

The BioOne Digital Library (<https://bioone.org/>) provides worldwide distribution for more than 580 journals and eBooks from BioOne's community of over 150 nonprofit societies, research institutions, and university presses in the biological, ecological, and environmental sciences. The BioOne Digital Library encompasses the flagship aggregation BioOne Complete (<https://bioone.org/subscribe>), the BioOne Complete Archive (<https://bioone.org/archive>), and the BioOne eBooks program offerings ESA eBook Collection (<https://bioone.org/esa-ebooks>) and CSIRO Publishing BioSelect Collection (<https://bioone.org/csiro-ebooks>).

Your use of this PDF, the BioOne Digital Library, and all posted and associated content indicates your acceptance of BioOne's Terms of Use, available at [www.bioone.org/terms-of-use](http://www.bioone.org/terms-of-use).

Usage of BioOne Digital Library content is strictly limited to personal, educational, and non-commercial use. Commercial inquiries or rights and permissions requests should be directed to the individual publisher as copyright holder.

---

BioOne is an innovative nonprofit that sees sustainable scholarly publishing as an inherently collaborative enterprise connecting authors, nonprofit publishers, academic institutions, research libraries, and research funders in the common goal of maximizing access to critical research.

## EPIZOOTIOLOGY AND HISTOPATHOLOGY OF *Chloromyxum trijugum* (MYXOSPORA: MYXOSPORIDA) IN CENTRARCHID FISHES FROM IOWA

LAWRENCE G. MITCHELL, JAMES K. LISTEBARGER and WAYNE C. BAILEY, Department of Zoology, Iowa State University, Ames, Iowa 50011, USA.

**Abstract:** The gall bladder parasite, *Chloromyxum trijugum*, shows marked host specificity within the sunfish family Centrarchidae. During 1977-78 80% of 230 bluegills (*Lepomis macrochirus*) in Iowa were infected. Prevalence in green sunfish (*L. cyanellus*) was lower (17%); one of 2 specimens of the hybrid *L. macrochirus* × *L. cyanellus* was infected; orangespotted sunfish (*L. humilis*) and hybrids (*L. humilis* × *L. macrochirus*) were not infected. Intensity of infection in bluegills varied throughout the year. Prevalence of free-floating plasmodia in bluegill gall bladders was highest (100%) during winter and spring months, and decreased to 40-50% during summer and fall. Prevalence of attached plasmodia may remain 80-100% throughout the year. Sporulation and plasmatomy were observed year-round. Plasmodia were attached to underlying epithelial cells by pseudopodia-like projections and were associated with various stages of breakdown in the mucosal layer.

### INTRODUCTION

*Chloromyxum trijugum* Kudo, 1919, first described from the longear sunfish (*Lepomis megalotis*) in Illinois, USA, has since been reported from five other species of the sunfish family Centrarchidae; the bluegill (*Lepomis macrochirus*) is commonly infected in Iowa.<sup>1-5</sup> Plasmodia of this myxosporidan are free-floating in bile and/or attached to the gall bladder mucosa. No host pathology has been described to date.

### MATERIALS AND METHODS

Fishes were obtained by angling, netting and electrofishing from impoundments in central Iowa and from earthen ponds at the Iowa Conservation Commission hatchery, Fairport, Iowa in Muscatine County during 1977-78. Gall bladders were examined from specimens killed within 24 h after capture. Samples of bile were examined microscopically to determine presence of free-floating stages of *C. trijugum*. Gall bladders of 20 adult bluegills were fixed in Bouin's solution, sectioned at 5-8  $\mu$ m and stained

with hematoxylin-eosin or Mallory's triple connective tissue stain for histopathology. Samples of bladder walls were also fixed in 3% buffered (pH 7.2) glutaraldehyde overnight, 1% buffered OsO<sub>4</sub> (pH 7.2) for 2 h, dehydrated, and embedded in Epon 812. Sections were cut at 1-2  $\mu$ m, stained with azure II/methylene blue, and examined with the aid of phase contrast microscopy.

### RESULTS AND DISCUSSION

#### Epizootiology

A total of 184 of 230 (80%) bluegills examined during 1977-78 was infected with *C. trijugum*. Only 4 of 24 specimens of green sunfish (*L. cyanellus*) were found infected; none of 20 orangespotted sunfish (*L. humilis*) were infected. Both of these sunfish may hybridize with the bluegill, and frequently cohabit ponds and lakes with bluegills. All orangespotted sunfish were taken from Iowa hatchery ponds which also contained infected bluegills. One of two feral specimens of the hybrid *L. macrochirus*

× *L. cyanellus* was found infected. Ten specimens of *L. macrochirus* × *L. humilis* from Fairport hatchery ponds were not infected.

Although several species of *Lepomis* (sunfishes) and *Pomoxis* (crappies) harbor infections, *C. trijugum* seems to be specific to certain species of these genera.<sup>1-5</sup> Our results are further indication that this myxosporidan shows marked host specificity within the family Centrarchidae.

Prevalence of *C. trijugum* in Iowa bluegills as indicated by free-floating plasmodial stages remained at 100% during winter and early spring of both years (Fig. 1). The apparent decrease in prevalence of infection from late spring into autumn may reflect active host feeding and consequent regular emptying of the gall bladder during warmer seasons. However, histopathologic sections indicate that prevalence of infection by attached plasmodia may remain near 80-100% throughout the year. Gall bladder sections obtained from 19 of 20

bluegills collected during all seasons contained attached plasmodia. Seasonal temperature changes may also directly influence *C. trijugum* although intensity of infection by free-floating and attached stages varied throughout all seasons. Sporulation occurred year-round, although macroscopic plasmodia containing daughter plasmodia (Fig. 2) were seen only in the spring (March-May). Plasmotomy was observed throughout the year.

### Histopathology

In 10 representative sections of whole gall bladders from 5 bluegills, plasmodia completely covered the mucosal surface. Attachment was by fine pseudopodia-like projections (Fig. 3). The free surfaces of attached plasmodia were covered with fine villusities (Fig. 3) suggesting that nutrients may be absorbed from the bile. Uspenskaya<sup>6</sup> indicated that nutrient absorption occurs across free surfaces of attached plasmodia of *Myxidium lieberkeuhni* in pike urinary bladders.

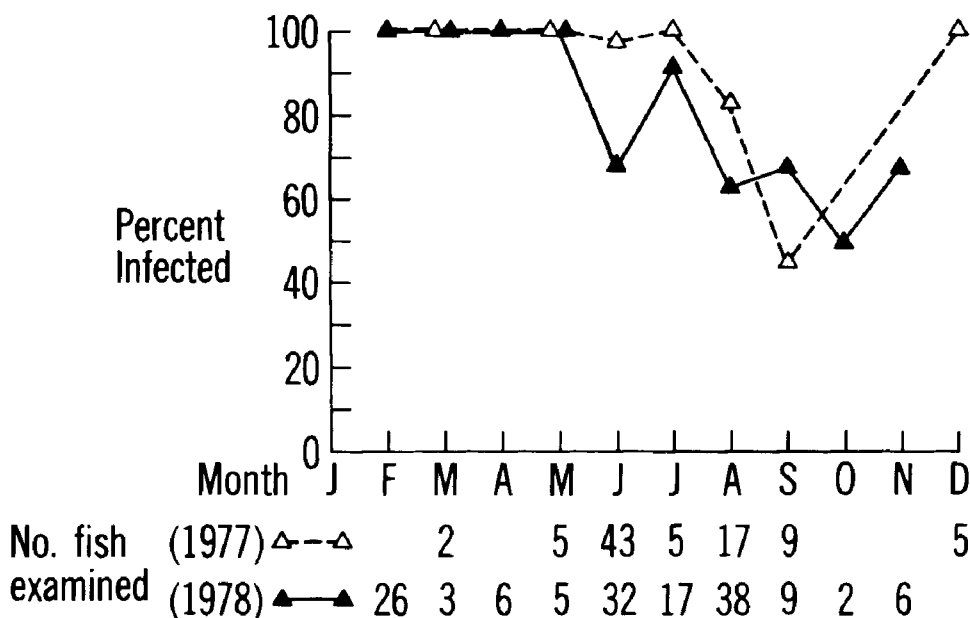


FIGURE 1. Seasonal Prevalence of *Chloromyxum trijugum* in Bluegills in Central Iowa during 1977-78 (free floating plasmodia in gall bladders).

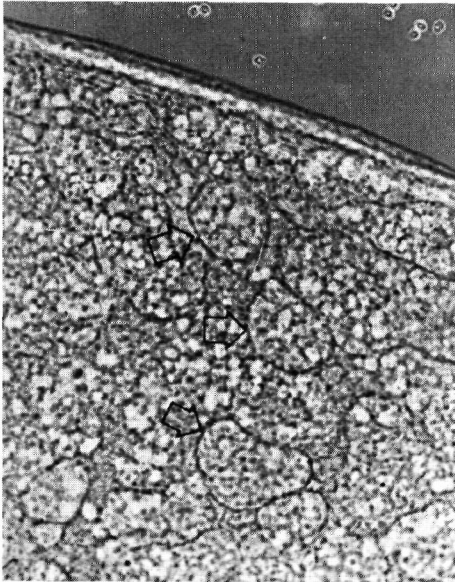


FIGURE 2. Portion of large free-floating plasmodium containing sporulating daughter plasmodia (arrows) from gall bladder of bluegill. Free spores (SP) in gall bladder lumen. Unstained  $\times 160$ .

Attached plasmodia of *C. trijugum* were associated with various stages in breakdown of the gall bladder mucosa. Compared with uninfected mucosal cells, those coated with plasmodia showed indistinct boundaries, loss of nuclear detail and general reduction in height. Vacuoles were common between infected mucosa and underlying connective tissue. Four heavily infected bladders contained plasmodia attached to desquamate submucosa (Fig. 4). The submucosa of these heavily infected bladders appeared thickened and contained aggregations of leucocytes not seen in other bladders.

The function of the gall bladder in fishes has not been extensively studied. Presumably, as in other vertebrates, gall bladder epithelial cells in centrarchid fishes are active in bile concentration. Desquamation of the bladder would preclude this function. Electron microscope studies of gall bladder pathology associated with this myxosporidan are in progress.

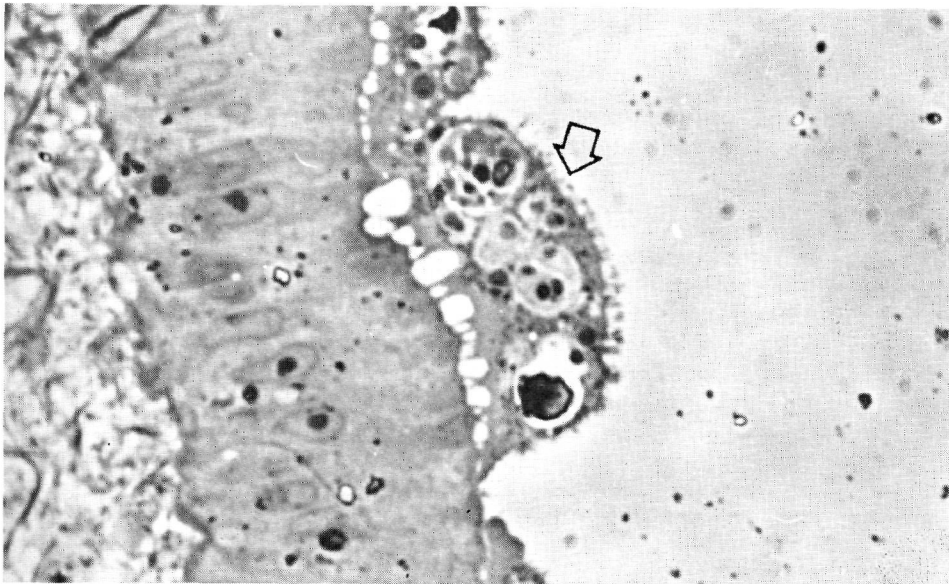


FIGURE 3. Sporulating plasmodia attached by pseudopodia-like projections to gall bladder mucosa of bluegill. Free surface of plasmodia covered with fine villusities (arrow). Azure II/methylene blue  $\times 950$ .

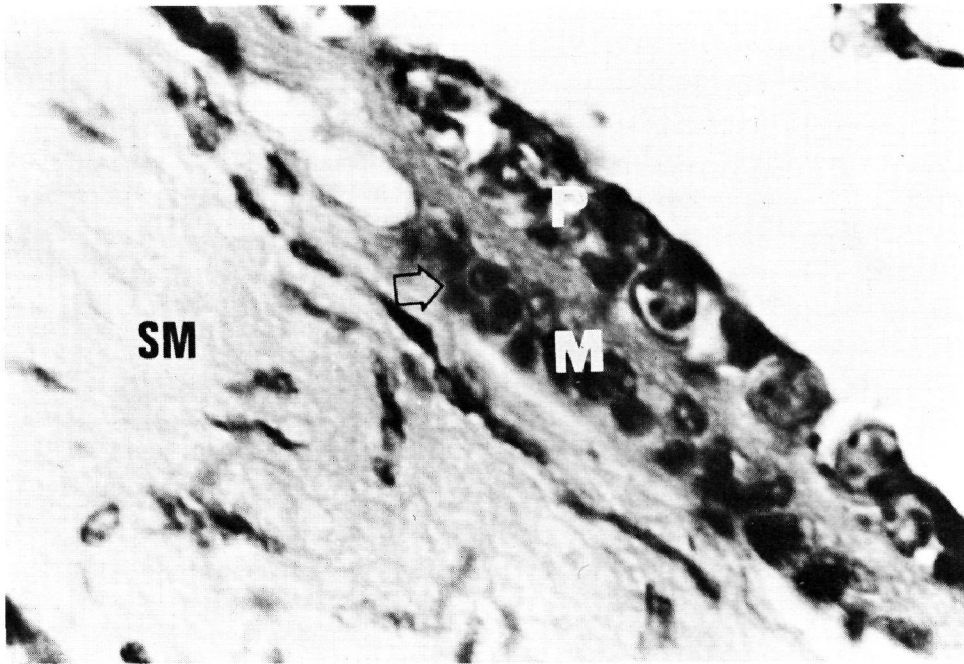


FIGURE 4. Elongate sporulating plasmodium (P) attached to desquamate gall bladder wall of bluegill. Remains of mucosal layer (M) appears as vacuolated connective tissue surrounding remains of mucosal nuclei (arrow). Connective tissue in mucosal zone appears continuous with submucosa (SM). H&E  $\times 950$ .

#### LITERATURE CITED

1. KUDO, R.R. 1919. Studies on Myxosporidia. A synopsis of genera and species. Ill. Biol. Monographs 5: 1-265.
2. ———. 1920. Cnidosporidia in the vicinity of Urbana. Trans. Ill. State Acad. Sci. 18: 298-303.
3. MEGLITSCH, P.A. 1937. On some new and known Myxosporidia of the fishes of Illinois. J. Parasitol. 23: 467-77.
4. MITCHELL, L.G. 1978a. Myxosporidan infections in some fishes of Iowa. J. Protozool. 25: 100-105.
5. ———. 1978b. Coelozoic Myxosporida of fishes of western Montana: genus *Chloromyxum*. Northwest Science 52: 236-242.
6. USPENSKAYA, A.V. 1966. On the mode of nutrition of vegetative stages of *Myxidium lieberkeuhni* (Bütschli) (in Russian). Acta Protozool. 4: 81-88.

*Received for publication 20 April 1979*