



## **EXPERIMENTAL TRANSMISSION OF BOVINE MALIGNANT CATARRHAL FEVER TO A BISON (Bison bison) 1**

Authors: LIGGITT, H. D., McCHESNEY, A. E., and DeMARTINI, J. C.

Source: Journal of Wildlife Diseases, 16(2) : 299-304

Published By: Wildlife Disease Association

URL: <https://doi.org/10.7589/0090-3558-16.2.299>

---

The BioOne Digital Library (<https://bioone.org/>) provides worldwide distribution for more than 580 journals and eBooks from BioOne's community of over 150 nonprofit societies, research institutions, and university presses in the biological, ecological, and environmental sciences. The BioOne Digital Library encompasses the flagship aggregation BioOne Complete (<https://bioone.org/subscribe>), the BioOne Complete Archive (<https://bioone.org/archive>), and the BioOne eBooks program offerings ESA eBook Collection (<https://bioone.org/esa-ebooks>) and CSIRO Publishing BioSelect Collection (<https://bioone.org/csiro-ebooks>).

Your use of this PDF, the BioOne Digital Library, and all posted and associated content indicates your acceptance of BioOne's Terms of Use, available at [www.bioone.org/terms-of-use](http://www.bioone.org/terms-of-use).

Usage of BioOne Digital Library content is strictly limited to personal, educational, and non-commercial use. Commercial inquiries or rights and permissions requests should be directed to the individual publisher as copyright holder.

---

BioOne is an innovative nonprofit that sees sustainable scholarly publishing as an inherently collaborative enterprise connecting authors, nonprofit publishers, academic institutions, research libraries, and research funders in the common goal of maximizing access to critical research.

## EXPERIMENTAL TRANSMISSION OF BOVINE MALIGNANT CATARRHAL FEVER TO A BISON (*Bison bison*)<sup>1</sup>

H. D. LIGGITT,<sup>2</sup> A. E. McCHESNEY<sup>3</sup> and J. C. DeMARTINI<sup>3</sup>

**Abstract:** Malignant catarrhal fever (MCF) was transmitted to a bison (*Bison bison*) by intravenous inoculation of whole blood obtained from a calf showing signs of experimental MCF. Clinical signs evident on the 25th day following inoculation included depression, weakness, epiphora, serous nasal discharge, watery diarrhea and multifocal ulcerations of oral mucosa. Gross and histopathological lesions observed in the bison were similar to those in cattle with a few qualitative differences. Compared to bovine cases, MCF in bison was characterized by more severe edema, congestion, and hemorrhage and accumulation of fewer lymphoid cells in lesions.

### INTRODUCTION

Epizootics of malignant catarrhal fever (MCF) in American bison (*Bison bison*) are being increasingly recognized. Recently Ruth *et al.*<sup>7</sup> reported three epizootics in South Dakota in which 6.9% (23/333) of the bison were affected and died. Members of our group have investigated epizootics in Colorado and Wyoming in which 9.8% (66/670) of the bison were affected and died.<sup>8</sup> Similar losses have been reported in cattle<sup>5</sup> and in captive deer.<sup>1,6</sup> Such losses arouse much concern, especially since an understanding of the pathogenesis, epidemiology and control of North American MCF is lacking. Because little is known of the biological behavior of North American MCF we were interested to see if the bovine form of the disease could be experimentally transmitted to a bison and, if so, if its pathological expression was altered. This investigation was

facilitated by the fact that we were concurrently performing experimental transmissions of MCF among cattle.<sup>2</sup>

### MATERIALS AND METHODS

Procedures used for the experimental transmission of MCF have been reported.<sup>2</sup> Briefly, 500 ml of whole blood from a second passage calf with early signs of experimental MCF was collected into acid-citrate-dextrose solution and within 2 h transferred intravenously into a bison. This bison was an approximately 1.5-year-old female which was clinically normal except for functional blindness due to severe bilateral, congenital, microphthalmia. The bison was housed separately from experimental cattle. Following inoculation it was examined daily for clinical signs, but its disposition would not allow routine handling. Necropsy was performed within 2 h

<sup>1</sup> Work performed in the Department of Pathology, College of Veterinary Medicine and Biomedical Sciences, Colorado State University, Ft. Collins, Colorado 80523 and supported in part by Grant No. 12-14-3001-563 from the U.S. Department of Agriculture and National Institutes of Health, Biomedical Sciences Research Support Grant No. 5-507 RR05485-15.

<sup>2</sup> Department of Veterinary Microbiology and Pathology, Washington State University, Pullman, Washington 99164, USA.

<sup>3</sup> Department of Pathology, College of Veterinary Medicine and Biomedical Sciences, Colorado State University, Ft. Collins, Colorado 80523, USA.

<sup>8</sup> Pierson, R. E., A. E. McChesney, J. C. DeMartini and H. D. Liggitt: MCF in Colorado and Wyoming Bison. College of Veterinary Medicine and Biomedical Sciences, Colorado State University, Fort Collins, Colorado 80523: Unpublished data, 1978.

following death. Tissues were fixed in 10% neutral buffered formalin, embedded in paraffin, sectioned at 6-10 $\mu$ m, and stained with hematoxylin and eosin.

## GROSS PATHOLOGY

Twenty-four days following inoculation with blood from a calf with MCF, the bison was anorectic and slightly depressed but otherwise appeared normal. The following day the animal was extremely depressed and weak and was showing epiphora, serous nasal discharge, profuse watery diarrhea, frequent blood tinged urination, mild to moderate multifocal ulceration of the gingiva and oral papillae, and a temperature of 40.0 C. Death occurred following a struggle associated with obtaining blood samples. Transmission, using whole blood, back to a calf was attempted but clinical disease never developed.

At necropsy the animal appeared well nourished and the only evidence of concurrent disease was severe bilateral congenital microphthalmia and chronic pneumonia localized in the anterior-ventral portions of the apical lung lobes. Other lesions were assumed to be associated with experimental MCF. On examination nasal turbinates were moderately reddish with small amounts of fibrin adherent to the surface. The tracheal mucosa was red-black and a few small, irregular erosions were scattered throughout. Lungs were reddish-tan and slightly wet. There were multiple shallow, punctuate to linear, ulcerations and erosions of the gingiva, oral papillae, hard and soft palates, oral pharynx, lateral tongue and esophagus. Scattered throughout the rumen, reticulum and omasum were large foci of red-black papillae, the tips of which were adherent in small clumps. The abomasum had several large, red, coalescing foci which contained a few small, irregular ulcerations. The intestinal tract was diffusely reddened and Peyer's patches

were prominent but erosions were not recognized. Intestinal contents were semi-solid to fluid and contained very small quantities of free blood. The slightly yellowish liver had an accentuated reticular pattern. Kidneys had many 1-8 mm in diameter raised, white, foci scattered throughout the cortical parenchyma. The urinary bladder mucosa had multiple focal and focal confluent red-black areas but there were no erosions. All lymph nodes examined were moderately to markedly enlarged and a few were mottled red and wet.

## HISTOPATHOLOGY

Histologically, vascular lesions were present in most organs examined, including the brain, rete mirabile, choroid plexus, spinal cord, oral cavity, trachea, lung, esophagus, gastrointestinal tract, liver, kidneys, urinary bladder, spleen, and lymph nodes. Lesions affected veins as well as arteries and ranged from mild perivascular cuffing to marked accumulation of inflammatory cells in adventitial, intimal and medial locations, sometimes accompanied by vascular wall necrosis (Fig. 1). Inflammatory cells were predominantly lymphoid with few neutrophils and plasma cells. While the range of severity of vascular lesions was wide the most common changes were perivascular cuffing, mild, medial lympho-infiltrative changes and, in some sites such as gastrointestinal tract, lymph nodes, and trachea, severe congestion with occasional hemorrhage. Vascular thrombi were infrequent.

Individual and coalescing focal epithelial lesions of the oral cavity, gastrointestinal tract, respiratory tract, urinary tract and choroid plexus had variable degrees of epithelial cell degeneration, necrosis and sloughing with mild to moderate accumulation of lymphoid cells in epithelial and sub-epithelial tissues. Lesions involving stratified squamous epithelium were

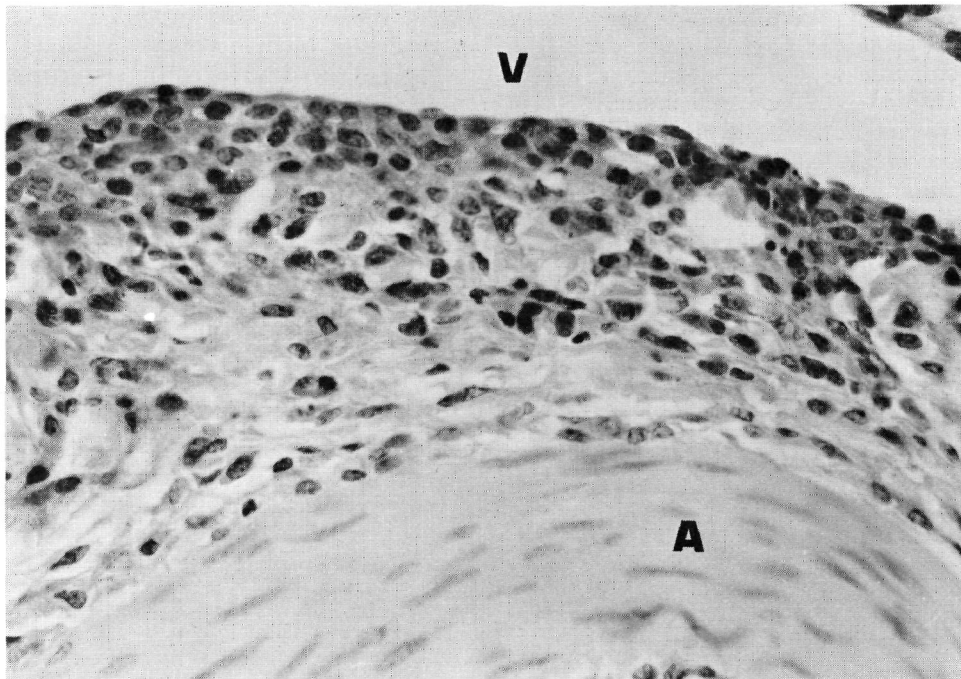


FIGURE 1. Accumulation of lymphoid cells within the adventitia common to a rete mirabile artery (A) and venous sinus (V). H&E  $\times 160$ .

moderately to markedly edematous and occasionally contained acantholytic vesicles. Some of these lesions had moderate numbers of neutrophils within or on the surface of the epithelium. Focal sloughing of epithelium was common in respiratory, gastrointestinal, urinary tract, and choroid plexus lesions and was usually associated with variable accumulations of lymphoid cells, vascular congestion and occasionally hemorrhage. The principal liver lesion was accumulation of lymphoid cells within and surrounding portal triads. Such triads had typical vascular lesions and, on occasion, focal areas of bile duct epithelial cell necrosis and sloughing. In the kidney large, dense, accumulations of lymphoid cells corresponded to the grossly visible raised, white foci (Fig. 2). These were present primarily in the cortex and usually surrounded renal arteries, glomeruli and tubules. The predominant central nervous system lesion was

lymphocytic meningitis which was of moderate severity in the cerebellum but mild and scattered in the cerebral cortex (Fig. 3). Mild vascular cuffing within parenchyma was localized to the cerebellum and spinal cord. Paracortical regions of lymph nodes were moderately to markedly hyperplastic. Morphologically, germinal centers appeared quiescent. Lymph nodes were congested, variably edematous, and infrequently hemorrhagic. Irregular foci of necrosis were scattered throughout the paracortex of most nodes. Except for typical vascular lesions the spleen was normal.

## DISCUSSION

Using similar techniques to those employed in cattle, transmission of infective blood from a bovine with experimental MCF to a clinically normal bison

resulted in the bison developing signs and lesions of MCF 25 days later. This compares to the incubation period in cattle of  $30.2 \pm 13.6$  days.<sup>2</sup> We have provided strong evidence that the clinical-pathologic syndrome of MCF can be transmitted from cattle to bison using whole blood. Less likely explanations for the occurrence of MCF in this bison include activation of a latent virus by xenogeneic blood transfusion, vector or fomite assisted transmission from other sources, or coincidence. Whether bovine-bison transmission of MCF occurs naturally is unknown. The epizootiological significance and practical consequences of alleged bovine-bison transmission in the field must await further studies including an understanding of the etiology and pathogenesis of North American MCF.

The lesions present in this case of experimental MCF in a bison are similar to those observed in naturally-occurring cases of acute MCF in bison which we have examined during the past few years and also resemble those described by Ruth *et al.*<sup>7</sup> Our previous reports describe lesions in cattle with experimental MCF.<sup>2,3,4</sup> The lesions of bison and cattle with experimental MCF are very similar with a few exceptions and qualifications. Compared to cattle with MCF, lesions of bison MCF, both in this experimental case and in naturally occurring cases, tend to have fewer lymphoid cells accumulated in epithelial and vascular lesions. Likewise, lymphoid hyperplasia in lymph nodes, although marked, is less pronounced than that usually seen in cattle. Bison epithelial lesions tend to be more edematous, vesiculated, and

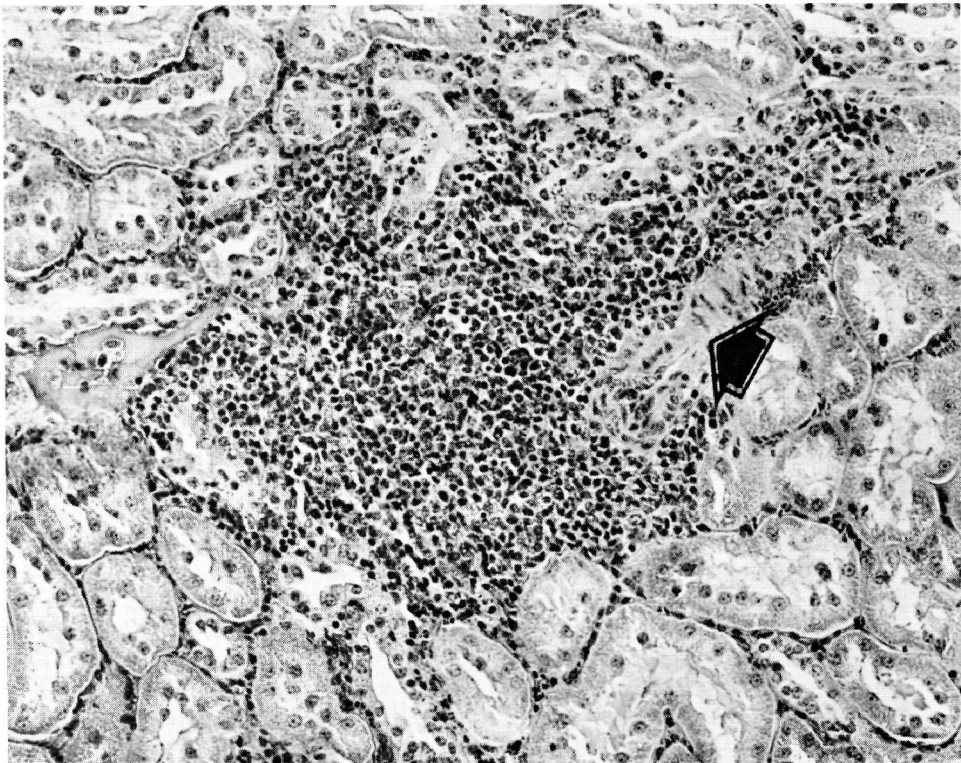


FIGURE 2. Focal accumulation of lymphoid cells within renal interstitium. Notice proximity to artery (arrow). H&E  $\times 100$ .

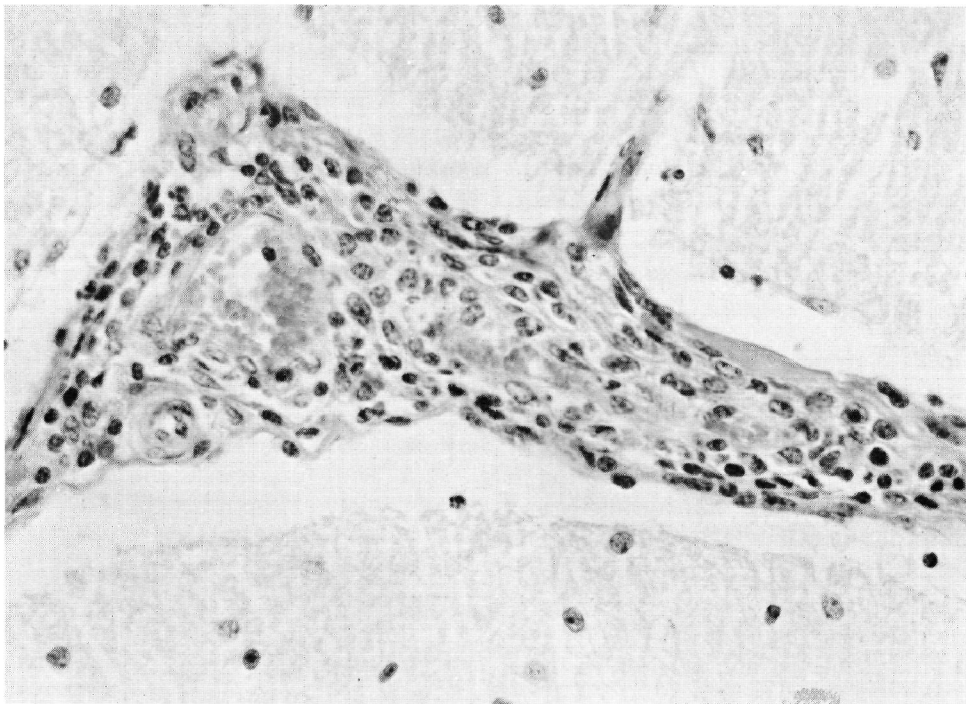


FIGURE 3. Lymphoid cells within the interfolial meninges of the cerebellum. H&E  $\times$  160.

necrotic than corresponding lesions in cattle. Neutrophils are also more obvious in the bison lesions. Finally, lesions in bison are more commonly characterized by presence of congestion and occasionally hemorrhage than those in

cattle. Whether these qualitative differences are a function of the acuteness of the disease in bison or a fundamental difference in the biological behavior of the agent in bison, or both, is unknown.

### Acknowledgements

We wish to thank Dr. R.E. Pierson for helpful clinical assistance.

### LITERATURE CITED

1. CLARK, K.A., R.M. ROBINSON, R.G. MARBURGER, L.P. JONES and J.H. ORCHARD. 1970. Malignant catarrhal fever in Texas cervids. *J. Wildl. Dis.* 6: 376-383.
2. LIGGITT, H.D., J.C. DeMARTINI, A.E. McCHESNEY, R.E. PIERSON and J. STORZ. 1978. Experimental transmission of malignant catarrhal fever in cattle: Gross and histopathologic changes. *Am. J. Vet. Res.* 39: 1249-1257.
3. — and —. 1980. The pathomorphology of malignant catarrhal fever. I. Generalized lymphoid vasculitis. *Vet. Pathol.* 17: 59-73.
4. —. 1980. The pathomorphology of malignant catarrhal fever. II. Multisystemic epithelial lesions. *Vet. Pathol.* 17: 74-84.

5. PIERSON, R.E., D. THAKE, A.E. McCHESNEY and J. STORZ. 1973. An epizootic of malignant catarrhal fever in feedlot cattle. J. Am. vet. med. Ass. 163: 349-350.
6. REID, H.W., D. BUXTON, W. CORRIYALL, A.R. HUNTER, D.A. McMARTIN and R. RUSHTON. 1979. An outbreak of malignant catarrhal fever in Red deer (*Cervus elaphus*). Vet. Rec. 104: 120-123.
7. RUTH, G.R., D.E. REID, C.A. DALEY, M.W. VORHIES, K. WOHLGEMUTH and H. SHAVE. 1977. Malignant catarrhal fever in bison. J. Am. vet. med. Ass. 171: 913-917.

*Received for publication 27 July 1979*

---