

CLINICAL MANGE OF THE BLACK BEAR, *Ursus americanus*, ASSOCIATED WITH *Ursicoptes americanus* (ACARI: AUDYCOPTIDAE)

Authors: YUNKER, C. E., BINNINGER, C. E., KEIRANS, J. E., BEECHAM, J., and SCHLEGEL, M.

Source: Journal of Wildlife Diseases, 16(3) : 347-356

Published By: Wildlife Disease Association

URL: <https://doi.org/10.7589/0090-3558-16.3.347>

The BioOne Digital Library (<https://bioone.org/>) provides worldwide distribution for more than 580 journals and eBooks from BioOne's community of over 150 nonprofit societies, research institutions, and university presses in the biological, ecological, and environmental sciences. The BioOne Digital Library encompasses the flagship aggregation BioOne Complete (<https://bioone.org/subscribe>), the BioOne Complete Archive (<https://bioone.org/archive>), and the BioOne eBooks program offerings ESA eBook Collection (<https://bioone.org/esa-ebooks>) and CSIRO Publishing BioSelect Collection (<https://bioone.org/csiro-ebooks>).

Your use of this PDF, the BioOne Digital Library, and all posted and associated content indicates your acceptance of BioOne's Terms of Use, available at www.bioone.org/terms-of-use.

Usage of BioOne Digital Library content is strictly limited to personal, educational, and non-commercial use. Commercial inquiries or rights and permissions requests should be directed to the individual publisher as copyright holder.

BioOne is an innovative nonprofit that sees sustainable scholarly publishing as an inherently collaborative enterprise connecting authors, nonprofit publishers, academic institutions, research libraries, and research funders in the common goal of maximizing access to critical research.

CLINICAL MANGE OF THE BLACK BEAR, *Ursus americanus*, ASSOCIATED WITH *Ursicoptes americanus* (ACARI: AUDYCOPTIDAE)

C. E. YUNKER,[□] C. E. BINNINGER,[□] J. E. KEIRANS,[□] J. BEECHAM[□] and M. SCHLEGEL[□]

Abstract: Numerous specimens of a mite, *Ursicoptes americanus* Fain and Johnston, 1970 (Acari: Audycoptidae), were found in skin scrapings from an aged female black bear, *Ursus americanus*, afflicted with a severe generalized mange. The mite had not been found previously in association with clinical dermatitis. The male, nymph and larva of *Ursicoptes americanus*, heretofore unknown, are described and the generic diagnosis is amplified. Discovery of the male aids in resolving the questionable taxonomic status of the family Audycoptidae.

INTRODUCTION

During a recent study of Idaho populations of the black bear, *Ursus americanus* Pallas, numerous specimens of a mite, *Ursicoptes americanus* Fain and Johnston, 1970 (Acari: Audycoptidae), were recovered in skin scrapings from a female with severe alopecia. Prior to this study, the mite was known only from the original description of three female specimens taken from a black bear that died in a zoo in Kansas.⁴ No clinical disease was recorded in the host. The dermatitis of the bear captured in Idaho is described clinically. We also describe, for the first time, the male, nymph and larva of *Ursicoptes americanus*. The discovery of the male permits amplification of the generic diagnosis and aids in resolving the questionable taxonomic status of the Audycoptidae.[□]

MATERIALS AND METHODS

One hundred bears were captured by means of Aldrich spring-activated foot snares in the Nez Perce National Forest of north-central Idaho during 1975 and 1976.¹ The bears were immobilized with phencyclidine hydrochloride[□] and skin scrapings were made from areas with a dermatitis resembling mange. Scrapings were cleared in warm 5% potassium hydroxide and examined microscopically.

RESULTS AND DISCUSSION

Four bears showed clinical signs of mange, but mites (*Ursicoptes americanus*) were found in deep skin scrapings from only one. This bear (no. 500), when first captured in July 1975,

[□] U.S. Department of Health, Education, and Welfare, Public Health Service, National Institutes of Health, National Institute of Allergy and Infectious Diseases, Epidemiology Branch, Rocky Mountain Laboratories, Hamilton, Montana 59840, USA.

[□] Southway Animal Clinic and Hospital, Lewiston, Idaho 83501, USA.

[□] Idaho Department of Fish and Game, Boise, Idaho 84707, USA.

[□] After this manuscript had been set in type *Ursicoptes procyni*, a second species of the genus, was described from *Procyon lotor*, a raccoon, in North America (Fain, A. and N. Wilson. 1979. *Acarologia* 5: 351-354). In this paper, mention is made of *Ursicoptes americanus* producing a "skin disease with damage to the fur" of the polar bear, *Ursus* (= *Thalarctos*) *maritimus*.

[□] Sernylan,[®] Bio-ceutic Laboratories, Inc., St. Joseph, Missouri 64502, USA.

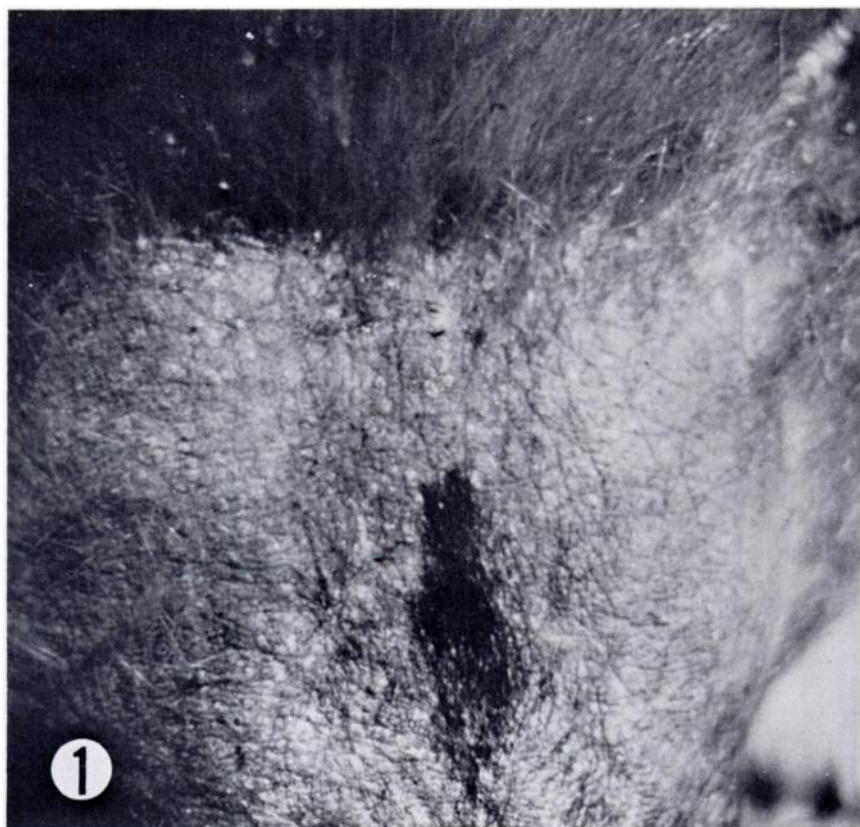


FIGURE 1. Head of bear No. 500, showing extent of alopecia, 12 June 1975.

had chronic lesions on the muzzle and forehead (Fig. 1) and acute lesions, although to a lesser extent, on the neck, thorax and front legs. The head lesions included 90% alopecia, lichenification, irregular gray colored areas, and light epidermal exfoliation. On the forehead, there was an abrupt border between normal, fully-haired areas and areas of alopecia. Serum crusts or scabs were absent. On the neck, thorax and front legs, lesions were more pronounced, with heavy exfoliation, large scales and apparent pruritis, as evidenced by obvious rubbing marks. In these three areas alopecia was less severe, skin color was normal and lichenification was absent.

Thirteen months later, when this same bear was recaptured, the skin lesions were compared with those described above. Regrowth of hair to 50-70% of normal length and thickness had occurred on the muzzle and forehead. Although the skin had become melanotic, all lesions seen a year earlier had improved. *Ursicoptes* mites were abundant in skin scrapings from affected areas. At this time, also, large numbers of lice, *Trichodectes pinguis euarctidos* Hopkins, 1954 (Mallophaga), were present over most of the body. Although a species of *Demodex* (Acari: Demodicidae) has been reported from an alopecic black bear in Wisconsin,⁷

Demodex was not found in the skin scrapings of bear No. 500.

The role of *Ursicoptes* in the dermatitis of Idaho bears warrants further study. The continued occurrence of these mites in lesions of the host is presumptive evidence that they are the causal agent and partial clinical recovery after one year would suggest that the condition is self-limiting. However, related mites (*Audycoptes* spp.) are known to inhabit hair follicles, apparently without producing mange or mange-like signs in their hosts (squirrel monkeys).⁵ Thus, *Ursicoptes* may have been an adventitious or accessory factor in the bear's condition.

Genus *Ursicoptes* Fain and Johnston, 1970⁴

Diagnosis: Audycoptidae Lavoipierre, 1964.³ Idiosoma elongate-ovoid, in both sexes rounded posteriorly; with se-jugal furrow, propodosomal shield and 2 pairs of modified setae [propodosomal sensory organs of Lavoipierre (Fig. 3)]; anus terminal. Anterior legs well-developed, most segments with recurved ventral spurs and/or bosses; tarsi with a terminal clawlike spur, a subterminal clawlike spine and a segmented stalk bearing ambulacral sucker. Posterior legs ventral, reduced and telescoped; tibiae each with a well-developed dorsal seta, which may be bifid; tarsi clawlike, each bearing an elongate attenuate seta, lacking ambulacral suckers. Coxal epimerites III fused with IV. Gnathosoma elongate, conical; chelicerae chelate. Female genital opening a transverse slit; male with rodlike aedeagus located within sclerotized ring on opisthosomal venter, with adanal suckers; larva with epimerite III.

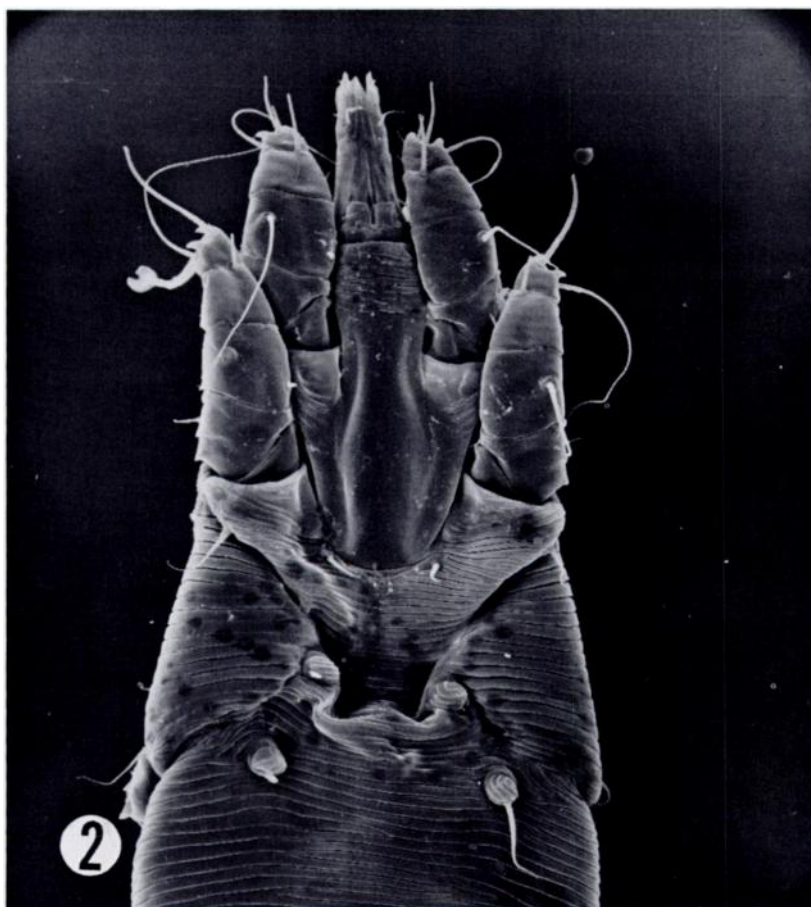
Type-species: *U. americanus* Fain and Johnston, 1970

Remarks: *Ursicoptes* is distinguishable from other audycoptid genera [*Audycoptes* Lavoipierre, 1964 (type-species *A. greeri* Lavoipierre, 1964) and *Saimiriopetes* Fain, 1968¹ (type-

species *S. paradoxus* Fain, 1968)] in lacking furcate setae, sclerotized bars or long cuticular lobes on the opisthosomal dorsum. However, the three genera are clearly related based on numerous characteristics shared among females. These females also resemble those of the family Rhyncoptidae Lawrence, 1956,⁶ as noted by Lavoipierre. This resemblance, which includes the absence of a solenidion on genua I and II, prompted Fain³ to question the status of the Audycoptidae ("On peut donc se demander s'il faut encore conserver le status de famille au genre *Audycoptes* et s'il ne serait pas préférable de le ramener au rang de sous-famille au sein des Rhyncoptidae?"). However, the unavailability of males for comparison caused Fain to retain separate familial status for the Audycoptidae. Although males are still unknown for the type-species of the nominal genus of that family, our finding of a male of *Ursicoptes* permits comparison with those of three *Rhyncoptes* spp. (including the type-species). All known rhyncoptid males [*R. recurvidens* Lawrence, 1956, *R. anastosi* (Fain, 1962), and *R. cercopithecii* Fain, 1964]^{2, 6} resemble psoroptids, in which sexual dimorphism is marked. In particular, the posterior of the male idiosoma shows a tendency toward bilobation and legs III are greatly enlarged and modified. In contrast, the sexes of *Ursicoptes* are not dimorphic; the male has a rounded opisthosoma and unexceptional legs III, bearing little resemblance to Psoroptidae. Thus, insofar as morphology of the male of *Ursicoptes* is concerned, the limits of the family Audycoptidae do not overlap with those of the Rhyncoptidae.

Ursicoptes americanus Fain and Johnston, 1970

Material studied: 4 females, 1 male, 1 nymph and 2 larvae (RML 63619) from skin scrapings of a black bear, *Ursus americanus*, captured on Coolwater Ridge (elev. approx. 1500 m), between



FIGURES 2-7. *Ursicoptes americanus*: (2) female dorsum, 530 \times ; (3) modified seta of propodosoma (female specimen), 5000 \times ; (4) male, dorsum, 780 \times ; (5) male, venter, 780 \times ; (6) nymph, dorsum, 726 \times ; (7) nymph, venter, 726 \times .

Lochsa and Selway Rivers, Nez Perce National Forest, Idaho County, Idaho; 12 June 1975. Eighteen females, 2 larvae (RML 63652) from same bear recaptured in same locality, 1 July 1976, plus approximately 50 additional specimens, most or all female, in alcohol.

Description - Female: (Figs. 2 and 3) Larviparous (otherwise as described and figured by Fain and Johnston, 1970).

Male: (Figs. 4 and 5) Length including gnathosoma, but not extruded chelicerae, 265 μm ; greatest width 138 μm . Idiosoma elongate-ovoid. A long, narrow prosomal shield anterior of sejugal furrow. Integument striate except posterodorsal idiosoma and most of venter posterior to coxal epimerites III, which areas are sclerotized. With 10 pairs of dorsal and 9 pairs of ventral idiosomal

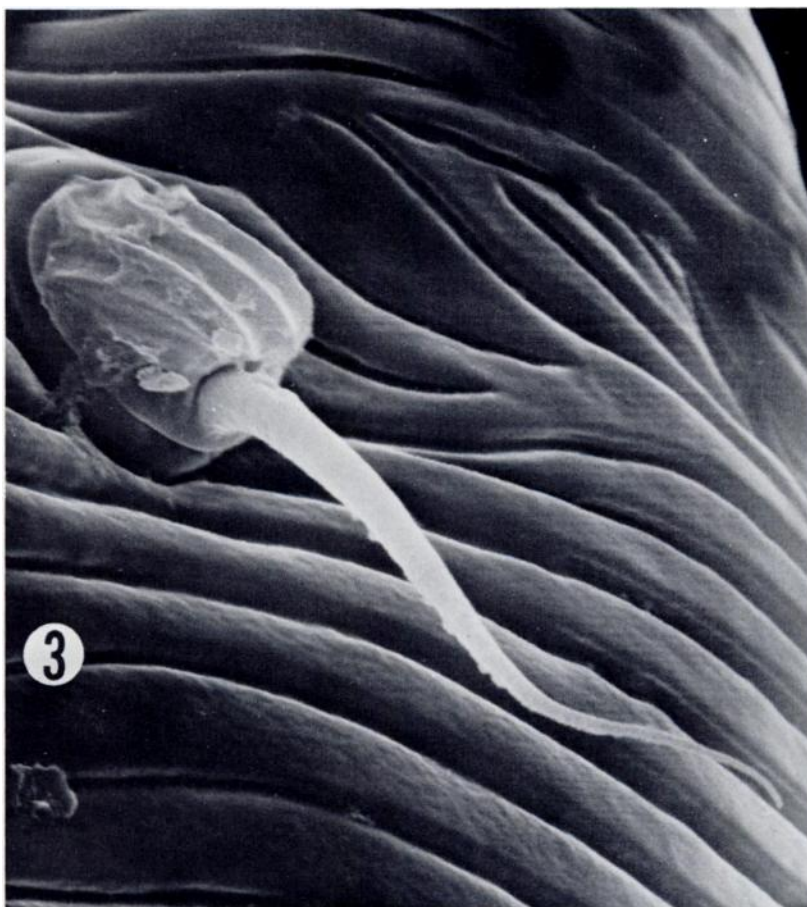


FIGURE 3. Modified seta of propodosoma (female specimen), 5000 \times .

setae (d, absent),[□] their shapes and relative proportions equivalent to corresponding ones of female. In contrast to the female, a single pair of short adanal setae arise terminally from large, deepset, heavily sclerotized rings. Genital organ an elongate rod located within a large, heavily sclerotized ring on opisthosomal venter. Anus terminal, accompanied anteroventrally by a pair of circular discs. Caudal aspect of

idiosoma broadly rounded, not bilobate. Epimerites and legs, including solenidia and other setae, as in female except clawlike processes of tarsi III and IV longer and more robust, and thickened seta of tibia IV not bifid. Gnathosoma longer than wide, palpi not seen; chelicerae chelate.

Nymph: (Figs. 6 and 7) Length including gnathosoma, 286 μm , greatest width 138 μm . Similar to female except

[□] Setal terminology follows that of Fain and Johnston, 1970.⁴

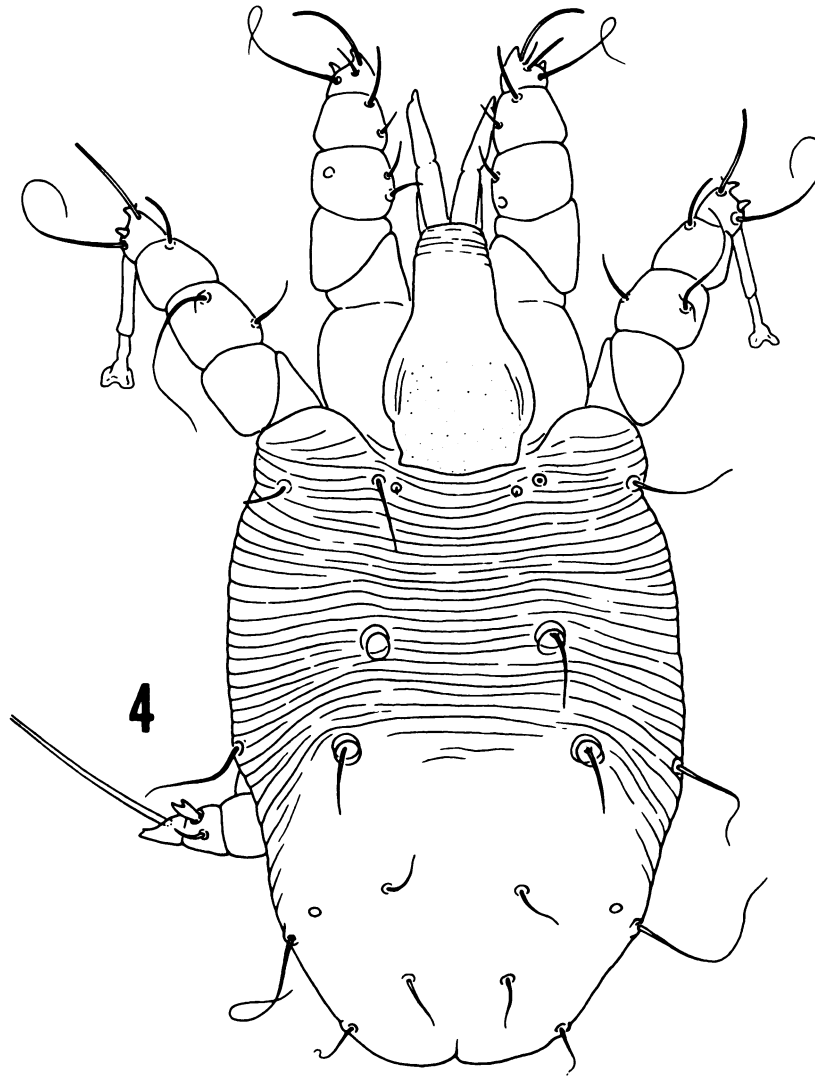


FIGURE 4. Male, dorsum, 780X.

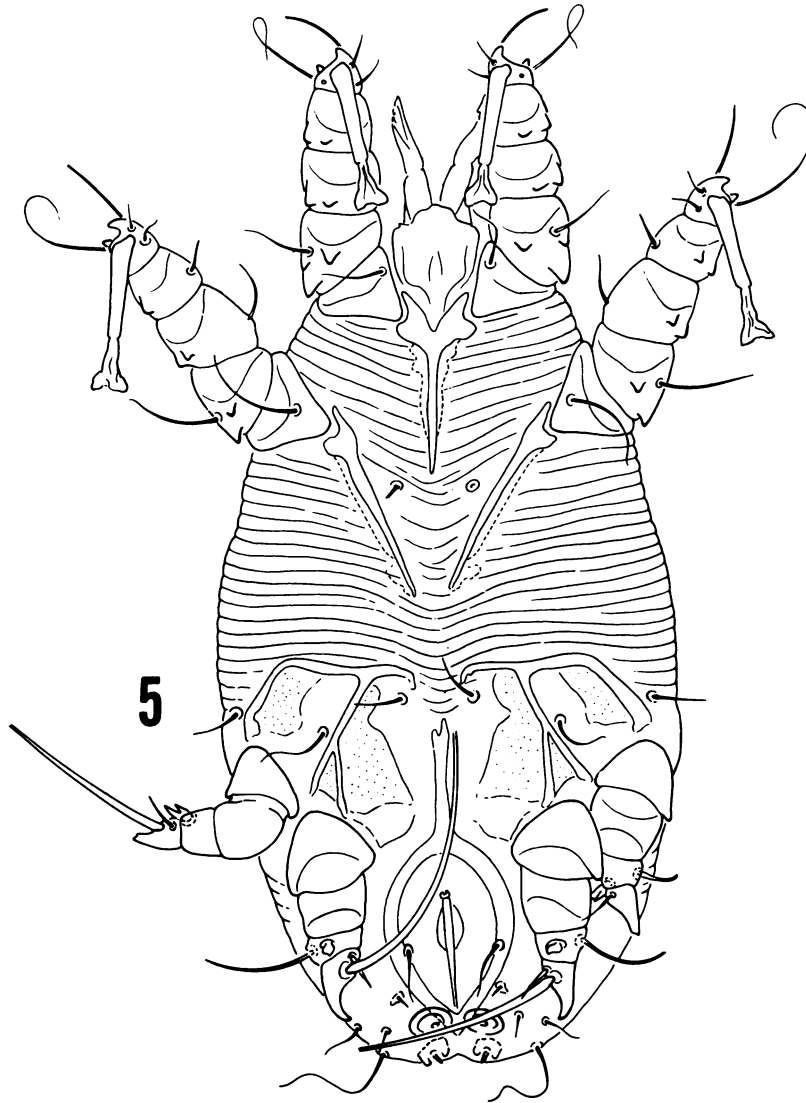


FIGURE 5. Male, venter, 780X.

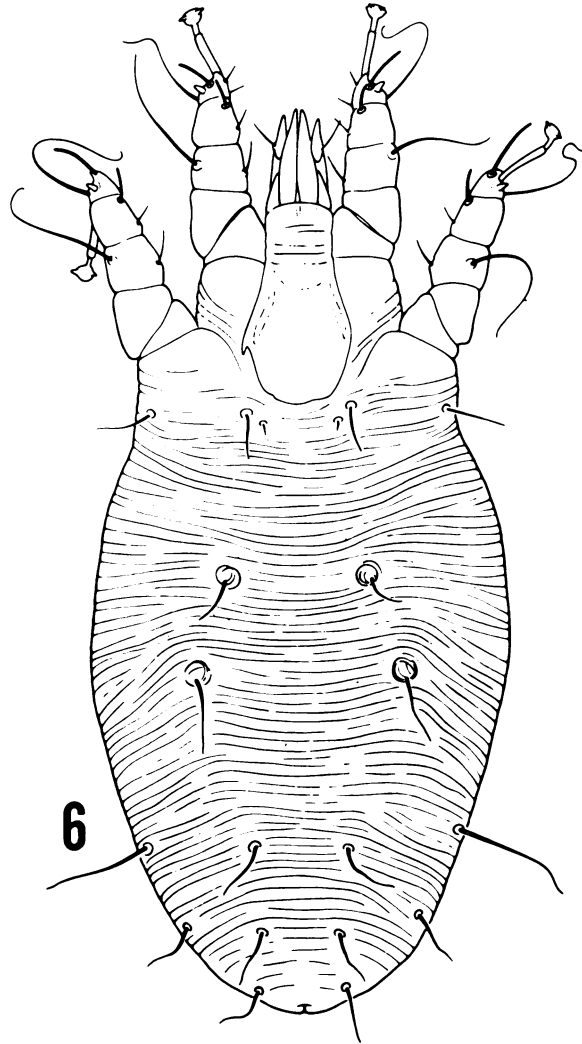


FIGURE 6. Nymph, dorsum, 726 \times .

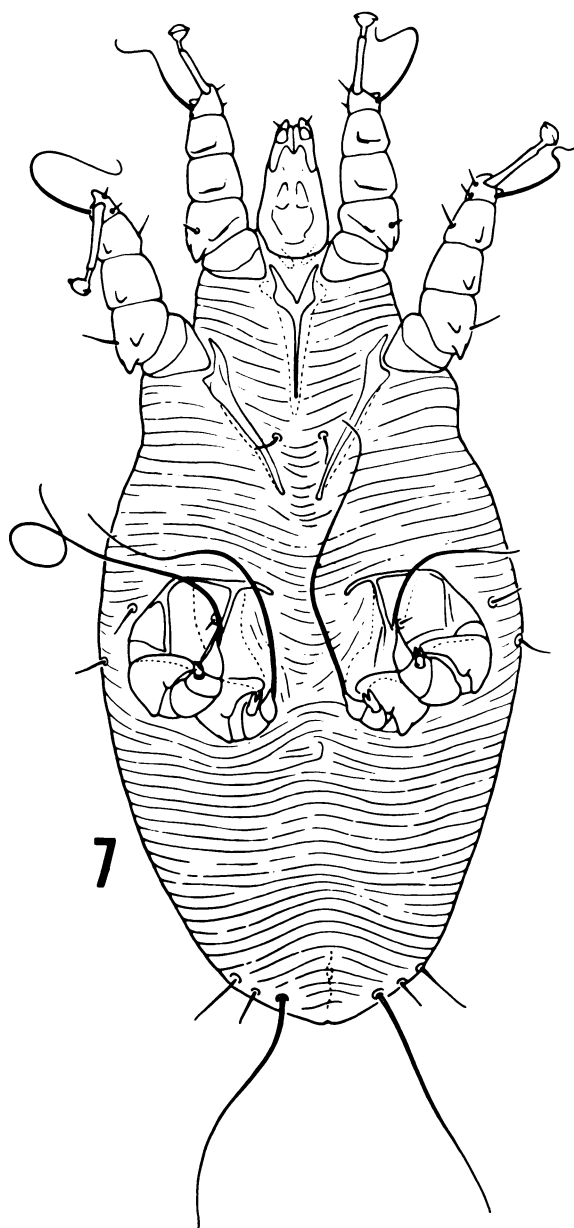


FIGURE 7. Nymph, venter, 726X.

smaller, lacking genitalia and genital setae, and clawlike prolongation of tarsi III and IV reduced.

Larva: Length including gnathosoma, 228 μ m, greatest width 101 μ m.

Similar to nymph except smaller, setae 1₄, 1₅, and d₄ absent, and 1₃ and d₅ longer. Epimeres I-III present. Hexapod; legs, including setae, as in nymph except a single solenidion on tarsi I and II.

Acknowledgements

We thank Mr. M.D. Corwin, RML, Hamilton, MT, who took the scanning electron micrographs. The line drawings were skillfully made by Mrs. Alma D. Smith, RML, Hamilton, MT, and Ms. Trudy Nicholson, Division of Research Services, National Institutes of Health, Bethesda, MD. This project was supported in part by Federal Aid in Wildlife Restoration Project No. W-160-R.

LITERATURE CITED

1. BEECHAM, J. Some population characteristics of two black bear populations in Idaho. In: Proc. 4th Int. Conf. Bear Res. and Manage. C.J. Martinka and K.L. McArthur, eds. (In press).
2. FAIN, A. 1965. A review of the family Rhyncoptidae Lawrence parasitic on porcupines and monkeys (Acarina: Sarcoptiformes). In: *Advances in Acarology*. Vol 2, J. Naegle (ed.), Cornell Univ. Press, Ithaca, NY, p. 135-159.
3. ———. 1968. Notes sur trois acariens remarquables. *Acarologia* 10: 276-291.
4. ——— and D.E. JOHNSTON. 1970. Un nouvel Acarien de la famille Audycptidae chez l'ours noir *Ursus americanus* (Sarcoptiformes). *Acta Zool. Pathol. Antverpiensia*. No. 50: 179-181.
5. LAVOPIERRE, M.M.J. 1964. A new family of acarines belonging to the suborder Sarcoptiformes parasitic in the hair follicles of primates. *Ann. Natal Mus.* 16: 191-208.
6. LAWRENCE, R.F. 1956. Studies on South African fur mites (Trombidiformes and Sarcoptiformes). *Ann. Natal Mus.* 13: 337-375.
7. MANVILLE, A.M., II. 1978. Ecto- and endoparasites on the black bear in Northern Wisconsin. *J. Wildl. Dis.* 14: 97-101.

Received for publication 21 June 1979