

**EXPERIMENTAL TRANSMISSION OF *Sarcocystis* sp.  
(PROTOZOA: SARCOCYSTIDAE) BETWEEN THE  
SHOVELER (*Anas clypeata*) DUCK AND THE STRIPED  
SKUNK (*Mephitis mephitis*)**

Authors: CAWTHORN, R.J., RAINNIE, D., and WOBESER, G.

Source: Journal of Wildlife Diseases, 17(3) : 389-394

Published By: Wildlife Disease Association

URL: <https://doi.org/10.7589/0090-3558-17.3.389>

---

BioOne Complete ([complete.BioOne.org](https://complete.BioOne.org)) is a full-text database of 200 subscribed and open-access titles in the biological, ecological, and environmental sciences published by nonprofit societies, associations, museums, institutions, and presses.

Your use of this PDF, the BioOne Complete website, and all posted and associated content indicates your acceptance of BioOne's Terms of Use, available at [www.bioone.org/terms-of-use](http://www.bioone.org/terms-of-use).

Usage of BioOne Complete content is strictly limited to personal, educational, and non - commercial use. Commercial inquiries or rights and permissions requests should be directed to the individual publisher as copyright holder.

---

BioOne sees sustainable scholarly publishing as an inherently collaborative enterprise connecting authors, nonprofit publishers, academic institutions, research libraries, and research funders in the common goal of maximizing access to critical research.

**EXPERIMENTAL TRANSMISSION OF *Sarcocystis* sp.  
(PROTOZOA: SARCOCYSTIDAE) BETWEEN THE SHOVELER  
(*Anas clypeata*) DUCK AND THE STRIPED SKUNK (*Mephitis  
mephitis*)**

R.J. CAWTHORN and D. RAINNIE, Department of Veterinary Microbiology, Western College of Veterinary Medicine, University of Saskatchewan, Saskatoon, Saskatchewan, Canada, S7N 0W0.

G. WOBESER, Department of Veterinary Pathology, Western College of Veterinary Medicine, University of Saskatchewan, Saskatoon, Saskatchewan, Canada, S7N 0W0.

**Abstract:** Muscle containing macroscopic cysts of *Sarcocystis* sp. from naturally infected wild shoveler (*Anas clypeata*) ducks was fed to two captive striped skunks (*Mephitis mephitis*). The skunks passed sporocysts in their feces beginning 19 and 22 days post-infection, and continued to pass small numbers of sporocysts sporadically to 63 and 51 days post-infection, respectively. Sporocysts from the skunks were administered orally to four laboratory-reared shovelers. No cysts were found in ducks examined 56 and 84 days post-infection. One duck examined at 85 days post-infection had many microscopic cysts in its skeletal muscle. The remaining duck had numerous small macroscopic cysts in muscle at 154 days post-infection. A skunk fed muscle from this duck began to pass sporocysts on day 18 post-infection. All cysts in muscle (natural and experimental infection) had irregular cauliflower-like projections of the primary cyst wall.

## INTRODUCTION

Macroscopic cysts of *Sarcocystis* spp. are found commonly in the skeletal muscle of North American ducks, but the identity of the final host(s) of these protozoans has evaded most attempts at elucidation, (for a review, see Drouin and Mahrt<sup>1</sup>). Duszynski and Box<sup>2</sup> were able to infect an opossum (*Didelphis virginiana*) with a species of *Sarcocystis* derived from a pintail (*Anas acuta*) duck. The parasite was not transmitted back to the intermediate host and cysts of *Sarcocystis* spp. from other species of ducks were not infectious for opossums.

In this report we describe preliminary results of experimental transmission of *Sarcocystis* sp. from wild shoveler (*Anas clypeata*) ducks to the striped skunk (*Mephitis mephitis*) and then sequentially to laboratory-reared shovelers and a skunk.

## MATERIALS AND METHODS

The original infective material for this study came from two wild adult male shovelers collected near Saskatoon, Saskatchewan in June, 1980. Both ducks had macroscopic cysts of *Sarcocystis* sp. in their muscles. Portions of muscle, (superficial pectoral, triceps brachii, gastrocnemius plus heart and esophagus), were preserved in 10% neutral buffered formalin for histology and the remainder of the muscle was fed to captive skunks.

The skunks used in this study had been taken from dens in northern Alberta, (an area free of rabies), in April, 1978. They were descented and held in individual stainless steel cages before and during the trials. During the 2 years prior to the study the skunks were fed commercial dry dog food. Four skunks were used in the initial trial: two principals received duck muscle and two control skunks in

cages adjacent to the principals, did not receive any duck muscle. Each of the principal skunks was fed the entire skeletal muscle mass from one of the wild ducks. Feces from all of the skunks were examined daily for the 7 days prior to infection by a flotation method using Sheather's sugar solution as the floatation medium.<sup>8</sup> After infection, feces from all skunks were examined daily by the same technique to 160 days post-infection (p.i.) and from 204-210 days p.i.

Feces containing sporocysts were stored in a solution of 2.5% potassium dichromate at 4 C for up to 25 days prior to attempted infection of ducks.

Shovelers used in the experimental infection trials were hatched in the laboratory from eggs collected in the wild. The ducks were reared in an isolation facility and fed a complete pelleted ration containing no medication. The ducks were approximately 8 weeks of age at the time of exposure. Four ducks were used for the infection trial; uninfected ducks, many of which were siblings of the principals, and which were maintained in the same manner, served as controls. Individuals among these "control" ducks were killed at various times (four at 30 days and one each at 153 and 188 days p.i.) for other purposes, and two ducks were killed at 154 and 179 days after infection of the principals and examined specifically for cysts. Samples of superficial pectoral, triceps brachii, gastrocnemius and muscles of the tongue, plus heart and esophagus from all these birds were examined microscopically.

Prior to attempted experimental infection of ducks, skunk feces containing sporocysts were strained through a single layer of cheese cloth, and washed twice with tap water by centrifugation to remove the potassium dichromate. Because few sporocysts were present, the feces from the two infected skunks were pooled. The four principal ducks were infected by intragastric intubation with sporocysts contained in the pooled, washed fecal material.

One of the experimentally infected ducks died under anaesthesia during attempted muscle biopsy on day 56 p.i.; the second duck was killed and examined at day 84 p.i.; the third duck was found dead (trauma) at 85 days p.i. and the final duck was killed and examined on day 154 p.i. In each case a necropsy was performed and samples of all major organs were preserved in 10% neutral buffered formalin for histology. Samples of muscle containing macroscopic cysts from the duck killed at 154 days p.i. were fixed in cold 2.5% glutaraldehyde, post-fixed in 2% osmium tetroxide, dehydrated and embedded in Epon. Sections were stained with uranyl acetate and lead citrate for ultrastructural study.

Muscle from the duck killed at 154 days p.i. was divided and fed to two previously uninfected skunks. A third skunk maintained in an adjacent cage served as a control. Food was withheld from the skunks for 3 days prior to attempted infection. These skunks were of the same origin and had been examined and maintained in the same manner prior to infection as those used in the initial trial. Feces were examined daily to day 80 p.i.

Cysts in the muscle of the two wild shovelers and the experimental duck that died at 85 days p.i. were examined ultrastructurally using material removed from haematoxylin-eosin stained histologic slides and processed by the method of Blank *et al.*<sup>1</sup>

## RESULTS

**Transmission:** Both skunks fed muscle tissue from the wild ducks passed sporocysts (Fig. 1) in their feces. Sporocysts were detected in the feces of one skunk on days 19-23, 30, 56 and 63 p.i. and in the feces of the other skunk on days 22, 33-35 and 51 p.i. Very few sporocysts were detected at any time and these were not counted because of the danger of loss of the sporocysts during the counting procedure. No protozoa were detected in the feces of any of the

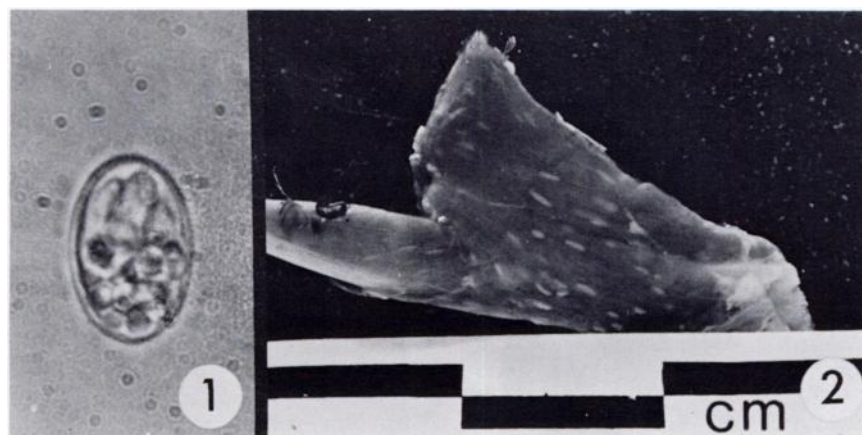

FIGURE 1. Single sporocyst passed by striped skunk fed muscle from a shoveler infected with *Sarcocystis* sp. The granular sporocyst residuum is concentrated at one pole; Portions of two of the four sporozoites are visible. Wet mount  $\times 1950$ .

FIGURE 2. Portion of skeletal muscle containing macroscopic cysts from a laboratory-reared shoveler infected orally 154 days earlier with sporocysts from a striped skunk.

skunks during the week prior to infection, nor at any time in the feces of the two control skunks.

No muscle cysts or other forms suggestive of *Sarcocystis* sp. were detected in the experimentally infected ducks examined at 56 and 84 days p.i. The duck found dead at 85 days p.i. did not have grossly visible cysts, but numerous microscopic cysts were present in all skeletal muscles examined. The duck killed at 154 days p.i. had many macroscopic cysts evident in all skeletal muscles (Fig. 2). No forms suggestive of *Sarcocystis* sp. were found in control ducks examined 154 and 179 days after infection of the principal ducks and none have been found in other birds from the colony examined for other purposes.

Sporocysts were detected on day 18 p.i., in the feces of one of the two skunks fed muscle from the duck killed at 154 days p.i. This skunk shed sporocysts continuously to day 62 p.i. and intermittently thereafter to day 80 p.i. Sporocysts were not detected in the feces of the other

principal nor in feces of the control skunk to 80 days p.i.

**Morphology of muscle cysts:** The macroscopic cysts in the wild shovellers measured approximately  $2$  to  $8 \times 1$  mm. Microscopically, the primary cyst wall in cysts from both ducks had numerous short, irregular, projections. These were "cauliflower-like" at the ultrastructural level (Fig. 3a).

The microscopic cysts present in the duck found dead on day 85 p.i. had a mean diameter of  $80.0 \pm 16.2 \mu\text{m}$  ( $47.5 - 100.0$ ,  $n=18$ ) in fixed stained tissue. The cysts contained pale-staining, vacuolated merozoites and merozoites could not be identified. The primary cyst wall had projections similar to, but shorter and less elaborate than, those of cysts from the wild ducks (Fig. 3b).

The macroscopic cysts in the duck killed on day 154 p.i. were 1 to 3 mm long and less than 1 mm in diameter (Fig. 2). At the light microscopic level, the central area of the cysts contained merozoites surrounded by a thin rim of pale,

vacuolated macrocytes. The primary cyst wall had projections (Fig. 3c) that were similar to those of the cysts from the wild ducks.

**Morphology of sporocysts:** Most of the organisms (63 of 68 examined) in recently passed feces were present as single sporocysts (Fig. 1); the remainder were present as sporulated oocysts with a thin wall. The ellipsoidal sporocysts ( $n = 27$ ) were  $12.4 \pm 1.4 \mu\text{m}$  (range 10.0 to  $14.0 \mu\text{m}$ ) long and  $7.9 \pm 1.0 \mu\text{m}$  wide (range 5.5 to 9.5). The length:width ratio was  $1.6 \pm 0.2$  (range 1.3-2.0). The granular sporocyst residuum was usual-

ly concentrated at one end of the sporocyst. Four sporozoites were present.

#### DISCUSSION

This study was undertaken as a preliminary trial based on the hypothesis that the striped skunk, a predator of nesting waterfowl and an ubiquitous omnivore about marshes throughout much of North America, might serve as a definitive host for *Sarcocystis* spp. of ducks. It appears that the skunk is a suitable final host for a *Sarcocystis* sp. from the shoveler.

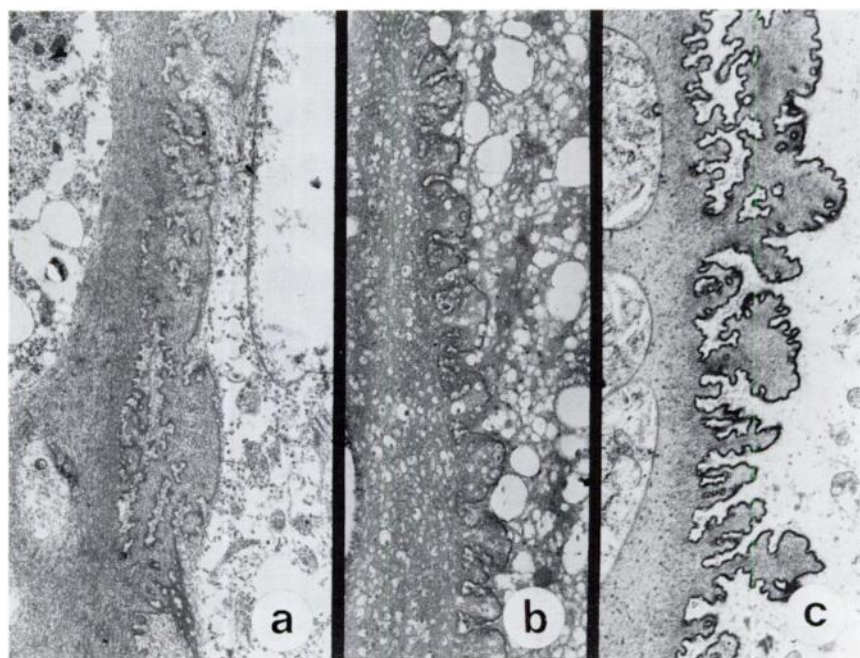


FIGURE 3. Sections through the periphery of cysts in the skeletal muscle of shovelers. The cyst lumen is to the left in all sections. Sections a and b were prepared from formalin-fixed, stained tissue on histologic slides. Uranyl acetate-lead citrate  $\times 6650$ . a. Naturally-infected wild duck (macroscopic cyst). The primary cyst wall has many irregular cauliflower-like projections. b. Experimentally-infected duck (microscopic cyst, 85 days post-infection). The projections of the primary cyst wall are smaller and less elaborate than those in a or b. c. Experimentally-infected duck (macroscopic cyst, 154 days post-infection, same bird as illustrated in Fig. 2). The cyst wall projections are similar to those in the wild bird (a).

*Sarcocystis* spp. infection is common in North American ducks, but there have been very few reports of infection in ducks in Europe (Betegh and Dorcich, 1912; Krause and Goranoff 1933, cited by Erickson<sup>6</sup>) where skunks do not occur in the wild. Munday *et al*<sup>10</sup> commented that the absence of macroscopic cysts in Australian birds was probably related to the lack of a suitable definitive host on that continent.

The morphology of the primary cyst wall is regarded to be characteristic of species of *Sarcocystis*, although cyst wall morphology cannot be used alone for species identification.<sup>9</sup> In this study, the mature experimentally-induced cysts (day 154 p.i.) had the same type of cyst wall as did the cysts in the wild ducks: The wall of the immature cysts (day 85 p.i.) was similar, but less well developed, indicating that all were probably of one species.

The cysts found in a duck at 85 days p.i. were not visible grossly and appeared to be immature, whereas those at 154 days p.i. were small, but visible grossly, and were infective. Drouin and Mahrt<sup>1</sup> speculated that macroscopic cysts in the shoveler may require about 6 months to become apparent; our results support that suggestion. This long period of development probably explains why macroscopic cysts are detected very rarely in juvenile waterfowl collected during the hunting season. (Chabreck<sup>2</sup> did report one instance of macroscopic cysts in a juvenile shoveler collected in Louisiana.) Drouin and Mahrt<sup>1</sup> suggested that *Sarcocystis* sp. was not transmitted to shovelers in Alberta, as they did not find infections in any of 14 juvenile ducks examined in "the autumn". However, if these ducks hatched about mid-June, most would have migrated from Alberta within approximately 4 months of hatching, allowing insufficient time for macroscopic cyst development. Microscopic, immature cysts could develop within that period,

provided the ducks were infected shortly after hatching.

In this study, cysts were not detected in two of the four of the experimentally-infected ducks. This may have been due either to lack of infection, or lack of detectable infection. One of these, the duck killed at day 56 p.i., may have been at a stage of the parasite's life cycle at which neither muscular or extramuscular forms were detectable. The lack of infection in the duck killed at 84 days p.i. is more difficult to explain, as a bird examined the following day was infected. The number of sporocysts given to the ducks was not counted, but was very low (probably fewer than 20 per bird), and the viability of the sporocysts after storage was unknown. Leek and Fayer<sup>7</sup> demonstrated that sporocysts of *S. cruzi* stored in potassium dichromate had a low excystation rate. Hence, this duck may have received no viable sporocysts, or the infection may have been so light that it was not detected in the samples examined.

The severity of infection in the two experimental ducks (Fig. 2) is surprising in light of the small dose of sporocysts administered. This fact considered with the low rate of sporocyst passage by the skunks, suggests that most replication of the parasite occurs within the intermediate host.

Macroscopic cysts in ducks have been considered to be of one species, *S. rileyi*, but to our knowledge there have been no detailed comparative studies of the cysts and no cross-infection trials have been attempted. Drouin and Mahrt<sup>1</sup> described macroscopic cysts with two types of cyst wall in naturally infected ducks, but whether this represented a specific difference or was related to age of the cysts was not determined. Duszynski and Box<sup>5</sup> were able to transmit *Sarcocystis* sp. from the pintail to the opossum; but were not able to transmit *Sarcocystis* sp. from the green-winged teal (*Anas crecca carolinensis*) or shoveler to that final host, suggesting

that there may be more than one species of *Sarcocystis* in ducks.

At present, we are attempting cross transmission of the *Sarcocystis* sp. de-

rived from the shoveler to other waterfowl and we are examining the development of the parasite in the intermediate and final hosts.

#### Acknowledgements

The authors wish to thank Dr. J. Iversen and Ms. A. Robertson for providing the skunks used in this study; Dr's R. Salmon and K. Dunkelgod, Canada Department of Agriculture for the medication-free duck feed; Dr. P.H.G. Stockdale for many helpful suggestions and I. Shirley and G. Appl for their assistance with electronmicroscopy and photography. Wild waterfowl used in this study were collected under permit from the Canadian Wildlife Service. The study was supported by an NSERC University Research Fellowship and operating grant to the senior author and by a grant from the Saskatchewan Department of Tourism and Renewable Resources for wildlife disease studies to Wobeser. The suggestions of the anonymous reviewers are appreciated.

#### LITERATURE CITED

1. BLANK, H., C. DAVIS and C. COLLINS. 1970. Electron microscopy for the diagnosis of cutaneous viral infection. *Br. J. Dermatol.* 83: 69-80.
2. CHABRECK, R.H. 1965. Sarcosporidiosis in ducks in Louisiana. *Trans. N. Am. Wildl. Conf.* 30: 174-184.
3. DROUIN, T.E. and J.L. MAHRT. 1979. The prevalence of *Sarcocystis* Lankester, 1882, in some birds in western Canada, with notes on its life cycle. *Can. J. Zool.* 57: 1915-1921.
4. ———. 1980. The morphology of cysts of *Sarcocystis* infecting birds in western Canada. *Can. J. Zool.* 58: 1477-1482.
5. DUSZYNSKI, D.W. and E.D. BOX. 1978. The opossum (*Didelphis virginiana*) as a host for *Sarcocystis debonei* from cowbirds (*Molothrus ater*) and grackles (*Cassidix mexicanus*, *Quiscalus quiscula*). *J. Parasit.* 64: 326-329.
6. ERICKSON, A.B. 1940. *Sarcocystis* in birds. *Auk* 57: 514-519.
7. LEEK, R.G. and R. FAYER. 1979. Survival of sporocysts of *Sarcocystis* in various media. *Proc. Helm. Soc. Wash.* 46: 151-154.
8. LEVINE, N.D. 1966. *Protozoan Parasites of Domestic Animals and Man*. Burgess Publ. Co., Minneapolis, 412 pp.
9. MEHLHORN, H. and A.O. HEYDORN. 1978. The Sarcocystidae (Protozoa, Sporozoa): life cycle and fine structure. *Adv. Parasitol.* 16: 43-91.
10. MUNDAY, B.L., W.J. HARTLEY, K.E. HARRIGAN, P.J.A. PRESIDENTE and D.L. OBENDORF. 1979. *Sarcocystis* and related organisms in Australian wildlife: II. survey findings in birds, reptiles, amphibians and fish. *J. Wildl. Dis.* 15: 57-73.

Received for publication 6 February 1981