

## **PRIMARY HEPATOCELLULAR CARCINOMA IN A BLACKTAILED PRAIRIE DOG (CYNOMYS LUDOVICIANUS)**

Authors: WOOLF, ALAN, KING, JOHN, and TENNANT, BUD

Source: Journal of Wildlife Diseases, 18(4) : 517-520

Published By: Wildlife Disease Association

URL: <https://doi.org/10.7589/0090-3558-18.4.517>

---

The BioOne Digital Library (<https://bioone.org/>) provides worldwide distribution for more than 580 journals and eBooks from BioOne's community of over 150 nonprofit societies, research institutions, and university presses in the biological, ecological, and environmental sciences. The BioOne Digital Library encompasses the flagship aggregation BioOne Complete (<https://bioone.org/subscribe>), the BioOne Complete Archive (<https://bioone.org/archive>), and the BioOne eBooks program offerings ESA eBook Collection (<https://bioone.org/esa-ebooks>) and CSIRO Publishing BioSelect Collection (<https://bioone.org/csiro-ebooks>).

Your use of this PDF, the BioOne Digital Library, and all posted and associated content indicates your acceptance of BioOne's Terms of Use, available at [www.bioone.org/terms-of-use](http://www.bioone.org/terms-of-use).

Usage of BioOne Digital Library content is strictly limited to personal, educational, and non-commercial use. Commercial inquiries or rights and permissions requests should be directed to the individual publisher as copyright holder.

---

BioOne is an innovative nonprofit that sees sustainable scholarly publishing as an inherently collaborative enterprise connecting authors, nonprofit publishers, academic institutions, research libraries, and research funders in the common goal of maximizing access to critical research.

## PRIMARY HEPATOCELLULAR CARCINOMA IN A BLACKTAILED PRAIRIE DOG (*CYNOMYS LUDOVICIANUS*)

ALAN WOOLF,<sup>□</sup> JOHN KING,<sup>□</sup> and BUD TENNANT<sup>□</sup>

A colony of woodchucks (*Marmota monax*) has been described which experienced a remarkably high prevalence of chronic hepatitis (CH) and primary hepatocellular carcinoma (PHC) over a period of years (Summers et al., 1978, Proc. Natl. Acad. Sci. 75: 4533-4537). A virus was demonstrated in the serum of woodchucks from the colony which had physical and biochemical characteristics similar to the human hepatitis B virus (HBV). A similar disease problem was reported subsequently in blacktailed prairie dogs (*Cynomys ludovicianus*) from the same zoo (Snyder, 1979, In: *Verhandlungsbericht des XXI Internationalen Symposiums über die Erkrankungen der Zootiere*, Akademie-Verlag, Berlin, Germany, pp. 325-334). Chronic hepatitis was observed frequently, and several prairie dogs were found to have PHC, suggesting a viral etiology similar to that proposed for the woodchuck. The following report summarizes observations on a similar case of PHC in a blacktailed prairie dog from a colony in which three of four prairie dogs were subsequently shown to have chronic hepatitis.

A mature female blacktailed prairie dog died in its pen on February 13, 1979. It was one of seven exhibited as a colony in the Highland Park Zoo, Pittsburgh, Pennsylvania 15206. At postmortem examination a pale, rather homogeneous, yellow mass approximately 5 mm in diameter could be seen on the surface of

the liver and extending into the parenchyma (Fig. 1). The consistency was somewhat more firm than the surrounding, well demarcated hepatic tissue. The lungs were diffusely involved throughout the parenchyma with focal and confluent masses of varying sizes (Fig. 1). These masses were white and seemed somewhat more firm than the hepatic tumor. Other organs and tissues were not remarkable. The hepatic mass (Fig. 2) was clearly a malignant PHC based on the presence of pulmonary metastases which had similar histologic features (Fig. 3). The PHC consisted of hyperchromatic hepatocytes that were arranged in chords. Tubular elements were not seen, nor were bile ducts or ductules. There were vacuoles present throughout the cytoplasm suggestive of fatty changes.

A second prairie dog from the colony was found dead 6 wk following the death of the prairie dog with PHC. At the time of postmortem examination, there was advanced autolysis which precluded microscopic examination of tissues; however, there was no gross evidence of hepatic tumors.

Postmortem examinations were subsequently performed on four other prairie dogs from the colony during the 2 mo following the case of PHC. In none was there evidence of hepatic neoplasia, but in three of the four there were multiple focal areas of round cell infiltration in-

<sup>□</sup> Cooperative Wildlife Research Laboratory, Southern Illinois University, Carbondale, Illinois 62901, USA.

<sup>□</sup> Department of Pathology, New York State College of Veterinary Medicine, Cornell University, Ithaca, New York 14853, USA.

<sup>□</sup> Department of Clinical Sciences, New York State College of Veterinary Medicine, Cornell University, Ithaca, New York 14853, USA.

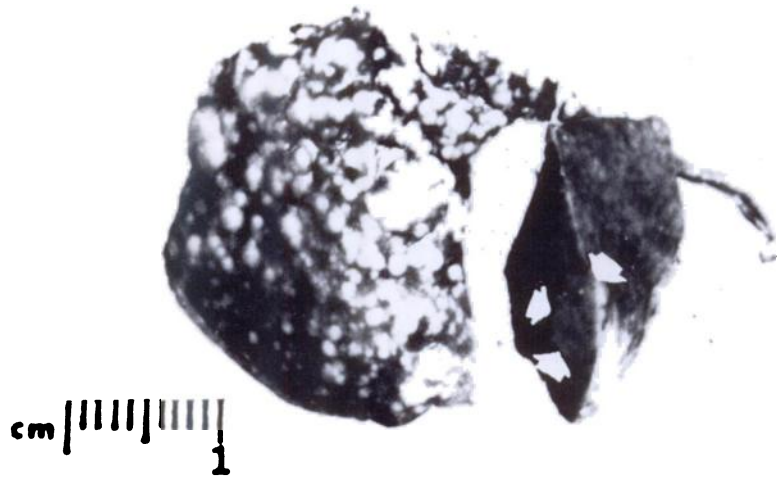


FIGURE 1. The section of liver (right) has a discrete pale 0.5 cm mass (arrows). The other tissue is a portion of lung with many metastatic nodules scattered throughout the parenchyma.

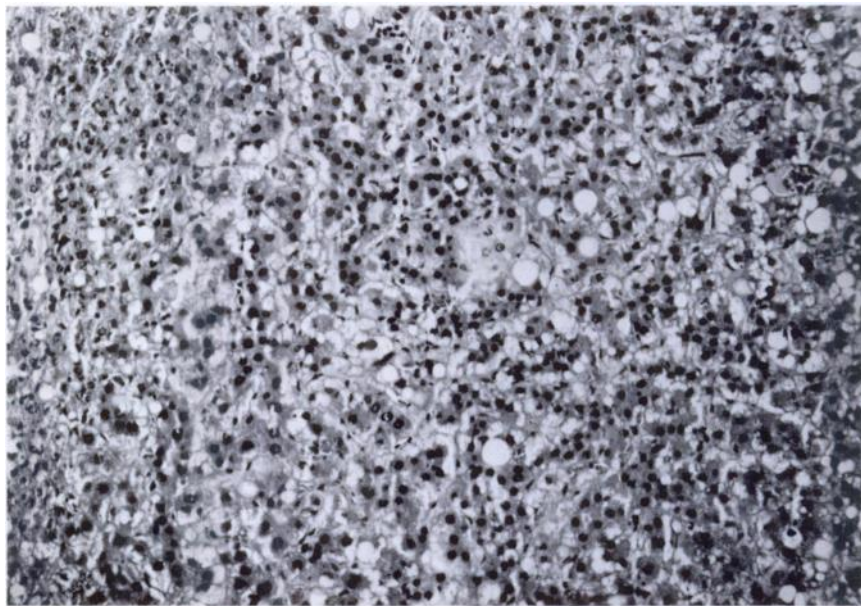


FIGURE. 2. The hepatic neoplasm consists of hyperchromatic hepatocytes; extensive vacuolization is suggestive of fatty change. The top left portion consists of a small zone of slightly compressed, but essentially normal hepatocytes bordering the tumor (150 $\times$ ).

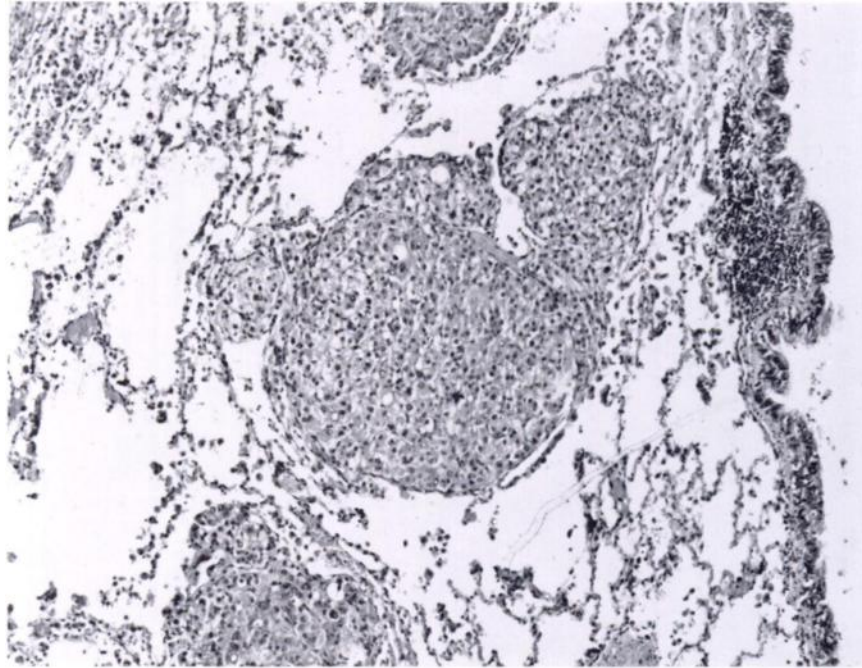


FIGURE 3. Along the right side is the wall of a bronchiole and scattered in the adjacent parenchyma are several nodules of metastatic hepatic PHC cells enclosed within small but dilated pulmonary vessels. The cells in the pulmonary vessels are indistinguishable from those in the liver nodule shown in the preceding photomicrograph (70 $\times$ ).

volving primarily the parenchyma. There was no evidence of portal inflammation or fibrosis. The hepatitis was similar to one of the forms described by Snyder (op. cit.). In his discussion, Snyder indicated that the designation hepatitis has no "special connotation" with respect to etiology and we concur. Further, designation as either acute or chronic can be rather arbitrary; we classified the hepatitis observed as chronic based on a probable duration of several or more months.

The origin of the colony is not certain, but prairie dogs were known to have been purchased from a wild animal dealer. They had been exhibited following purchase with several nine-banded armadillos (*Dasypus novemcinctus*) and

black-tailed jackrabbits (*Lepus californicus*) for a period of 6 mo prior to the death of the subject. No other historical information was available.

Demonstration of the Australia antigen (Blumberg et al., 1965, *J. Am. Med. Assoc.* 191: 541-546; Blumberg et al., 1967, *Ann. Int. Med.* 66: 924-931) and subsequent establishment of its relationship to hepatitis B virus (HBV) has resulted in major advances in knowledge of the pathogenesis of viral hepatitis (Alberti et al., 1979; *Gut*, 20: 190-195; Blumberg et al. 1965, op. cit.; Okuchi and Murakami, 1968, *Vox Sang.* 15: 374-385; Prince, 1968, *Proc. Natl. Acad. Sci.* 60: 814-821). Increasing epidemiological evidence has accumulated which suggests a relationship between HBV

infection and the pathogenesis of PHC (Sherlock et al., 1970, *Lancet*, 1: 1243-1247). This association has been established in several developing regions of the world (Blumberg et al., 1975, *Am. J. Path.* 81: 669-682; Nayak et al., 1977, *Int. J. Cancer*, 20: 643-654; Prince et al., 1975, *Int. J. Cancer*, 16: 376-383) in which the rate of HBV infection is high (Szmunn, 1975, *Am. J. Path.* 81: 629-650) and also exists in the United States where both HBV infection rate and the prevalence of PHC are relatively low (Omata et al., 1979, *Gastroenterology*, 76: 279-287; Tabor et al., 1977, *J. Natl. Cancer Inst.* 58: 1197-1200). On a worldwide basis, PHC appears to be one of the most frequent human malignancies (Linsell and Peers, 1977, Cold Spring Harbor Conf. Cell Proliferation, 4: 549-556; Maupas et al., 1975, *Lancet*, 2: 9-11).

In 1978, a colony of woodchucks at the Philadelphia Zoological Gardens was described which, for a period of 18 yr, had experienced a remarkably high prevalence of chronic hepatitis and in which 23% of animals were found at necropsy to have PHC (Summers et al., op. cit.). In an earlier report, mycotoxin exposure had been tentatively eliminated as an etiologic factor because a similar problem was not observed in other animal species fed the same diet. Based on histologic findings in the liver, a viral etiology was postulated (Snyder, 1968, *Am. J. Path.* 52: 32a-33a). Fifteen percent of woodchuck sera from this colony was shown to contain DNA polymerase activity (Summers et al., op. cit.). It was possible to demonstrate spherical and tubular particles approximately 15 nm in diameter which were similar to the hepatitis B surface antigen, and larger, spherical particles

50 nm in diameter which contained DNA polymerase and which were similar in size and morphological appearance to HBV. The DNA of the particles was similar in size and structure to the DNA of HBV.

Based on these studies, the woodchuck hepatitis virus (WHV) was tentatively classified as the second member of a novel class of viruses which previously was represented only by HBV. The disease associated with WHV infection appeared to be remarkably similar clinically and pathologically to that observed in chronic HBV infection in man.

More recently, a colony of blacktailed prairie dogs also from the Philadelphia Zoological Gardens, has been shown to have an unusually high prevalence of chronic hepatitis and PHC. A close relationship of the disease to that of the woodchuck was recognized and a viral etiology also hypothesized (Snyder, op. cit.).

The cases of PHC and chronic hepatitis described herein are remarkably similar to that previously recorded and suggest a similar etiology. The prairie dog and the woodchuck are closely related phylogenetically (Order: Rodentia; Family: Sciuridae). The recent identification of a viral agent similar to WHV and HBV in the California ground squirrel (*Citellus beecheyi*) (Marion et al., 1980, *Proc. Natl. Acad. Sci.* 77: 2941-2945), also a member of the family Sciuridae, suggests that rodents of this family may be of special value as animal models in the investigation of fundamental mechanisms in the pathogenesis of viral hepatitis and the relationship of this infection to PHC.

*Received for publication 16 July 1981*