BioOne DIGITAL LIBRARY

Evaluation of Two Survey Methods for Detection of Helminth Infections in White-tailed Deer (Odocoileus virginianus)

Authors: SAMUEL, W. M., and BEAUDOIN, R. L.

Source: Bulletin of the Wildlife Disease Association, 2(4) : 100-107

Published By: Wildlife Disease Association

URL: https://doi.org/10.7589/0090-3558-2.4.100

The BioOne Digital Library (https://bioone.org/) provides worldwide distribution for more than 580 journals and eBooks from BioOne's community of over 150 nonprofit societies, research institutions, and university presses in the biological, ecological, and environmental sciences. The BioOne Digital Library encompasses the flagship aggregation BioOne Complete (https://bioone.org/subscribe), the BioOne Complete Archive (https://bioone.org/archive), and the BioOne eBooks program offerings ESA eBook Collection (https://bioone.org/esa-ebooks) and CSIRO Publishing BioSelect Collection (https://bioone.org/csiro-ebooks).

Your use of this PDF, the BioOne Digital Library, and all posted and associated content indicates your acceptance of BioOne's Terms of Use, available at www.bioone.org/terms-of-use.

Usage of BioOne Digital Library content is strictly limited to personal, educational, and non-commmercial use. Commercial inquiries or rights and permissions requests should be directed to the individual publisher as copyright holder.

BioOne is an innovative nonprofit that sees sustainable scholarly publishing as an inherently collaborative enterprise connecting authors, nonprofit publishers, academic institutions, research libraries, and research funders in the common goal of maximizing access to critical research.

Downloaded From: https://complete.bioone.org/journals/Bulletin-of-the-Wildlife-Disease-Association on 07 Jul 2025
Terms of Use: https://complete.bioone.org/terms-of-use

Evaluation of Two Survey Methods for Detection of Helminth Infections in White-tailed Deer (*Odocoileus virginianus*)

W. M. SAMUEL[1] and R. L. BEAUDOIN[2]

The Pennsylvania State University, University Park

Received for publication 28 April, 1966

ABSTRACT

White-tailed deer, *Odocoileus virginianus*, from central Pennsylvania were examined for helminth parasites by regular autopsy procedures supplemented by a direct centrifugal flotation technique. The two methods were compared and evaluated for suitability in diagnosis and survey work. The reliability and repeatability of the flotation method were studied.

Prevalence of most nematodes encountered was increased as a direct result of supplementing autopsy routines with microscopic examination of fecal pellets by the DCF technique. The DCF technique was especially advantageous when dealing with small cryptic forms such as *Ostertagia* sp. and *Capillaria* sp.

INTRODUCTION

Many studies deal with parasites of white-tailed deer, *Odocoileus virginianus* (Karstad, 1964) and the subject has recently been reviewed by Anderson (1962 a,b). Several of these studies contain prevalence data obtained by various survey techniques (Dikmans, 1939; Dinaburg, 1939; Olsen and Fenstermacher, 1943; Samuel and Beaudoin, 1965). Survey techniques employed in these studies include autopsy routines, examination of fecal pellets for eggs or larvae, or a combination of both. To date, however, there has been no attempt to evaluate the reliability of either technique for use in deer studies.

As part of an ecological study on deer parasitism a satisfactory method of surveying a deer population had to be devised and evaluated. The purpose of this study is to examine the efficiency and accuracy of two techniques for detecting helminth infections in the white-tailed deer *Odocoileus virginianus*. This was accomplished by comparing the routine autopsy data with data from fecal examination obtained by means of a direct centrifugal flotation (DCF), when both procedures were performed on the same deer.

[1]Present address: Department of Veterinary Science, University of Wisconsin, Madison, Wisconsin.

[2]Present address: Department of Parasitology, Naval Medical Research Institute, Bethesda, Maryland.

Downloaded From: https://complete.bioone.org/journals/Bulletin-of-the-Wildlife-Disease-Association on 07 Jul 2025
Terms of Use: https://complete.bioone.org/terms-of-use

METHODS AND PROCEDURES

Collection and Storage

Study specimens were collected from deer killed by hunters in December 1963, 1964. Collection sites included deer check stations at the Letterkenny Army Ordnance Depot, Franklin County, Pennsylvania and the Pennsylvania State University Experimental Forest, Huntingdon County, Pennsylvania.

Whenever possible the following autopsy specimens from each of the animals were examined: head, liver, lungs, esophagus, stomach, mesenteries, small intestine, large intestine and caecum.

All autopsy specimens were returned to the laboratory in suitably labelled plastic bags with exception of heads, some lungs and livers which were examined in the field. Fecal pellets taken from the terminal end of the colon were immediately fixed and stored in 10% formalin to prevent further egg development. Autopsy specimens were stored in a standard household freezer until used.

Autopsy Procedures

Examination of organs at autopsy was effected in the following manner: brains were exposed by means of a mid-sagittal cut made with a hack saw, which split the head into two longitudinal halves. The brain was removed, leaving the meninges attached to the skull and exposing their inner surface. Excess blood was removed with water and the inner surface of the meninges and outer surface of the brain were examined for meningeal worms, which are easily seen usually attached to the meninges, especially in the cerebral and hypophysial areas. In freshly killed animals the worms are quite active, facilitating detection.

The liver was examined grossly by scrutinizing the surface for discoloration and other abnormal appearances while bile ducts were slit open and followed as far as possible. In addition, several slices of liver tissue were made at random and studied visually.

Whenever possible, the respiratory tree was removed intact. Excess blood was washed from the surface, and the trachea, bronchi and larger bronchioles were exposed and scraped. Scrapings and washings were examined in a black-bottom pan.

The esophagus was opened, scraped to remove the excess mucous, flushed with water and scraped a second time to uncover *Gongylonema* found embedded in the wall. This parasite was very conspicuous when the above procedures were followed.

The rumen, reticulum and omasum were emptied of their contents and examined by stretching over a bright light. The contents were discarded. The abomasum was repeatedly flushed, scraped and the contents washed, decanted and checked several times in a black-bottom pan.

The small intestine, caecum and large intestine were separately stripped and flushed. The flushings were repeatedly washed and decanted until clear and examined for worms. Mesenteries were washed and stretched over a light for observation.

Nematodes were fixed in hot 10% formalin, cleared and mounted in polyvinyl alcohol (PVA) containing lactic acid. This preparation was found to give quick, excellent results and was particularly effective in making internal structures visible.

Flotation Procedure

A modified Lane direct centrifugal flotation technique, described by Levine *et al.* (1960), was employed with modifications. Ten grams of feces in pellet form were blotted on tissue paper and added to 90 ml of water. A homogeneous suspension was obtained by placing the mixture in a small monel Waring blendor for 7-15 seconds, comminution time, depending on the hardness of the pellets. Pellets were added after the blendor was turned on to keep them from settling below the cutting blades. An aliquot was removed with either a disposable 10-cc stylex syringe whose bore had been widened by removal of the tip, or a bulbed wide-mouth pipette. The aliquot was placed in a 12-ml centrifuge tube and centrifuged at 2200 rpm for about five minutes. The supernatant was poured off and six ml of sugar flotation solution (sp. gr. 1.270), prepared according to Levine *et al* (op. cit.), was added to the sediment and thoroughly mixed by shaking. Additional sugar solution was added to fill the tube to one-fourth inch below the top and the suspension remixed. The suspension was centrifuged two minutes at 1100 rpm. A plug of debris formed at the surface and was loosened from the tube

Downloaded From: https://complete.bioone.org/journals/Bulletin-of-the-Wildlife-Disease-Association on 07 Jul 2025
Terms of Use: https://complete.bioone.org/terms-of-use

wall by ringing with a probe. Additional sugar solution was added, following centrifugation, until a positive meniscus was formed above the lip of the tube. A 22-mm square coverslip was gently placed over the lip of the tube. Removal of the coverslip was made by grasping two adjacent corners by the thumb and forefinger and lifting briskly (Stoll, 1930). Replacing the sugar solution and repeating the procedure at two-minute intervals permitted taking a second, third and fourth coverslip sample. As many as six replicate trials were run on each deer and each trial included four consecutive coverslips, so that up to 24 coverslips were scanned for a single deer.

The flotation coverslips were examined with a 20X ocular and 3.5X objective. The microscope was focused on small air bubbles, enabling examination of the immediate undersurface of the coverslip. Each coverslip was systematically scanned in its entirety for eggs and larvae.

Parasite Identification

Parasites were identified by egg, larva and adult chracteristics (Samuel and Beaudoin, 1965; Shorb, 1939, 1940; Kates and Shorb, 1943; Olsen and Fenstermacher, 1943).

RESULTS

The time required to complete the laboratory portion of the autopsy routine, excluding examination of heads, averaged 66 minutes per animal. Average time required for coverslip examination was 7.5 minutes, for a total average time expended of 30 minutes for each fecal sample.

Of the various helminth species found (Table 1), *Haemonchus contortus* (Rudolphi, 1803) (3/113; 2.7 per cent), *Moniezia expansa* (Rudolphi, 1805) (2/120;

TABLE 1. *Parasite species recovered with their location in the host and stage of development of eggs and larvae in the feces*

Parasite	Location of adult in host	Stage of development of immature forms in feces
Odocoileostrongylus tenuis (Dougherty, 1945)	meningeal and subdural spaces and sinuses	first stage larva
Gongylonema pulchrum Molin, 1857	wall of the esophagus	vermiform embryo
Ostertagia odocoilei Dikmans, 1931	wall and lumen of the abomasum	8-64 cell
Ostertagia mossi Dikmans, 1931	wall and lumen of the abomasum	8-64 cell
Haemonchus contortus (Rudolphi, 1803)	wall and lumen of the abomasum	8-64 cell
Dictyocaulus viviparus (Bloch, 1782)	bronchioles	first stage larva
Nematodirus filicollis (Rudolphi, 1802)	small intestine (duodenum)	8-16 cell
Capillaria sp.	Small intestine	1-2 cell
Trichuris ovis (Abildgaard, 1795)	large intestine and caecum	1-2 cell
Oesophagostomum venulosum (Rudolphi, 1809)	large intestine and caecum	8-64 cell
Moniezia expansa (Rudolphi, 1805)	small intestine	egg
Setaria sp.	abdominal cavity	not present
Taenia sp.[1]	liver and mesenteries[1]	not present
Eimeria spp.	intestine	oocysts

[1]Found in larval stage; tentatively indentified as *Taenia hydatigena* Pallas 1766 on the basis of size and location.

Downloaded From: https://complete.bioone.org/journals/Bulletin-of-the-Wildlife-Disease-Association on 07 Jul 2025
Terms of Use: https://complete.bioone.org/terms-of-use

1.7 per cent), *Setaria* sp. (1/120; 0.83 per cent) and *Taenia* sp. (1/37; 2.7 per cent) were considered as incidental. The flotation technique used was primarily devised to detect nematode eggs. It proved ineffective for detecting infections of *M. expansa,* which were discovered at autopsy. In addition, autopsy procedures alone uncovered the presence of *Setaria* and *Taenia* spp.

Autopsies of 73 livers were negative and a single cysticercus, probably *Taenia hydatigena* (Pallas, 1766, was recovered from 37 mesenteries examined.

Results obtained with multiple trials run upon individual deer are shown in Figure 1. At least three trials were run upon 44 animals, while 4, 5 and 6 trials were run upon 26, 21 and 14 deer respectively. Data obtained by examining four consecutive coverslip preparations from each trial are shown in Figure 2. Thus, for *Nematodirus filicollis* (Rudolphi, 1802), all 11 infections were found on the first trial (Figure 1).

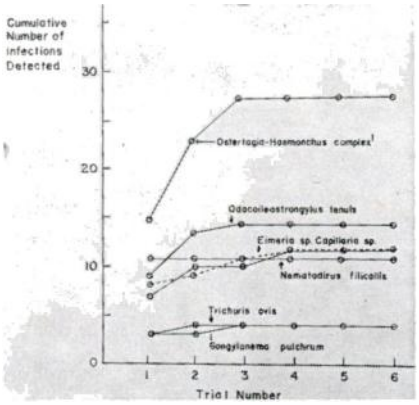

FIGURE 1. *Effect of the number of replicate trials upon the reliability of detecting nematode infections in deer using the direct centrifugal flotation technique.*

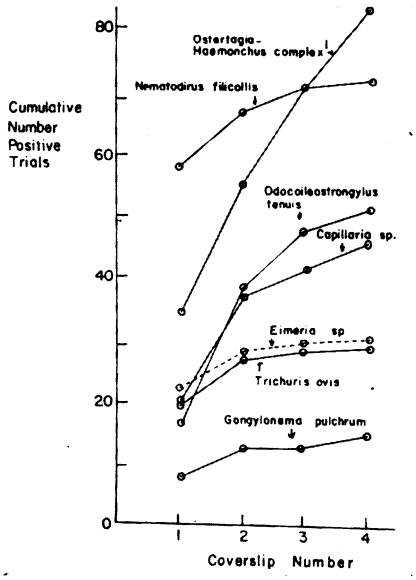

FIGURE 2. *Effect of scanning a series of coverslip preparations from a single trial upon the reliability of detecting nematode infections in deer by the direct centrifugal flotation technique.*

NOTE 1. The complex consists of *Ostertagia odocoilei, O. mossi,* and *Haemonchus contortus,* which have proven difficult to separate on the basis of egg characteristics.

Ninety-three per cent of the detected infections had appeared by the second coverslip (Figure 2). On the other hand, *Ostertagia* spp. yielded four infections on the third trial but only 56 of 84 detected infections (67 per cent) were discovered by the second coverslip.

The repeatability of the flotation technique and hence its usefulness is suggested by comparison of the first trial on deer killed in 1963 with the 1964 prevalence data when only one trial was made on each deer (Table 2). In no cases were significant differences in prevalence between years noted ($p > .05$).

Downloaded From: https://complete.bioone.org/journals/Bulletin-of-the-Wildlife-Disease-Association on 07 Jul 2025
Terms of Use: https://complete.bioone.org/terms-of-use

TABLE 2. *Comparison of flotation results from mece sexamined in* 1963 *and* 1964 *when one sample per deer was accomplished*

Parasite	Prevalence (expressed as %) 1963[a]	1964[b]	Chi sq.
Odocoileostrongylus tenuis	7.35	12.9	1.52 [e]
Gongylonema pulchrum	4.41	4.3	.002[e]
Ostertagia odocoilei, *Ostertagia mossi*, *Haemonchus contortus*[c]	30.9	24.7	.692[e]
Nematodirus filicollis	7.35	3.26	1.54 [e]
Capillaria sp.	8.82	9.68	.04 [e]
Trichuris ovis	1.47		1.47 [e]
Eimeria spp.	13.2 [d]	12.9	.004[e]

[a]Sixty-eight deer examined.

[b]Ninety-three deer examined.

[c]Species determination not reliable using the flotation technique.

[d]Prevalence for 1963 when up to six 10-gram samples were run was 19.1 per cent.

[e]Not statistically significant (p>.05).

In several instances deer were positive for a parasite, using one technique and negative, using the other. For example, *Odocoileostrongylus tenuis* (Dougherty, 1945) larvae were recovered by flotation from three deer but the adults were not found on autopsy (Table 3). Two *Trichuris ovis* (Abildgaard, 1795) infections positive by autopsy and negative by flotation contained single male worms. Likewise, 11 of 16 deer positive for *Oesophagostomum venulosum* (Rudolphi, 1809) by autopsy contained only a few males, showing one disabvantage in using flotation alone. *Capillaria* sp. was detected by egg flotation in 13 deer negative by autopsy. The flotation technique used as a supplement to autopsy routines increased the diagnostic accuracy for all species encountered with the exception of *Dictyocaulus viviparus* (Bloch, 1782), *Oesophagostomum venulo-*

TABLE 3. *Comparison of autopsy with Flotation Techniques when both were accomplished on the same deer.*

Parasite	Number of Deer: Examined by both me'ds.	Positive: By both methods	Positive: by autopsy only	Positive: By flotation only	Negative by both me'ds.
Capillaria sp.	120	2	0	13	105
Dictyocaulus viviparus	114	1	5	0	108
Gongylonema pulchrum	72	6	41	1	24
Nematodirus filicollis	120	7	3	1	109
Odocoileostrongylus tenuis	53	8	32	3	10
Oesophagostomum venulosum	120	2	16	0	102
Ostertagia odocoilei[1] *Ostertagia mossi*[1] *Haemonchus contortus*[1]	113	30	58	3	22
Trichuris ovis	120	1	3	0	116

[1]Species determination between *Ostertagia odocoilei, O. mossi* and *Haemonchus contortus* not reliable using the flotation technique.

Downloaded From: https://complete.bioone.org/journals/Bulletin-of-the-Wildlife-Disease-Association on 07 Jul 2025
Terms of Use: https://complete.bioone.org/terms-of-use

sum (Rudolphi, 1809), and *Trichuris ovis* (Abildgaard, 1795).

DISCUSSION

The data show that supplementing autopsy procedures with a flotation technique increases the accuracy of detecting nematode infections in *O. virginianus* although either procedure is satisfactory for the diagnosis of infection with selected nematodes. If only one procedure is to be used, autopsy is the method of choice for all worms except *Capillaria* sp. Autopsy is both an accurate and an efficient method of uncovering *Gongylonema pulchrum* Molin, 1857, *Oesophagostomum venulosum* (Rudolphi, 1809) and *Dictyocaulus viviparus* (Bloch, 1782) (Table 3) which are large in size and found in easily accessible portions of the deer. In spite of the ease of recovery, *G. pulchrum* has been reported on only one previous occasion (Dikmans and Lucker, 1935), from a single deer in North Carolina. It is reasonable to conclude from the present study that *G. pulchrum* is relatively common in deer in Pennsylvania and probably elsewhere but, occurring in the wall of the esophagus, it has been overlooked.

A recent report by Anderson (1965) indicates that for some age groups *Odocoileostrongylus tenuis* (Dougherty, 1945) may be overlooked at autopsy since mature worms occur in the spinal, subdural and cranial venous sinuses where they are difficult to find. Some of the undetected infections with this worm were discovered through flotation techniques, decreasing the number of false negatives reported in surveys.

Thus, the prevalence of *O. tenuis* in this study was 75% based on autopsy alone but became 81% when both autopsy and flotation procedures were used on the same deer. Using autopsy procedures alone, Alibasoglu *et al.* (1961) showed a similar prevalence (75%) for this parasite in deer from the same area.

For the smaller nematodes in the abomasum and small intestine a combination of both methods should be used. Goldsby and Eveleth (1946) indicate the main disadvantage of postmortem studies to be the failure of finding *Ostertagia* sp. and trichostrongyles which either are too small to see with the naked eye or are buried in the mucous membranes. Anderson (1962b) adds that *Trichuris* sp. is hard to locate in the host, hence they probably occur more frequently than reports would indicate. *Trichuris* sp. has previously been reported from white-tailed deer only twice (Cheatum, 1952; Dinaburg, 1939).

The prevalence of *Capillaria* sp. is best determined by using the flotation technique (Table 3) since the worm is very inconspicuous and standard autopsy procedures often fail to detect light infestations (Cowan, 1946). This probably accounts for the lack of information on infections with this nematode in deer. *Capillaria* has previously been reported only once in deer from Florida by Dinaburg (1939).

Ostertagia odocoilei Dikmans, 1931, *Ostertagia mossi* Dikmans, 1931 and *Haemonchus contortus* (Rudolphi, 1803) data are hard to interpret when based on flotation studies alone since it is not possible to distinguish between the various species of *Ostertagia*, and even difficult to reliably separate

Downloaded From: https://complete.bioone.org/journals/Bulletin-of-the-Wildlife-Disease-Association on 07 Jul 2025
Terms of Use: https://complete.bioone.org/terms-of-use

Ostertagia from *Haemonchus* infections by egg characteristics alone (Samuel and Beaudoin, 1965). *H. contortus* is rarely found in the deer population we studied, and 33 of 88 *Ostertagia* infections uncovered were by the flotation technique alone. This strongly indicates the desirability of microscopic fecal examination as a supplement to routine autopsy.

Although the purpose of the flotation technique is to increase the accuracy in uncovering helminth infections, it has application where only deer feces are available. In such cases microscopic scanning of four coverslips from one 10-gram sample would be sufficient for detection of most infections, other than those of the *Ostertagia-Haemonchus* complex which require up to three trials (12 coverslips) (Figure 1).

The scanning of four successive coverslips per 10-gram sample is adequate for routine purposes (Figure 2). Only in the case of the *Ostertagia-Haemonchus* complex is a large number of infections discovered on the fourth coverslip. It is quite possible that the technique is more suited for detecting one of these species over the others, since the method depends on the specific gravity of the parasite egg or larva being less than that of the flotation medium. Thus, a slight difference in the specific gravity of the eggs of the three species in question would give the step-like recovery observed in Figure 2.

The data on *Eimeria* spp. are included (Table 2) to supplement the scant number of existing references to infections with coccidia in deer (Dahlberg and Guettinger 1956; Forbes, 1961) and to illustrate another application of the DCF technique.

The major shortcomings of the modified DCF technique are: (1) reporting of false negatives (Goldsby and Eveleth, 1946), although this objection is nullified when it is used to supplement autopsy procedures; (2) the technique does not detect the presence of male or immature female worms, which is illustrated clearly in *Oesophagostomum venulosum* infections (Table 3), likewise nullified when used with autopsy; and (3) egg and larval similarities in size, shape and development of some species make specific identification difficult even though detection of infection is possible (Samuel and Beaudoin, 1965; Shorb, 1939).

In using the modified DCF technique certain precautions decidedly increase its reliability. Of these the following deserve mention: (1) care in removing the coverslip, the most delicate step in the Technique (Turner, 1951); (2) use of more than one coverslip for each sample (Stoll, 1930) (Figure 2); (3) variation in duration of fecal comminution in the Waring blendor based on fecal consistency; and (4) variations in time of the last centrifugation based on the amount of fecal debris which in turn affects recovery of eggs.

ACKNOWLEDGEMENT

The authors acknowledge the assistance in various phases of the study of Drs. Davis, Kradel, and Lindzey of the Pennsylvania State University and personnel of the Letterkenny Army Ordinance Depot for help in collecting specimens.

Downloaded From: https://complete.bioone.org/journals/Bulletin-of-the-Wildlife-Disease-Association on 07 Jul 2025
Terms of Use: https://complete.bioone.org/terms-of-use

LITERATURE CITED

ALIBASOGLU, M., KRADEL, D. C. and DUNNE, H. W. 1961. Cerebral nematodiasis in Pennsylvania deer (*Odocoileus virginianus*). Cornell Vet. 51: 431-441.

ANDERSON, R. C. 1962a. The parasites (Helminths and Arthropods) of whitetail deer. Proc. Nat. Whitetail deer disease symposium Feb. 13-15. 1: 162-173.

ANDERSON, R. C. 1962b. The helminth and arthropod parasites of the white-tailed deer (*Odocoileus virginianus*): A general review. Trans. Roy. Canad. Inst. 34: 57-92.

ANDERSON, R. C. 1965. Cerebrospinal nematodiasis (*Pneumostrongylus tenuis*) in North American cervids. Trans. N. Amer. Wildl. Conf. 13: 156-167.

CHEATUM, E. L. 1952. Disease and parasite investigations. Final report, Pittman-Robertson Proj. 1-R, Supplement E. New York State Conser. Dept. 1-75. "Mentioned in review by Anderson, R. C., The helminth and arthropod parasites of the white-tailed deer (*Odocoileus virginianus*): A general review. Trans. Roy. Canad. Inst. 34: 57-92."

COWAN, I. McT. 1946. Parasites, diseases, injuries and anomalies of the columbian black-tailed deer, *Odocoileus hemionus columbianus* Richardson, in British Columbia. Can. J. Research D, 24: 71-103.

DAHLBERG, B. L. and GUETTINGER, R. C. 1956. White-tailed deer in Wisconsin. Wisc. Conserv. Dept. Tech. Wildl. Bull. 14: 119-120.

DIKMANS, G. 1939. Helminth parasites of North American semi-domesticated and wild ruminants. Proc. Helminth. Soc. Washington, D. C. 6 (2): 97-101.

DIKMANS, G. and LUCKER, J. T. 1953. New records of nematode parasites from deer in the United States. Proc. Helminth Soc. Washington, D. C. 2: 83.

DINABURG, A. G. 1939. Helminth parasites collected from deer *Odocoileus virginianus* in Florida. Proc. Helminth Soc. Washington, D. C. 6: 102-104.

FORBES, S. E. 1961. Diseases and parasites of the Pennsylvania white-tailed deer. Penna. Game News 32 (12): 42-46.

GOLDSBY, A. I. and EVELETH, D. F. 1946. Diagnosis of internal parasites of sheep. Vet. Med. 41: 391-403.

KARSTAD, L. (editor) 1964. Diseases of the cervidae: a partly annotated bibliography. Wildl. Dis. 43: 1-233.

KATES, K. C. and SHORB, D. A. 1943. Identification of eggs of nematodes parasitic in domestic sheep. Amer. J. Vet. Res. 4(10): 54-60.

LEVINE, N. D., MEHRQ, K. N., CLARK, D. T. and AVES I. 1960. A comparison of nematode egg counting techniques for cattle and sheep feces. Amer. J. Vet. Research 21(82): 511-515.

OLSEN, O. W. and FENSTERMACHER, R. 1943. The helminths of North American deer with special reference to those of white-tailed deer (*Odocoileus virginianus borealis*) in Minnesota. Tech. Bull. (159). Minnesota Agric. Exper. Station. 20 pp.

SAMUEL, W. M. and BEAUDOIN, R. L. 1965. Identification of eggs and larvae of nematodes parasitic in deer in Pennsylvania. Proc. Penna. Acad. Sci., in press.

SHORB, D. A. 1939. Differentiation of eggs of various genera of nematodes parasitic in domestic ruminants in the United States. U. S. Dept. Agr. Tech. Bull. 694: 1-10.

SHORB, D. A. 1940. A comparative study of the eggs of various species of nematode parasites in domestic ruminants. J. Parasitol. 26: 223-231.

STOLL, N. R. 1930. On methods of counting nematode ova in sheep dung. Parasitol. 22 (1): 13-136.

TURNER, J. H. 1951. Counting *Nematodirus spathiger* eggs in sheep dung. Proc. Helminth. Soc. Washington, D. C., 18: 132-136.

Downloaded From: https://complete.bioone.org/journals/Bulletin-of-the-Wildlife-Disease-Association on 07 Jul 2025
Terms of Use: https://complete.bioone.org/terms-of-use