

Spontaneous Papillomatosis in Domestic Rabbits 1

Author: HAGEN, KARL W.

Source: Bulletin of the Wildlife Disease Association, 2(4) : 108-110

Published By: Wildlife Disease Association

URL: <https://doi.org/10.7589/0090-3558-2.4.108>

The BioOne Digital Library (<https://bioone.org/>) provides worldwide distribution for more than 580 journals and eBooks from BioOne's community of over 150 nonprofit societies, research institutions, and university presses in the biological, ecological, and environmental sciences. The BioOne Digital Library encompasses the flagship aggregation BioOne Complete (<https://bioone.org/subscribe>), the BioOne Complete Archive (<https://bioone.org/archive>), and the BioOne eBooks program offerings ESA eBook Collection (<https://bioone.org/esa-ebooks>) and CSIRO Publishing BioSelect Collection (<https://bioone.org/csiro-ebooks>).

Your use of this PDF, the BioOne Digital Library, and all posted and associated content indicates your acceptance of BioOne's Terms of Use, available at www.bioone.org/terms-of-use.

Usage of BioOne Digital Library content is strictly limited to personal, educational, and non-commercial use. Commercial inquiries or rights and permissions requests should be directed to the individual publisher as copyright holder.

BioOne is an innovative nonprofit that sees sustainable scholarly publishing as an inherently collaborative enterprise connecting authors, nonprofit publishers, academic institutions, research libraries, and research funders in the common goal of maximizing access to critical research.

Spontaneous Papillomatosis in Domestic Rabbits¹

KARL W. HAGEN

Animal Disease Research Laboratory, Animal Disease and Parasite Research Division, A.R.S., U.S.D.A., Washington State University, Pullman

Received for publication 9 May, 1966

ABSTRACT

Infectious papillomatosis is an enzootic virus disease of wild cottontail (*Sylvilagus*) rabbits. What is believed to be the first naturally-occurring infection of domestic rabbits is reported, and enzootic infection of the California cottontail rabbit with this virus is suggested.

Rabbit papillomatosis is an enzootic disease of cottontail rabbits (Shope, 1933). Geographically, the disease is found in the wild rabbits of Kansas, Iowa, Oklahoma, and Texas. The domestic rabbit and the jack rabbit (*Lepus californicus*) are also susceptible to this disease (Beard and Rous, 1935). While the virus can be obtained easily from the growths on cottontail rabbits, it is usually not recoverable from papillomas on domestic rabbits. Domestic rabbits are easily infected with the wild cottontail rabbit virus (WRV), but successive passages are usually not successful (Selbie and Robinson, 1947; Shope, 1935). The purpose of this report is to describe cases of naturally-occurring papillomatosis in domestic rabbits raised in Southern California.

CLINICAL SIGNS AND GROSS PATHOLOGY

During the month of November 1960, a mature, male New Zealand White rabbit (*Oryctolagus cuniculus*) was observed to have numerous horn-like protuberances on the skin of the left ear (Fig. 1). These horn-like growths caused no apparent discomfort to the animal and no evidence of generalized illness was noted. During the next 18 months, with attention drawn to this condition, seven more domestic rabbits in four different rabbitries were found to have papillomas. Each rabbitry was located in an agricultural area and was surrounded by open fields on at least two-thirds of the perimeter. Wild rabbits were known to be in the area and several growers reported seeing wild rabbits on their properties.

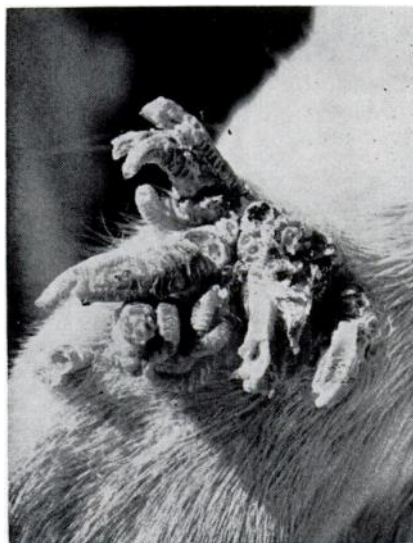


FIGURE 1. Papilloma on ear of rabbit G-1.

¹This research was accomplished when the author was located at the U. S. Rabbit Experiment Station (closed June 1965), ADP, ARS, USDA, Fontana, California.

The most common sites for these growths were the ears and eyelids, and the growths varied in both size and conformity (Fig. 2). The growths were well keratinized and the upper surfaces were irregular and often split. The lower portions of the growths were fleshy to the touch and pinkish in color. The lateral surfaces appeared to be striated. As the lesions became older they increased in size, became more cornified, and were hard to the touch. On the cut section, the growth had a pink, fleshy center. These growths were easily scratched off by the rabbits or knocked off when the rabbits were handled. Growths removed this way left a free-bleeding surface which usually healed without complications. On two occasions, a second growth appeared at the site of the original lesion.

RESISTANCE OF INFECTED RABBITS TO REINFECTION

The stock virus preparation was supplied by Dr. Robert S. Stone, Department of Pathology, UCLA Medical Center, Los Angeles, California. It was a 10% suspension made from stored, cottontail rabbit tumor tissues. Rabbits to be inoculated were shaved on the abdomen and the skin was lightly scarified with sandpaper. The scratches were made only deep enough to cause a light oozing of blood tinged fluid. A small amount of diluted WRV suspension was applied immediately and rubbed into the scarifications. After the inoculated areas had dried, the rabbits were returned to their cages and were examined at weekly intervals. Wild cottontail rabbits were used as virus controls.

Rabbits with active papilloma infection were completely or partially resistant to reinfection and

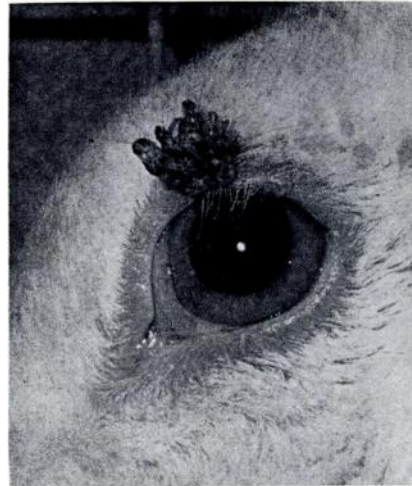

FIGURE 2. Lesion on eyelid of rabbit G-2.

produce antibodies capable of completely or partially neutralizing the papilloma virus. Six domestic rabbits with papillomas of varying stages were tested for resistance to reinfection with wild cottontail rabbit virus (Table 1). All six domestic rabbits resisted reinfection, while the wild cottontail rabbits used as the virus controls developed typical growths 20 to 30 days following inoculation.

In nature, rabbit papillomatosis is transmitted by the rabbit tick, (Larson *et al.*, 1936). Under laboratory conditions it has been transmitted by the mosquito, *Aedes aegypti*, and the reduviid bugs, *Rhodnius prolixus*, and *Triatoma infestans* (Dalmat, 1958). The manner in which the domestic rabbit is raised commercially would probably exclude the tick and the reduviid bugs as vectors involved. Mosquitoes usually will not feed on densely haired areas and, therefore, are limited to probing in areas on the nose, tips and edges of the ears and the vent. In

a fibroma-enzootic area, free-fly-ing, infected mosquitoes were able to transmit the virus so that lesions appeared on the ears, nose and legs of wild rabbits (Kilham and Dalmat, 1955). Since this is

a known enzootic area for another insectborne rabbit virus disease, myxomatosis, the transmission of papilloma virus from the wild cottontail rabbit to the domestic rabbit by the mosquito is suggested.

TABLE 1. Summary of case histories and wild rabbit virus challenges.

Rabbit No.	Sex	Lesion		Wild Rabbit Virus Challenge		Notes
		Date	Location	Date	Results	
G-1 (V)*	M	11/14/60	L. ear ad- vanced	—	—	No virus transm. to domestic rabbit.
G-2 (V)	F	3/ 8/62	L. eyelid	3/ 5/63	Immune	Growths broken off, did not return.
1-1 (SM)**	M	2/ - /61	R. ear ad- vanced	7/10/63	Immune	Growth cut back twice, then healed. No virus transm. to DR.
L-1 (V)	F	6/21/62	R. ear	8/30/62	Immune	Growths broken off, did not return.
L-2 (V)	F	6/21/62	R. & L. ear	3/ 5/63	Immune	Growths broken off, did not return.
M-1 (V)	F	3/ 8/62	R. ear ad- vanced	8/30/62	Immune	Growths cut back, regrew, developed secondary infection
M-2 (V)	F	3/ 8/62	L. ear	—	—	Growths broken off, did not return.
M-3 (V)	F	3/ 8/62	R. ear	3/ 5/63	Immune	Growths broken off, did not return.

* (V), Vista, San Diego County.

** (SM), San Marcos, San Diego County.

ACKNOWLEDGMENT

The author is indebted to Dr. Robert S. Stone, UCLA Medical Center, Los Angeles, California, for his assistance and advice, and to Mr. R. E. Job, 5 J's Ranch, Claremont, California for supplying the wild cottontail rabbits.

LITERATURE CITED

- BEARD, J. W. and ROUS, P., 1935. Effectiveness of the Shope papilloma virus in various American rabbits. *Proc. Soc. Exptl. Biol. Med.* 33:191-193.
- DALMAT, H. T. 1958. Arthropod transmission of rabbit papillomatosis. *J. Exptl. Med.* 108:9-20.
- KILHAM, L., and DALMAT, H. T. 1955. Host-virus-mosquito relations of Shope fibromas in cottontail rabbits. *Amer. J. Hyg.* 61:45-54.
- LARSON, C. L., SHILLINGER, J. E., and GREEN, R. C. 1936. Transmission of rabbit papillomatosis by the rabbit tick, *Haemaphysalis leporis palustris*. *Proc. Soc. Exptl. Biol. Med.* 33:536-538.
- SELBIE, F. R., and ROBINSON, R. H. M. 1947. Serial transmission of infectious papillomatosis in the domestic rabbit. *Brit. J. Cancer* 1:371-379.
- SHOPE, R. E. 1933. Infectious papillomatosis of rabbits. With a note on the histopathology by E. W. Hurst. *J. Exptl. Med.* 58:607-624.
- SHOPE, R. E. 1935. Serial transmission of virus of infectious papillomatosis in domestic rabbits. *Proc. Soc. Exptl. Biol. Med.* 32:830-832.