

Severe Disseminated Aspergillosis in a Captive Abyssinian Tawny Eagle (*Aquila rapax raptor*)

Authors: Fatunmbi, O. O., and Bankole, A.

Source: Journal of Wildlife Diseases, 20(1) : 52-54

Published By: Wildlife Disease Association

URL: <https://doi.org/10.7589/0090-3558-20.1.52>

The BioOne Digital Library (<https://bioone.org/>) provides worldwide distribution for more than 580 journals and eBooks from BioOne's community of over 150 nonprofit societies, research institutions, and university presses in the biological, ecological, and environmental sciences. The BioOne Digital Library encompasses the flagship aggregation BioOne Complete (<https://bioone.org/subscribe>), the BioOne Complete Archive (<https://bioone.org/archive>), and the BioOne eBooks program offerings ESA eBook Collection (<https://bioone.org/esa-ebooks>) and CSIRO Publishing BioSelect Collection (<https://bioone.org/csiro-ebooks>).

Your use of this PDF, the BioOne Digital Library, and all posted and associated content indicates your acceptance of BioOne's Terms of Use, available at www.bioone.org/terms-of-use.

Usage of BioOne Digital Library content is strictly limited to personal, educational, and non-commercial use. Commercial inquiries or rights and permissions requests should be directed to the individual publisher as copyright holder.

BioOne is an innovative nonprofit that sees sustainable scholarly publishing as an inherently collaborative enterprise connecting authors, nonprofit publishers, academic institutions, research libraries, and research funders in the common goal of maximizing access to critical research.

TABLE 1. Occurrence of lymphocystis on Caribbean marine fishes.

Host	Locality (date)
<i>Pomacentrus partitus</i> Poey	Crashboat, Aguadilla (30 Jan. 1976), Sardinera, Mona Island (23 April 1976), shelf edge off La Parguera (6 Jan. 1977), Carbi-nero, Mona Island (25 May 1977), Laurel Reef, La Parguera (15 Sept. 1977), Puerto Rico; Dolphin Point, Saona Island (18 May 1979), Dominican Republic
<i>Hypoplectrus nigricans</i> (Poey)	Mario Reef, La Parguera, Puerto Rico (2 Sept. 1977)
<i>Chaetodon ocellatus</i> Bloch	Bank Reef off St. James, Barbados (3 June 1981)
<i>Apogon quadrisquamatus</i> Longley	Laurel Reef, La Parguera, Puerto Rico (7 Jan. 1982)

fectured individuals appeared to behave normally and were no more easily collected than uninfected individuals of the same species.

Thanks are expressed to Michael J. Dowgiallo and Joseph J. Kimmel for collecting four of the infected hosts. Special thanks are extended to Drs. John A. Plumb, Auburn University, and Raymond E. Waldner, Palm Beach Atlantic College, for review of the manuscript. Support was

provided by grant number 8852 from the American Philosophical Society, a grant from the President of the University of Puerto Rico, Dr. Ismael Almodovar, and National Science Foundation Grant OCE 78-07899. Laboratory and field equipment and assistance were provided by Centro de Investigaciones de Biología Marina, Dominican Republic; Discovery Bay and Port Royal Marine Laboratories, Jamaica.

Journal of Wildlife Diseases, 20(1), 1984, pp. 52-54
© Wildlife Disease Association 1984

Severe Disseminated Aspergillosis in a Captive Abyssinian Tawny Eagle (*Aquila rapax raptor*)

O. O. Fatunmbi and A. Bankole, Department of Veterinary Medicine, University of Ibadan, Ibadan, Nigeria

Aspergillosis is a mycotic disease of avian species which has been recognized as an acute or chronic infection since the early 1800's (O'Meara and Witter, 1971, *In Infectious and Parasitic Diseases of Wild Birds*, Davis et al. (eds.), Iowa State Univ. Press, Ames, Iowa, pp. 153-162). It has been reported commonly in both wild and domestic birds (Ainsworth and Rewell, 1949, *J. Comp. Pathol.* 59: 213-214),

recently captured wild birds (Friend and Trainer, 1969, *Bull. Wildl. Dis. Assoc.* 5: 261-275) and free-living birds of the anseriform, larid, gallinaceous and passeriform groups (McDiarmid, 1955, *J. Comp. Pathol.* 65: 246-249; O'Meara and Witter, 1971, op. cit.; Rosen, 1964, *Avian Dis.* 8: 1-6).

There is little information about the occurrence of aspergillosis in free-living raptors, but the disease has been reported in the bald eagle (*Haliaeetus leucoceph-*

Received for publication 15 April 1983.



FIGURE 1. Concave plaques (arrows) of *Aspergillus fumigatus* in a captive tawny eagle.

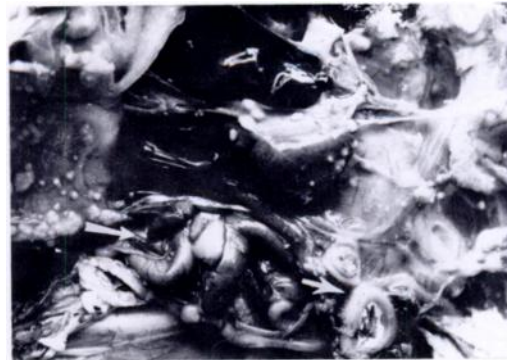

FIGURE 2. Extensive plaque formation with adhesion (arrows) of organs in the abdominal cavity of a captive tawny eagle.

alus), martial eagle (*Polemaetus bellicosus*), European sparrow hawk (*Accipiter nisus*), tawny owl (*Strix aluco*), barn owl (*Tyto alba*) and golden eagle (*Aquila chrysaetos*) (Coon and Locke, 1968, Bull. Wildl. Dis. Assoc. 4: 51; Cooper, 1969, Vet. Rec. 84: 454–457; Keymer, 1972, Vet. Rec. 90: 579–594; MacDonald, 1965, Bird Study 12: 181–195; O'Meara and Witters, 1971, op. cit.; Waterston, 1959, Br. Birds 52: 197). However, there appear to be no references on aspergillosis in Abyssinian tawny eagles. This communication therefore reports its occurrence in a captive Abyssinian tawny eagle.

On 3 April 1982, two recently purchased Abyssinian tawny eagles were introduced into the Zoological Garden of the University of Ibadan, Nigeria. The eagles were captured in the wild in northern Nigeria and subsequently transported by road in a wooden cage from Kano suburb to Ibadan, a distance of about 1,033 km.

They were fed raw goat meat once a day and clean potable water was supplied ad lib. in plastic dishes. The two eagles were housed in a cage (4.2 m × 1.2 m) partitioned into two adjacent rooms. Poles were placed in a criss-cross fashion to serve as perches in the rooms.

The birds appeared healthy before and after purchase from their captors. They were, however, showing some clinical signs

24 days after they arrived in Ibadan. These included dullness, ruffled feathers, tucked-up heads, anorexia, gasping, droopiness of wings, emaciation, diarrhea and dyspnea which was accompanied with gurgling sounds. A day after the commencement of clinical signs, one eagle died and was submitted for post mortem examination.

At necropsy, *Aspergillus* plaques were common in all the organs. The plaques varied from pinhead size to about 3.0 cm in diameter and from spongy soft to hard. The form of the plaques varied from a nearly spherical nodule to concave or flattened discs (Fig. 1). The plaques were gray-greenish in color and those with depressions in the centers of the lesions were filled with greenish material which contained conidiophores. Most lesions were firmly attached usually within or on the surface of the organs. However, some were very loosely attached in the mesentery. There was an extensive plaque formation and nodules in the peritoneum producing peritonitis with adhesions (Fig. 2). A plaque was found at the bifurcation of the trachea but within its lumen. Sections were cut from the infected spleen and lungs after fixing in 10% formalin and stained with methamine hexamine silver nitrate and haematoxylin eosin.

Direct examinations of the lesions in 10% sodium hydroxide were made with

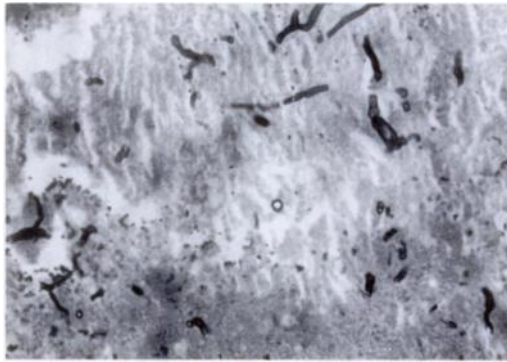


FIGURE 3. Granulomatous lesions showing septate branching hyphae of *Aspergillus fumigatus* in infected lung of a captive tawny eagle. $\times 800$.

the aid of a light microscope. Smears of the lesions were made onto a microscope slide, fixed by heat and stained by the Ziehl-Neelsen method. Swabs were taken from the lesions observed in the spleen, liver and lung for microbiological study. These were subsequently inoculated onto blood agar and Sabouraud's agar and incubated at 37 C.

Histopathological examination of the infected lung and spleen revealed a granulomatous reaction with a necrotic center showing the branching hyphae (Fig. 3). Microscopic examination of the lesions in 10% sodium hydroxide revealed short pieces of thick, septate hyphae characteristic of *Aspergillus* species. Smears made from the lesions and stained by the Ziehl-

Neelsen method did not show any acid-fast organisms. The culture yielded fungus growth with white colonies at first which later turned greenish and velvety after about 60 hr. The fungus was examined microscopically and identified as *Aspergillus fumigatus* (Raper and Fennel, 1965, *The Genus Aspergillus*, Williams and Wilkins, Baltimore, Maryland, 330 pp.). No bacteria of pathological significance were cultured.

The plaques found in the viscera (Figs. 1 and 2) and the isolation of *Aspergillus fumigatus* from the lesions confirmed a diagnosis of generalized disseminated aspergillosis which subsequently led to the death of the eagle. It has been suggested that under physiological stress such as provided by adverse conditions of management and transportation, aspergillosis could be very fatal in recently captured wild birds (O'Meara and Witter, 1971, op. cit.). This could explain the fatal nature of this disease in this recently captured eagle especially when it had been subjected to stress of captivity and transportation. The gurgling sounds which accompanied the dyspnea were due to the location of an *Aspergillus* plaque in the trachea. This is not commonly a feature of the respiratory form of aspergillosis (Redig, 1981, *In Recent Advances in the Study of Raptor Diseases*, Cooper and Greenwood (eds.), Chiron Publications Ltd., Keighly, England, pp. 117-122).