

Polypoid Gastritis in a Scaly Anteater Caused by Larvae of *Gendrespirura* sp.

Authors: Gardiner, C. H., and Werner, R. M.

Source: Journal of Wildlife Diseases, 20(1) : 68-70

Published By: Wildlife Disease Association

URL: <https://doi.org/10.7589/0090-3558-20.1.68>

The BioOne Digital Library (<https://bioone.org/>) provides worldwide distribution for more than 580 journals and eBooks from BioOne's community of over 150 nonprofit societies, research institutions, and university presses in the biological, ecological, and environmental sciences. The BioOne Digital Library encompasses the flagship aggregation BioOne Complete (<https://bioone.org/subscribe>), the BioOne Complete Archive (<https://bioone.org/archive>), and the BioOne eBooks program offerings ESA eBook Collection (<https://bioone.org/esa-ebooks>) and CSIRO Publishing BioSelect Collection (<https://bioone.org/csiro-ebooks>).

Your use of this PDF, the BioOne Digital Library, and all posted and associated content indicates your acceptance of BioOne's Terms of Use, available at www.bioone.org/terms-of-use.

Usage of BioOne Digital Library content is strictly limited to personal, educational, and non-commercial use. Commercial inquiries or rights and permissions requests should be directed to the individual publisher as copyright holder.

BioOne is an innovative nonprofit that sees sustainable scholarly publishing as an inherently collaborative enterprise connecting authors, nonprofit publishers, academic institutions, research libraries, and research funders in the common goal of maximizing access to critical research.

Simpson et al. (1983, op. cit.) reported a significant reduction (38.1%) in feed intake by red deer calves on the first day after injection with 0.8 mg/kg xylazine hydrochloride, but not thereafter. Card (1981, Nutritional influences on blood characteristics in white-tailed deer, M.S. Thesis, Virginia Polytech. Inst. and State Univ., Blacksburg, Virginia, 181 pp.) used 0.5 mg/kg xylazine hydrochloride to immobilize adult male white-tailed deer in two experiments, and observed a suppression in feed intake (50–55%) on the day after injection. Three days were required for feed intake to return to pre-injection levels. We observed a 97.9% reduction in feed intake by ad libitum-fed deer on the day after injection, and the reduction remained significant for the first week after injection. Since we used higher doses of xylazine hydrochloride than were used in the other studies, the possibility of a dose-response relationship exists.

In sheep, the anorexia-inducing effect of xylazine hydrochloride is thought to be caused by reduced plasma insulin concentrations and elevated plasma glucagon concentrations, which elevate plasma glucose concentrations (Brockman, 1981, Res. Vet. Sci. 30: 383–384). Hsu and Hummel

(1981, Endocrinology 109: 825–829) reported a dose-response relationship for xylazine hydrochloride-induced hyperglycemia and hypoinsulinemia in cows, and concluded that this effect is mediated by α -2-adrenergic receptors in β -cells of pancreatic islets.

Comparable data on white-tailed deer are unavailable, but the physiological mechanisms may be similar. Mautz et al. (1980, J. Wildl. Manage. 44: 343–351) and Gibson (1980, Clinical and physiological assessment of xylazine hydrochloride (Rompun) applications in captive white-tailed deer with emphasis on handling stress, M.S. Thesis, Virginia Polytech. Inst. and State Univ., Blacksburg, Virginia, 272 pp.) reported significant elevations in plasma glucose of white-tailed deer immobilized with xylazine hydrochloride. The physiological adaptation whereby the 75% ad libitum-fed deer were able to more quickly overcome the anorexia-inducing effect of xylazine hydrochloride remains to be determined.

This study was supported by the Pratt Animal Nutrition Foundation at Virginia Polytechnic Institute and State University. We thank A. Oelschlaeger and T. Jones for assistance.

Journal of Wildlife Diseases, 20(1), 1984, pp. 68–70
© Wildlife Disease Association 1984

Polypoid Gastritis in a Scaly Anteater Caused by Larvae of *Gendrespirura* sp.

C. H. Gardiner, Department of Veterinary Pathology, Armed Forces Institute of Pathology, Washington, D.C. 20306, USA; and R. M. Werner, Small Animal Section, Veterinary Resources Branch, National Institutes of Health, Bethesda, Maryland 20205, USA

A malnourished scaly anteater (*Manis javanicus*) was kept in captivity at the U.S.

Received for publication 1 July 1983.

Army Medical Research Unit, Kuala Lumpur, Malaysia. The condition of the animal progressively deteriorated and it died 2 wk after capture. At necropsy an

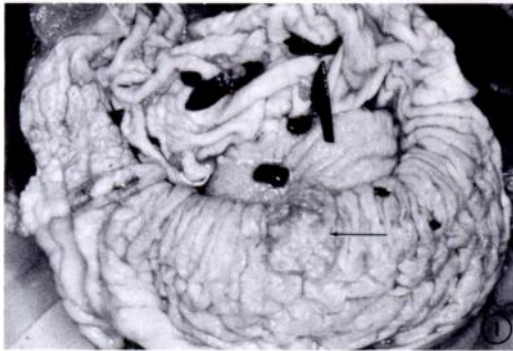


FIGURE 1. A cauliflower-like sessile polyp (arrow) protruding from the gastric mucosa of a scaly anteater. (AFIP Neg. #81-13674-1)

oval polypoid cauliflower-like nodule, measuring 1.5 cm in diameter, was noted on the mucosal surface of the stomach (Fig. 1). The nodule was fixed in 10% buffered formalin and submitted for histologic processing.

Histologically, the keratin layer of the mucosal epithelium was greatly thickened (Fig. 2). Numerous sections of nematode larvae were present in tracts in the upper lamina propria and epithelium (Figs. 2 and 3). The larvae were often surrounded by abundant neutrophils and macrophages

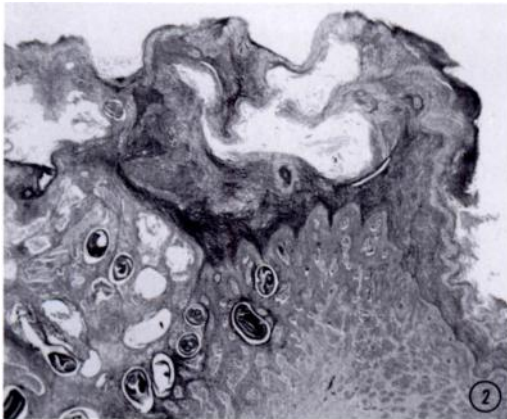


FIGURE 2. Histological section of polyp in the stomach of a scaly anteater. Note hyperplastic epithelium containing numerous nematode larvae. Hematoxylin and eosin H&E, $\times 25$. (AFIP Neg. #83-7361)

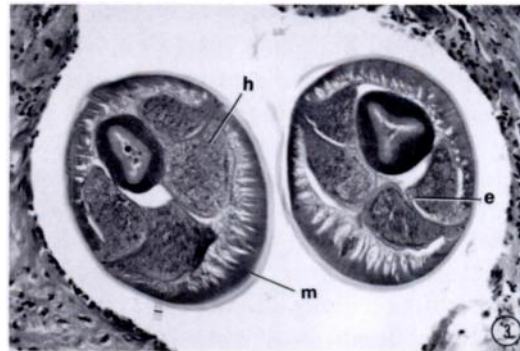


FIGURE 3. Histological section of coiled larva in polyp in the stomach of a scaly anteater. Note coelomyarian muscles (m), large pedunculated hypodermal chords (h), and excretory canal (e). H&E, $\times 250$. (AFIP Neg. #81-14911)

with fewer eosinophils and lymphocytes. Moderate ballooning degeneration of epithelial cells was also present. The larvae measured $200 \mu\text{m}$ in greatest diameter and had the following morphologic features:

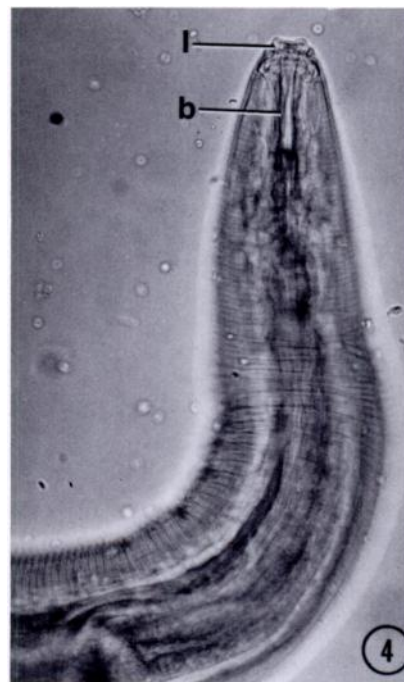


FIGURE 4. Optical section through anterior end of larva of *Gendrespirura* sp. cleared in glycerine. Note bilobed lip (1) and buccal cavity (b). $\times 155$. (AFIP Neg. #81-14910)

A thick cross-striated cuticle, coelomyarian musculature and very large lateral chords which protruded into the pseudo-coelom. The chords were divided into sublaterals and contained a prominent excretory canal. Fragments of larvae were teased from formalin fixed tissue. In lateral view (Fig. 4) the mouth of the larva was surrounded by two large, round, bilobed lips. A long buccal cavity, approximately 80 μm long, extended from the mouth to the esophagus. The larvae had characteristics of Spirurida and were identified as *Gendrespirura* sp. (Chabaud, 1958, Ann. Parasitol. Hum. Comp. 33: 445–508; Chabaud, 1975, CIH Keys to the Nematode Parasites of Vertebrates, No. 3, Pt. 2, Commonwealth Agricultural Bureaux, Farnham Royal, Slough, England, 30 pp.). Representative specimens have been deposited in the U.S. National Parasite Collection, Beltsville, Maryland 20705, USA (Accession No. 77695).

There are several reports of *Gendrespirura* (published as *Habronema*) *hamospiculata* in scaly anteaters (Baylis, 1931, Ann. Mag. Nat. Hist. 8: 191–194; Hsu, 1932, Peking Nat. Hist. Bull. 7: 99–115; Baylis, 1936, Ann. Mag. Nat. Hist. 17: 257–272; Vuylsteke, 1956, Rev. Zool. Bot. Afr. 53: 441–447; Le Van Hoa, 1962, Mission (de Witte) (1946–1949) Explor. Parc. Nat. Upemba, 65: 3–58; Rasheed, 1965, J. Helminthol. 39: 349–362; Myers and Kuntz, 1969, Can. J. Zool. 47: 419–421; Kamara, 1975, Bull. Anim. Health Prod. Afr. 23: 265–268). All but the last two reports were from African anteaters. Since fourth stage larvae of *Gendrespirura* have not been described from Asian anteaters it remains undetermined if the species in this case is *G. hamospiculata*. The polypoid lesion due to this parasite has not been described in any of these reports.

Journal of Wildlife Diseases, 20(1), 1984, pp. 70–72
© Wildlife Disease Association 1984

Insulin-producing Islet Cell Tumor in an Ectopic Pancreas of a Red Fox (*Vulpes vulpes*)

Kari Elvestad, Section of Wildlife Diseases, State Veterinary Serum Laboratory, Copenhagen, Denmark; and **Ulrik V. Henriques and Jens Peter Kroustrup**, University Institute of Pathology, Aarhus, Denmark

In May 1981, a young female red fox, exhibiting convulsions and salivation, was killed and examined at necropsy. It was in a good state of nutrition. One-fourth of the tail was missing, but the wound seemed to have healed without complications. The lungs were congested. The liver was swollen and showed a few lesions from ascarid larvae. The adrenal glands were hypertrophic. The kidneys were red in color. The pancreas appeared normal. In the mesentery, attached to the colon, a tumor,

measuring approximately $3 \times 3 \times 3$ cm and resembling a lymph node, was seen. No other tumors were observed.

No bacteria were demonstrated in the brain, the liver or the tumor by cultivation on blood agar and Conradi-Drigalski agar plates. Examination for Aujeszky's disease using tissue culture was negative. So was examination for organophosphorus insecticides using pralidoxime-induced reactivation of brain cholinesterases, and for canine distemper and toxoplasmosis using smears stained with hematoxylin and Shorr's differential stain.

Received for publication 18 January 1983.