

Dermatophilosis in a Mule Deer, *Odocoileus hemionus* (Rafinesque), from Wyoming

Authors: Williams, Elizabeth S., Pier, A. C., and Wilson, Roger W.

Source: Journal of Wildlife Diseases, 20(3) : 236-238

Published By: Wildlife Disease Association

URL: <https://doi.org/10.7589/0090-3558-20.3.236>

The BioOne Digital Library (<https://bioone.org/>) provides worldwide distribution for more than 580 journals and eBooks from BioOne's community of over 150 nonprofit societies, research institutions, and university presses in the biological, ecological, and environmental sciences. The BioOne Digital Library encompasses the flagship aggregation BioOne Complete (<https://bioone.org/subscribe>), the BioOne Complete Archive (<https://bioone.org/archive>), and the BioOne eBooks program offerings ESA eBook Collection (<https://bioone.org/esa-ebooks>) and CSIRO Publishing BioSelect Collection (<https://bioone.org/csiro-ebooks>).

Your use of this PDF, the BioOne Digital Library, and all posted and associated content indicates your acceptance of BioOne's Terms of Use, available at www.bioone.org/terms-of-use.

Usage of BioOne Digital Library content is strictly limited to personal, educational, and non-commercial use. Commercial inquiries or rights and permissions requests should be directed to the individual publisher as copyright holder.

BioOne is an innovative nonprofit that sees sustainable scholarly publishing as an inherently collaborative enterprise connecting authors, nonprofit publishers, academic institutions, research libraries, and research funders in the common goal of maximizing access to critical research.

Ectoparasites and other arthropod vectors have been incriminated as carriers of this organism. Soil, grass, drinking water, and decomposing animal carcasses are also a source of *E. rhusiopathiae* (Wood and Shuman, 1981, op. cit.). The isolate we cultured from the fawn may have been transmitted by biting flies, including

species of *Stomoxys* or *Tabanus*, if the flies had recently fed on an infected animal.

As no further isolations have been made from other white-tailed deer in this locality, we believe that this is an isolated event rather than an indication of an outbreak of *E. rhusiopathiae* in deer in Iowa.

Journal of Wildlife Diseases, 20(3), 1984, pp. 236-238
© Wildlife Disease Association 1984

Dermatophilosis in a Mule Deer, *Odocoileus hemionus* (Rafinesque), from Wyoming

Elizabeth S. Williams and A. C. Pier, Division of Microbiology and Veterinary Medicine, University of Wyoming, Laramie, Wyoming 82071, USA; and **Roger W. Wilson**, Wyoming Game and Fish Department, P.O. Box 6249, Sheridan, Wyoming 82801, USA

Dermatophilus congolensis Van Saceghem, 1915 causes contagious exudative dermatitis in cattle, horses, sheep, goats, dogs, humans and 25 species of wild animals including white-tailed deer (*Odocoileus virginianus* Zimmermann) (Pier, 1981, *In Tropical Diseases of Cattle*, Pistia (ed.), W. Junk, The Hague, Netherlands, pp. 367-376; Richard, 1981, *In Infectious Diseases of Wild Mammals*, Davis et al. (eds.), Iowa State University Press, Ames, Iowa, pp. 339-346; Salkin and Gordon, 1981, *In Diseases and Parasites of White-tailed Deer*, Davidson et al. (eds.), Tall Timbers Research Station, Tallahassee, Florida, pp. 168-174). The agent was first described in 1915 by Van Saceghem in Africa. First isolations of the organism in the United States were reported in 1961 from white-tailed deer and horses in New York and cattle in Texas (Bentinck-Smith et al., 1961, *Cornell Vet.* 51: 334-339; Bridges and Romane, 1961, *J. Am. Vet. Med. Assoc.* 138: 153-157; Dean et al., 1961, *N.Y. State J. Med.* 61: 1283-1287).

A previous description of "mycotic dermatitis," a common term for dermatophilosis, in a female mule deer in Wyoming was reported in 1957 (Post and Winter, 1957, *Federal Aid in Fish and Wildlife Restoration*, Project FW3-R-4, Wyoming Game and Fish Comm., Cheyenne, p. 16). The purpose of the present communication is to report the first culturally verified case of *D. congolensis* infection in a mule deer and the first isolation from Wyoming.

In September 1983 a doe and two fawns on a ranch near Clearmont, Wyoming were observed to be in poor nutritional condition; the doe also had a rough hair coat. Several days later, one of the fawns was found dead and partially decomposed and the second fawn was caught manually and euthanized. Necropsy of both fawns revealed numerous tapeworms (*Monezia expansa* (Rudolphi, 1810)) in the small intestine and evidence of diarrhea. Scabs and crusts were on the skin of the ears, the chin, and axilla of the fawn that was euthanized. Many nymphal ear ticks (*Otobius* sp.) were in the external meatus of both fawns. Besides several minor abra-

Received for publication 17 January 1984.

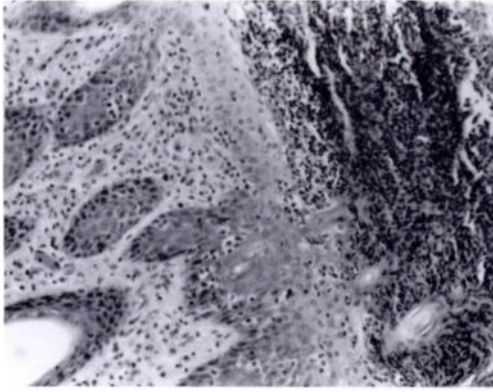


FIGURE 1. Suppurative dermatitis in a mule deer with dermatophilosis. H&E stain, $\times 105$.

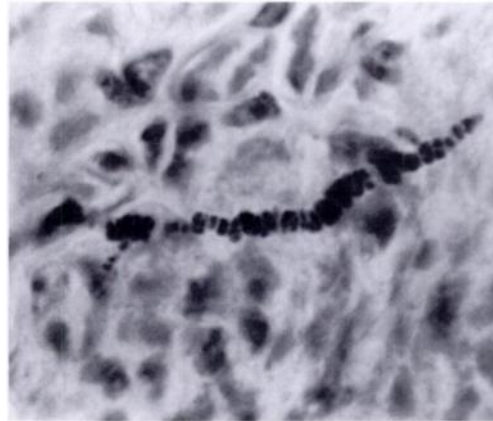


FIGURE 2. *Dermatophilus congolensis* in the skin of a mule deer. Giemsa stain, $\times 1,300$.

sions and lacerations, possibly due to barbed wire fences, there were no other gross lesions.

Microscopic examination of 6 μm sections of skin of the chin and axilla stained with hematoxylin and eosin or Giemsa stain revealed numerous foci of suppurative dermatitis and folliculitis. There was mild acanthosis and focal hyperkeratosis and parakeratosis. Fibrin, cellular debris, keratin and bacterial colonies covered the eroded or ulcerated skin (Fig. 1). In many suppurative foci, branching beaded hyphae were in the superficial layers of the skin (Fig. 2). Other microscopic lesions included a mild suppurative enteritis and mesenteric lymphadenitis.

Skin from the chin was examined by scraping and by KOH digestion and was negative for external parasites and dermatophytes. Viruses were not found on examination of negatively stained lesion preparations by electron microscopy. *Escherichia coli* (Migula, 1895) and a coagulase negative *Staphylococcus* sp. were isolated by routine bacteriologic techniques. Cultures for pathogenic fungi were negative.

Exudative crusts taken from the skin of the muzzle were emulsified, air dried, stained with Giemsa stain, and examined microscopically. Numerous multidimen-

sionally septate packets were observed (Fig. 3). Additional exudative crust material was emulsified in sterile saline, filtered through a 1.2 μm membrane syringe filter and the filtrate streaked on BHI agar as previously described (Pier et al., 1964, Am. J. Vet. Res. 25: 1014–1020). A nearly

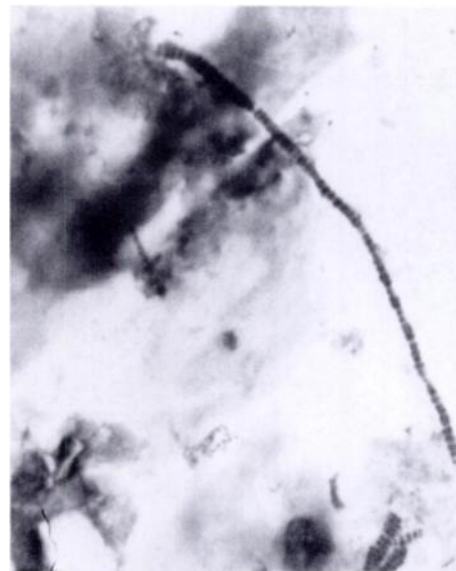


FIGURE 3. *Dermatophilus congolensis* in a smear of the exudate from the skin of a mule deer. Giemsa stain, $\times 370$.

pure culture of *D. congolensis* was recovered after 48 hr incubation at 37 C. The colonies were buff colored, raised, adherent, wrinkled, and surrounded by a zone of hemolysis. The isolated organism had morphologic and biochemical characteristics typical of *D. congolensis* (Pier et al., 1963, J. Am. Vet. Med. Assoc. 142: 995-1000).

This report adds an additional animal, the mule deer, to the growing list of animal hosts of *D. congolensis*. It seems possible that wildlife may act as a reservoir of this infection in many areas, considering the long list of known wildlife hosts (Richard and Schotts, 1976, Wildlife Diseases, Plenum Press, New York, New York, pp. 205-214). Despite extensive laboratory effort, *D. congolensis* has never been isolated as a free-living agent in the environment. It is considered to be an obligate parasite that is transmitted by direct contact or arthropod vectors from animal to animal (Richard and Pier, 1966, Am. J.

Vet. Res. 27: 419-423). Moisture enhances transmission presumably due to release of the motile zoospore phase of the organism (Pier, 1981, op. cit.). In much of Wyoming, the summer of 1983 was unusually wet due to abundant rainfall; however, in the Clearmont area summer rainfall was below normal.

Recognition of this condition in mule deer in Wyoming may have been the basis for the report of mycotic dermatitis in 1957 (Post and Winter, 1957, op. cit.), a term often applied to dermatophilosis of sheep and goats (Austwick, 1958, Vet. Rev. Annot. 4: 33-48). If that were the situation, the 1957 Wyoming report antedated other reports of this disease in the United States by 4 yr. However, lack of described cultural or microscopic data leaves this issue unresolved.

The authors thank Mr. Frank Auzque, Mr. Mark Owens, Ms. M. A. Reis, Ms. Sal Etherton, Mrs. Inez Johnson and Dr. E. Tom Thorne for assistance.

Journal of Wildlife Diseases, 20(3), 1984, pp. 238-240
© Wildlife Disease Association 1984

Granulomatous Peritonitis in a Fish Caused by a Flagellated Protozoan

C. H. Gardiner and Ralph M. Bunte, Department of Veterinary Pathology, Armed Forces Institute of Pathology, Washington, D.C. 20306, USA

An immature African cichlid (*Lamprologus elongatus* Boulenger, 1898), housed in a large show aquarium, was no-

ticed to have a worm-like structure protruding from the ventral mid-line. The fish was killed and submitted for histopathology.

In histologic section, abundant granu-

Received for publication 21 November 1983.

FIGURES 1-5. Granuloma in abdominal cavity of an African cichlid caused by flagellates. 1. Granuloma eroding through intestine. (i), intestine; (g), granuloma. H&E, $\times 25$ (AFIP MIS #83-8290). 2. Granuloma consisting of histiocytes and fibroblasts surrounds nests (o) of organisms. Most organisms appear to be contained within vacuoles. H&E, $\times 250$ (AFIP MIS #83-8291). 3. Organism has one nucleus (n) and a dark kinetoplast nucleoid (k) which gives rise to the flagella. H&E, $\times 1,000$ (AFIP MIS #83-8294). 4. Transmission electron micrograph of flagellate. (n), nucleus; (k), kinetoplast nucleoid; (f), flagella; (fp), flagellar pocket. $\times 19,700$ (AFIP MIS #83-8298). 5. Transmission electron micrograph of flagellar pocket. (f), flagella; (fp), flagellar pocket; (m) pellicular microtubules. Note 9 + 2 axoneme structure. $\times 63,350$ (AFIP MIS #83-8295).