

HEMATOZOA OF RAPTORS FROM SOUTHERN NEW JERSEY AND ADJACENT AREAS

Authors: Kirkpatrick, Carl E., and Lauer, David M.

Source: Journal of Wildlife Diseases, 21(1) : 1-6

Published By: Wildlife Disease Association

URL: <https://doi.org/10.7589/0090-3558-21.1.1>

The BioOne Digital Library (<https://bioone.org/>) provides worldwide distribution for more than 580 journals and eBooks from BioOne's community of over 150 nonprofit societies, research institutions, and university presses in the biological, ecological, and environmental sciences. The BioOne Digital Library encompasses the flagship aggregation BioOne Complete (<https://bioone.org/subscribe>), the BioOne Complete Archive (<https://bioone.org/archive>), and the BioOne eBooks program offerings ESA eBook Collection (<https://bioone.org/esa-ebooks>) and CSIRO Publishing BioSelect Collection (<https://bioone.org/csiro-ebooks>).

Your use of this PDF, the BioOne Digital Library, and all posted and associated content indicates your acceptance of BioOne's Terms of Use, available at www.bioone.org/terms-of-use.

Usage of BioOne Digital Library content is strictly limited to personal, educational, and non-commercial use. Commercial inquiries or rights and permissions requests should be directed to the individual publisher as copyright holder.

BioOne is an innovative nonprofit that sees sustainable scholarly publishing as an inherently collaborative enterprise connecting authors, nonprofit publishers, academic institutions, research libraries, and research funders in the common goal of maximizing access to critical research.

HEMATOZOA OF RAPTORS FROM SOUTHERN NEW JERSEY AND ADJACENT AREAS

Carl E. Kirkpatrick¹ and David M. Lauer²

ABSTRACT: Blood smears from 259 birds of 12 species, representing four families of raptors, from New Jersey, Pennsylvania, Delaware, and Virginia were examined for blood parasites. Infected birds constituted 59.1% of the total. Birds were infected with one or more of the following genera of protozoa: *Leucocytozoon* (43.2%); *Haemoproteus* (21.6%); *Plasmodium* (1.2%); and *Trypanosoma* (1.2%). Blood culture of 142 raptors of 11 species for *Trypanosoma* revealed a prevalence of 41.5%. *Plasmodium circumflexum* is reported for the first time in *Accipiter striatus*, and *Trypanosoma* sp. in *Buteo jamaicensis*.

INTRODUCTION

Little information exists on the Hematozoa of raptors, most existing data coming from the examination of captive birds (Peirce, 1981). Although numerous surveys of Hematozoa in North American birds have been reported, comparatively few of these have included a significant number of raptors, and few have covered the Middle Atlantic region of the United States (Wetmore, 1941; Jochen, 1966; Greiner et al., 1975; Williams and Bennett, 1978).

The present study was conducted to determine the prevalence of Hematozoa in raptors residing in or migrating through southern New Jersey and nearby areas and to determine the applicability of in vitro culture methods to the detection of parasitemias of *Trypanosoma* spp. in raptors.

MATERIALS AND METHODS

Birds and survey areas

Birds were trapped and sampled at bird-banding stations in Cape May County, New Jersey (207 birds) and in Northampton County, Virginia (31 birds). Captive birds were sampled at two injured-bird rehabilitation facilities: Tri-State Bird Rescue and Research, Inc., Wilmington, Delaware (15 birds); and the School of Vet-

erinary Medicine, University of Pennsylvania, Philadelphia, Pennsylvania (10 birds). Avian nomenclature conforms to that in a recent check-list of North American birds (American Ornithologists' Union, 1983).

Blood sampling

All blood samples were taken during the fall of 1982 and the fall and winter of 1983-1984. Blood was drawn aseptically from the right jugular vein, in the majority of birds, or from one of the tibial veins. Blood smears from 259 birds, representing 12 species and four families, were made in the field and dried with a stream of compressed air. In most cases, smears were fixed with absolute methanol and stained with Giemsa stain in the laboratory.

Blood culture

Of the 263 birds included in this survey, 142, representing 11 species and four families, were tested for the presence of circulating trypanosomes by blood culture; blood smears were not obtained from four of these birds. Freshly drawn blood (0.1 ml) was injected into 2-ml, rubber-stoppered glass vials containing one of two culture-medium formulations (1 ml/vial): SNB-9 (Diamond and Herman, 1954; Kucera, 1979), a diphasic medium, modified by the addition of antibiotics (200 U penicillin, 200 µg streptomycin, and 100 µg gentamycin/ml) and heat-inactivated (56 C, 30 min), rather than autoclaved, defibrinated rabbit blood; or Schneider's *Drosophila* Medium (GIBCO, Grand Island, New York 14072, USA) supplemented with 20% (v/v) heat-inactivated, fetal bovine serum (HyClone, Logan, Utah 84321, USA), 1.5% (w/v) sodium citrate, and antibiotics (as above). The latter medium is designated SCH-20-C and is a modification of a formula devised by Hendricks et al. (1978). The components of the SNB-9 medium (with the exception of the blood) were sterilized by autoclaving, and the SCH-

Received for publication 28 June 1984.

¹ Department of Pathobiology, School of Veterinary Medicine, University of Pennsylvania, Philadelphia, Pennsylvania 19104, USA.

² Tri-State Bird Rescue and Research, Inc., 2920 Duncan Road, Wilmington, Delaware 19808, USA.

This One



658C-993-EQYY

TABLE 1. Prevalence of Hematozoa in raptors as assessed by examination of stained blood smears.

| Host family and species | Total birds | | Total birds infected with | | | |
|---------------------------|-------------|----------|---------------------------|------|-----|------|
| | Examined | Infected | L* | H | P | T |
| Accipitridae | | | | | | |
| <i>Accipiter cooperii</i> | 5 | 4 | 4 | | | |
| <i>Accipiter striatus</i> | 166 | 109 | 99 | 25 | 3 | |
| <i>Buteo jamaicensis</i> | 10 | 3 | 3 | | | |
| <i>Buteo platypterus</i> | 2 | 0 | | | | |
| <i>Circus cyaneus</i> | 3 | 2 | 2 | | | |
| Total | 186 | 118 | 108 | 25 | 3 | |
| Percent infected | | 63.4 | 58.1 | 13.4 | 1.6 | |
| Cathartidae | | | | | | |
| <i>Cathartes aura</i> | 2 | 0 | | | | |
| Falconidae | | | | | | |
| <i>Falco columbarius</i> | 18 | 1 | | 1 | | |
| <i>Falco sparverius</i> | 43 | 29 | | 29 | | 2 |
| Total | 61 | 30 | | 30 | | 2 |
| Percent infected | | 49.2 | | 49.2 | | 3.3 |
| Strigidae | | | | | | |
| <i>Aegolius acadicus</i> | 3 | 3 | 3 | | | 1 |
| <i>Bubo virginianus</i> | 3 | 1 | 1 | | | |
| <i>Otus asio</i> | 3 | 1 | | 1 | | |
| <i>Strix varia</i> | 1 | 0 | | | | |
| Total | 10 | 5 | 4 | 1 | | 1 |
| Percent infected | | 50.0 | 40.0 | 10.0 | | 10.0 |
| Grand total | 259 | 153 | 112 | 56 | 3 | 3 |
| Percent infected | | 59.1 | 43.2 | 21.6 | 1.2 | 1.2 |

* Key: L = *Leucocytozoon*; H = *Haemoproteus*; P = *Plasmodium*; T = *Trypanosoma*.

20-C medium was sterilized by membrane filtration (0.45 μ m). Both media were refrigerated (4 C) until use.

After inoculation, the culture vials were incubated at 26 ± 1 C, and the contents of each vial were examined microscopically for trypanosomes two or three times for at least 15 days.

Statistical analyses

Differences between infection prevalences in various groups of birds were evaluated for significance by the chi square test.

RESULTS

Blood smears

Of the 259 birds from which blood smears were made, 153 (59.1%) were found to be infected with one or more genera of Hematozoa (Table 1). Among

the Accipitridae, *Leucocytozoon* was the most commonly observed parasite (58.1%). All of the *Leucocytozoon* in these birds resembled *L. toddi* as described by Greiner and Kocan (1977). Most *Haemoproteus* infections in *Accipiter striatus* were *H. elani*, with *H. syrnii*-like gametocytes evident in some specimens (Fig. 1), and the three malarial infections in *A. striatus* were *Plasmodium circumflexum* (Fig. 2).

In contrast to the Accipitridae, none of the Falconidae exhibited *Leucocytozoon* infection. However, 49.2% of the 61 Falconidae examined were found to be infected with *Haemoproteus*, which resembled *H. tinnunculus* as described recently by Maloney et al. (1984).

Half of the 10 Strigidae examined had positive blood smears. Four displayed

Leucocytozoon danilewskyi, and one, *Otus asio*, contained *Haemoproteus* (perhaps *H. noctuae*).

Neither of the two *Cathartes aura* sampled was found to be infected.

The great majority of slides showed very low parasitemias (<0.1%), particularly those containing *Plasmodium* and *Trypanosoma*.

Sheathed microfilariae were found in smears from an *A. striatus* (not shown).

The sexes of 234 of the birds were determined, and the proportion of males infected (70.3%) with one or more genera of Hematozoa, as assessed by blood-smear examination, was significantly greater ($P < 0.05$) than that of females (56.4%). Male birds comprised 43.2% of these 234 birds.

Representative blood smears have been deposited in the International Reference Centre for Avian Hematozoa, Memorial University of Newfoundland, St. John's, Newfoundland, Canada and assigned accession numbers 94992–95009.

Blood cultures

Culture of the blood of 142 birds revealed parasitemias of *Trypanosoma* sp. in 59 (41.5%) of them (Table 2). Among the Accipitridae, Falconidae, and Strigidae, 37.0%, 61.5%, and 42.9%, respectively, were found to have been infected with trypanosomes. Trypanosomes were not detected in the one *Cathartes aura* sampled. Only one (0.7%) of the 140 birds from which blood was cultured for trypanosomes also evidenced these organisms on a blood smear. The infection of *A. striatus* with *Trypanosoma* sp. was associated with *L. toddi* infection to a significant extent ($P < 0.01$) but not with *Haemoproteus* spp. infection ($P > 0.05$). For other host species, either the sample sizes were inadequate for statistical analysis, or no significant association ($P > 0.05$) was found (i.e., *H. tinnunculus* infection in *F. sparverius*).

Comparative studies on the suitability

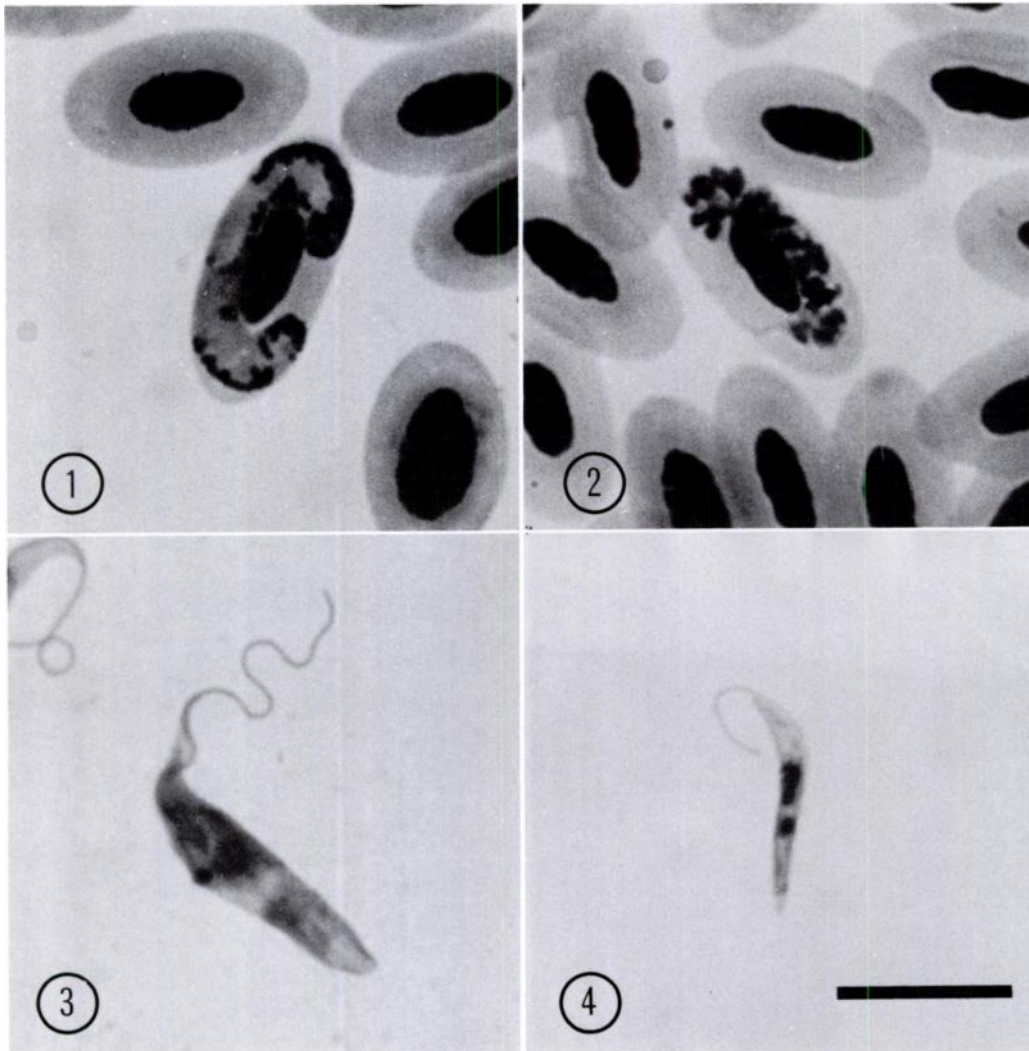
TABLE 2. Prevalence of trypanosomes in raptors as assessed by blood culture.

| Host family and species | Total birds | | % |
|---------------------------|-------------|----------|-------|
| | Examined | Infected | |
| Accipitridae | | | |
| <i>Accipiter cooperii</i> | 4 | 0 | |
| <i>Accipiter striatus</i> | 96 | 39 | 40.6 |
| <i>Buteo jamaicensis</i> | 6 | 1 | 16.7 |
| <i>Buteo platypterus</i> | 2 | 0 | |
| Cathartidae | | | |
| <i>Cathartes aura</i> | 1 | 0 | |
| Falconidae | | | |
| <i>Falco columbarius</i> | 6 | 4 | 66.7 |
| <i>Falco sparverius</i> | 20 | 12 | 60.0 |
| Strigidae | | | |
| <i>Aegolius acadicus</i> | 3 | 3 | 100.0 |
| <i>Bubo virginianus</i> | 1 | 0 | |
| <i>Otus asio</i> | 2 | 0 | |
| <i>Strix varia</i> | 1 | 0 | |
| Total | 142 | 59 | 41.5 |

of SNB-9 and SCH-20-C media for the detection of trypanosomes in the peripheral blood of raptors revealed no difference between them (data not shown). Therefore, SCH-20-C was used exclusively for about half of the samplings, since this medium was easier to prepare.

One hundred twenty-six of the birds tested for circulating trypanosomes were sexed, and 42.9% were males and 57.1% females. There was no significant difference ($P > 0.05$) between the proportion of males infected with trypanosomes (42.6%) and the proportion of females so infected (43.1%).

Primary culture of trypanosomes from these birds revealed two distinct morphologic types (Figs. 3 and 4). Procyclic trypomastigotes (culture forms) isolated from *Falco sparverius* were more slender and generally shorter than those from the other host species sampled. These differences were noted regardless of the medium (SNB-9 or SCH-20-C) used for parasite isolation. Comparison of the trypanosome isolates of host species other than *F. spar-*



FIGURES 1-4. Photomicrographs of blood parasites from raptors in southern New Jersey and adjacent areas. Giemsa stain. Bar in Figure 4 = 10 μ m. All figures are at the same magnification. 1. *Haemoproteus syrnii*-like microgametocyte in a blood smear from *Accipiter striatus*. Note the volutin granules distributed on the margins of the organism. 2. Mature schizont of *Plasmodium circumflexum* in a blood smear from *Accipiter striatus*. 3. Procyclic trypomastigote form of *Trypanosoma* sp. derived from a culture of peripheral blood from *Buteo jamaicensis*. The kinetoplast is adjacent to the nucleus. 4. Procyclic trypomastigote form of *Trypanosoma* sp. derived from a culture of peripheral blood from *Falco sparverius*. The kinetoplast is posterior to the nucleus. Note the shorter, more slender appearance of this organism compared with that in Figure 3.

verius did not reveal any obvious differences among them.

DISCUSSION

In the present study, the proportion of raptors (59.1% of 259 birds) found to be

infected with one or more genera of Hematozoa, as assessed by blood-smear examination, is similar to the results of surveys of raptors in Colorado (51.8% of 222 birds) (Stabler and Holt, 1965) and in Oklahoma (61.6% of 86 birds) (Kocan et al., 1977).

Williams and Bennett (1978) found only 27.1% of 70 raptors from New Jersey and Maryland to be infected; however, that study did not include any members of the Falconidae.

Culture of the peripheral blood of 142 birds for trypanosomes revealed a prevalence of 41.5% in raptors. Stabler et al. (1966) found 37.5% of 24 Colorado raptors to harbor trypanosomes as assessed by the examination of wet mounts of fresh bone marrow for the presence of motile trypomastigotes. These authors found that bone marrow was a much better indicator of trypanosome infection than the examination of stained blood smears. Using SNB-9 medium, Diamond and Herman (1954) found that, although the bone marrow was more likely to contain trypanosomes than blood, blood culture was superior to blood smears for the detection of trypanosome infections in geese. Concentration of trypanosomes by centrifugation of whole blood in capillary tubes has been advocated also as a sensitive diagnostic technique (Bennett, 1962). The results of the present study indicated that culture of the peripheral blood of raptors in SCH-20-C medium was a convenient and sensitive method of trypanosome detection; small amounts of blood were adequate, and the highly motile organisms were found readily after a week or two of culture.

The trypanosomes isolated from *F. sparverius* were consistently different, morphologically, from the trypanosomes isolated from all of the other species of birds reported here. A detailed examination of these differences is currently underway in our laboratory, and preliminary results indicate several biochemical differences between the trypanosomes of *F. sparverius* and those of the other raptors studied.

The prevalence of Hematozoa of raptors reported here may be lower than the true figure, because birds were sampled during the fall and winter months. Others

have shown seasonal fluctuations in parasitemias of the various Hematozoa in wild birds with highest levels occurring in the spring and summer months (Dorney and Todd, 1960; Applegate, 1971; Kucera, 1979). Our findings with respect to the prevalence of infections of *Plasmodium*, in particular, are very likely understated. Most of the parasitemias were quite low, and *Plasmodium* infections were recorded only if intraerythrocytic schizonts were detected; the gametocyte stages of *Plasmodium* and *Haemoproteus* can be difficult to distinguish in very low parasitemias (Peirce, 1981).

We conclude that: (i) Hematozoa are common in raptors in the area surveyed; (ii) males are more likely to be infected with Hematozoa, overall, than females; although no significant difference between the sexes appears to exist with regard to infection with *Trypanosoma* spp.; (iii) *A. striatus* infected with *Trypanosoma* sp. are more likely than not to be infected with *L. toddi*, which suggests that these parasites have a common vector (probably ornithophilic simuliids); and that (iv) two species of trypanosomes may be prevalent among raptors in the survey area. Furthermore, new host records are reported: (i) *Plasmodium circumflexum* in *Accipiter striatus*; and (ii) *Trypanosoma* sp. in *Buteo jamaicensis*. Also, the finding of *Haemoproteus syrnii*-like organisms in *A. striatus* is of interest, since this hematozoan has not been reported in hawks. These conclusions are based on the absence of these host-parasite associations in a recently compiled check-list of the avian Hematozoa (Bennett et al., 1982).

ACKNOWLEDGMENTS

We thank Drs. E. C. Greiner and G. F. Bennett for examining some of the slides and for helpful advice; Dr. W. Medway for advice; Messrs. W. S. Clark, F. Schaeffer, W. P. Smith, C. Schultz, and H. Gabler for their kind cooperation and assistance at banding stations; Ms. S. Williams for assistance in bird handling; and Ms. J. Flinn for typing the manuscript. This

study was funded, in part, by grants from the NIH Medical Scientist Training Program GM-07170; USDA Formula Fund CSRS-OD-1088 (D) Sub 08; and Tri-State Bird Rescue and Research, Inc.

LITERATURE CITED

- AMERICAN ORNITHOLOGISTS' UNION. 1983. Checklist of North American Birds, 6th Ed. Allen Press, Inc., Lawrence, Kansas, 877 pp.
- APPLEGATE, J. E. 1971. Spring relapse of *Plasmodium relictum* infections in an experimental field population of English sparrows (*Passer domesticus*). J. Wildl. Dis. 7: 37-42.
- BENNETT, G. F. 1962. The hematocrit centrifuge for laboratory diagnosis of Hematozoa. Can. J. Zool. 40: 124-125.
- , M. WHITEWAY, AND C. WOODWORTH-LYNAS. 1982. A host-parasite catalog of the avian Hematozoa. Memorial Univ. Nfld. Occ. Pap. Biol. 5: 1-243.
- DIAMOND, L. S., AND C. M. HERMAN. 1954. Incidence of trypanosomes in the Canada goose as revealed by bone marrow culture. J. Parasitol. 40: 195-202.
- DORNEY, R. S., AND A. C. TODD. 1960. Spring incidence of ruffed grouse blood parasites. J. Parasitol. 46: 687-694.
- GREINER, E. C., G. F. BENNETT, E. M. WHITE, AND R. F. COOMBS. 1975. Distribution of the avian Hematozoa of North America. Can. J. Zool. 53: 1762-1787.
- , AND A. A. KOCAN. 1977. *Leucocytozoon* (Haemosporidia; Leucocytozoidae) of the Falconiformes. Can. J. Zool. 55: 761-770.
- HENDRICKS, L. D., D. E. WOOD, AND M. E. HAJDUK. 1978. Hemoflagellates: Commercially available liquid media for rapid cultivation. Parasitology 76: 309-316.
- JOCHEN, R. F. 1966. Blood parasites of birds trapped in the New Jersey coastal region. Avian Dis. 10: 405-407.
- KOCAN, A. A., J. SNELLING, AND E. C. GREINER. 1977. Some infectious and parasitic diseases in Oklahoma raptors. J. Wildl. Dis. 13: 304-306.
- KUCERA, J. 1979. A simple cultivation method for field diagnosis of avian trypanosomes. Folia Parasitol. 26: 289-293.
- MALONEY, P. J., G. F. BENNETT, D. M. BIRD, AND D. J. LEWIS. 1984. *Haemoproteus tinnunculus* in the American kestrel (*Falco sparverius*). J. Wildl. Dis. 20: 57-58.
- PEIRCE, M. A. 1981. Current knowledge of the Hematozoa of raptors. In Recent Advances in the Study of Raptor Diseases, J. E. Cooper and A. G. Greenwood (eds.). Chiron Publications, Ltd., Keighly, England, pp. 15-19.
- STABLER, R. M., AND P. A. HOLT. 1965. Hematozoa from Colorado birds. II. Falconiformes and Strigiformes. J. Parasitol. 51: 927-928.
- , ———, AND N. J. KITZMILLER. 1966. *Trypanosoma avium* in the blood and bone marrow from 677 Colorado birds. J. Parasitol. 52: 1141-1144.
- WETMORE, P. W. 1941. Blood parasites of birds of the District of Columbia and Patuxent research refuge vicinity. J. Parasitol. 27: 379-393.
- WILLIAMS, N. A., AND G. F. BENNETT. 1978. Hematozoa of some birds of New Jersey and Maryland. Can. J. Zool. 56: 596-603.