

Electrocardiograms of American River Otters (*Lutra canadensis*) during Immobilization

Author: Hoover, J. P.

Source: Journal of Wildlife Diseases, 21(3) : 331-334

Published By: Wildlife Disease Association

URL: <https://doi.org/10.7589/0090-3558-21.3.331>

The BioOne Digital Library (<https://bioone.org/>) provides worldwide distribution for more than 580 journals and eBooks from BioOne's community of over 150 nonprofit societies, research institutions, and university presses in the biological, ecological, and environmental sciences. The BioOne Digital Library encompasses the flagship aggregation BioOne Complete (<https://bioone.org/subscribe>), the BioOne Complete Archive (<https://bioone.org/archive>), and the BioOne eBooks program offerings ESA eBook Collection (<https://bioone.org/esa-ebooks>) and CSIRO Publishing BioSelect Collection (<https://bioone.org/csiro-ebooks>).

Your use of this PDF, the BioOne Digital Library, and all posted and associated content indicates your acceptance of BioOne's Terms of Use, available at www.bioone.org/terms-of-use.

Usage of BioOne Digital Library content is strictly limited to personal, educational, and non-commercial use. Commercial inquiries or rights and permissions requests should be directed to the individual publisher as copyright holder.

BioOne is an innovative nonprofit that sees sustainable scholarly publishing as an inherently collaborative enterprise connecting authors, nonprofit publishers, academic institutions, research libraries, and research funders in the common goal of maximizing access to critical research.

response resembled that of other bears. He snarled, hissed, turned and ran off. After running 30 m the bear fell on its side, convulsed and stopped breathing.

Due to transportation problems involving an airlift the bear was not examined until 24 hr after death. The carcass of the bear was in dorsal recumbency. There was no apparent damage to the skin or pelage, but palpation revealed an area of approximately 15×20 cm over the right ventral thorax which had subcutaneous fluid and crepitation. In the center of this area, just dorsal to the costochondral junction over the sixth rib there was a 3 cm palpable defect in the thoracic wall.

There was less than 1 cm of subcutaneous fat present. All lesions were confined to the thoracic region. There was a large (10×4 cm) subcutaneous hemorrhage over the ventral portion of the right sixth rib and extensive intramuscular hemorrhage in this area. The sixth rib was fractured approximately 3 cm dorsal to the costochondral junction.

A few free blood clots plus 250 ml of dark red fluid were present in the pleural cavity. There was a 4 cm tear in the ventral portion of the anterior lobe of the right lung. The pericardial sac, which had no lacerations, was enlarged and turgid and

contained a large volume of partially clotted dark red blood. The heart was fully contracted and over the right coronary groove was a hemorrhage (approximately 4×2 cm) in the center of which was a 1 cm tear. This tear communicated with the right ventricle. There was hemorrhage in the myocardium around the tear, to a distance of 3–4 cm from the tear.

The cause of death of this bear was cardiac tamponade. The pericardium was not damaged. It is, therefore, likely that the damage to the ventricle arose from a shock wave rather than a direct physical injury by either the projectile or rib. Had an end of the broken rib caused damage to the ventricle, the pericardium would probably have been damaged also.

There has been a recognized risk potential when using the rubber baton on bears. The possibility of severe injury exists. Currently there is no more efficient deterrent available and the alternative of not deterring bears would inevitably lead to a continued increase in the number of bears being shot as man continues to encroach upon bear range. Persons now using this system have been instructed to aim for the hind quarters of the bear and to avoid shooting at distances under 40 m.

Journal of Wildlife Diseases, 21(3), 1985, pp. 331–334
© Wildlife Disease Association 1985

Electrocardiograms of American River Otters (*Lutra canadensis*) during Immobilization

J. P. Hoover, Department of Medicine and Surgery, College of Veterinary Medicine, Oklahoma State University, Stillwater, Oklahoma 74078, USA

The Oklahoma Department of Wildlife Conservation conducted a pilot study in 1984 to assess the feasibility of reintroduction of American river otters into Okla-

homa waterways as a part of the Non-game Wildlife Program. Ten otters (five males and five females) wild-caught in Louisiana were used in the study. Surgical implantation of intra-abdominal radiotelemetry devices to monitor otter movements and locations post-release was per-

Received for publication 15 October 1984.

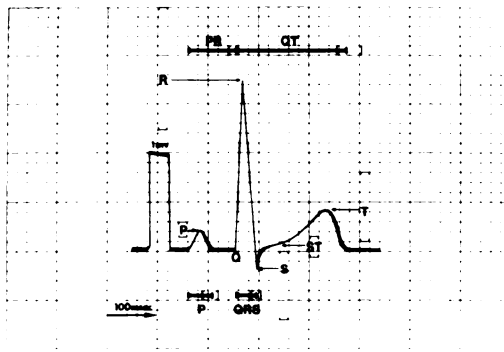


FIGURE 1. Scale representation of the mean lead II electrocardiogram for American river otters at a paper speed of 50 mm/sec. Each small box equals 0.1 millivolts on a vertical axis and 20 milliseconds on a horizontal axis. The observed ranges are contained within the brackets.

formed at the Boren Veterinary Medical Teaching Hospital at Oklahoma State University (Hoover, 1984, *J. Am. Vet. Med. Assoc.* 185: 1317–1320). Comprehensive clinical evaluations were performed on these otters prior to their release (Hoover et al., 1984, *J. Am. Vet. Med. Assoc.* 185: 1321–1326). In similar studies, post-release mortalities have been attributed to pulmonary and cardiac complications in river otters (Melquist and Hornocker, 1979, *Proc. Second Int. Conf. on Wildl. Biotelemetry*, pp. 104–114). The purpose of this report is to present the pre-surgical electrocardiographic findings from these otters.

Food was withheld for at least 12 hr prior to chemical immobilization, but otters were allowed water. Each otter was squeezed in its cage and given an intramuscular injection of ketamine hydrochloride (Ketaset, Bristol Laboratories, Syracuse, New York 13321, USA) combined with xylazine (Rompun, Haver-Lockhart Bayvet Division, Miles Laboratories, Inc., Shawnee, Kansas 66203, USA) and acepromazine maleate (PromAce, Fort Dodge Laboratories, Inc., Fort Dodge, Iowa 50501, USA). This combination consisted of 1,000 mg (10 ml) ke-

tamine, 10 mg (0.5 ml) xylazine, and 5 mg (0.5 ml) acepromazine. When sufficiently immobilized (≤ 10 min), weights were obtained, and the mean dosage of ketamine given was 17 mg/kg (range 13–22 mg/kg).

Electrocardiograms (ECG's) were recorded on an FD-31P ECG/phono system (Fukuda Denshi Corp., Tokyo, Japan). Variations in body positioning may alter ECG findings (Ettinger and Suter, 1970, *Canine Cardiology*, W. B. Saunders Co., Philadelphia, Pennsylvania, pp. 102–103). Sternal recumbency with all limbs extended was achieved easily in the immobilized otters and adopted as the standard for ECG recording. Three limb lead ECG's (I, II, and III) and three augmented limb lead ECG's (AVR, AVL, and AVF) were taken on each otter. Limb leads were attached over the patellas and olecranons with alligator clips. In addition, two chest leads were obtained which approximate CV_5RL (C_1)—fifth right intercostal space near the edge of the sternum, and CV_6LL (C_2)—sixth intercostal space near the sternum (Detweiler and Patterson, 1965, *Ann. N.Y. Acad. Sci.* 127: 481).

Measurements of the lead II ECG deflections (waves) and the comparisons of ECG configurations for the various leads have been established as criteria for evaluating normal findings and cardiac changes in domestic canines (Ettinger and Suter, 1970, *op. cit.*) and felines (Tilley and Gompf, 1977, *Vet. Clin. North Am.* 7: 257–284). The mean, standard deviation, and range for lead II ECG's and the % occurrence of the sum of positive and negative QRS deflections for all leads recorded on the otters are presented in Table 1. The P- and T-waves were negative in all lead AVR ECG's, positive in all lead II ECG's, and variable in all other leads. The mean lead II ECG for the otters is illustrated in Figure 1, and the observed ranges are included.

One otter was found to have mild right ventricular enlargement and another gen-

TABLE 1. Electrocardiograms of 10 American river otters during immobilization.^a

	QRS complex deflections				Mean \pm SD	Range
	Pos.	Iso-elec-tric	Neg.			
Leads				Heart rate	142 \pm 15/min	120–160/min
Standard						
I	100%	—	—	Rhythm	NSR ^b	—
II	100%	—	—			
III	60%	40%	—	Mean electrical axis		
Augmented				Frontal plane	54 \pm 13°	35–68°
AVR	—	—	100%			
AVL	40%	60%	—	Lead II		
AVF	80%	20%	—	P msec ^c	49 \pm 10	30–60
Chest				P mV ^d	0.22 \pm 0.05	0.15–0.30
C ₁ (n = 7)	43%	43%	14%	PR msec	95 \pm 8	80–100
C ₂	30%	—	70%	QT msec	220 \pm 19	200–250
				ST segment mV	0.05 \pm 0.07	(–0.05)–0.15
				T mV	0.42 \pm 0.21	0.10–0.80
				QRS msec	41 \pm 6	30–50
				S mV	(–0.17) \pm 0.26	(–0.70)–0.00
				Q mV	0 \pm 0	—
				R mV	1.75 \pm 0.46	1.25–2.50

^a Paper speed was 50 mm/sec, and sensitivity of 1 millivolt = 10 mm.^b NSR = normal sinus rhythm.^c msec = milliseconds.^d mV = millivolts.

eralized cardiomegaly on thoracic radiographs. The ECG's of these two otters were compared to the eight otters having normal radiographic cardiac silhouettes. The lead II P-wave duration was 60 milliseconds (range 30–60) for both otters, and the R-wave amplitude was 1.25 millivolts (range 1.25–2.50) for the otter with generalized cardiomegaly. These values were not found to be significant ($P < 0.10$) when detection of extreme values was performed (Dixon and Massey, 1969, Introduction to Statistical Analysis, 3rd Ed., McGraw Hill, New York, New York, pp. 328–330). Values for all other lead II measurements fell within the observed ranges of this sample population, and the ECG configurations in all leads were not unique for these two otters. No accepted criteria (Ettinger and Suter, 1970, op. cit.; Tilley and Gompf, 1977, op. cit.) predicting the

radiographic right ventricular enlargement or generalized cardiomegaly were found based on these ECG's.

One otter was found to have a 3.8 mEq/liter serum potassium (mean 4.4 mEq/liter, range 4.2–4.5 mEq/liter, and $n = 9$) on hematologic samples (Hoover et al., 1984, op. cit.). No difference in ECG T-wave amplitude, duration, or configuration was observed at this level of serum potassium.

The effects of immobilization agents on the ECG's are unknown; however, it is unlikely that comparable data will be collected on river otters without chemical restraint. No changes in lead II ECG's other than rate were observed on continuous oscilloscope monitoring during the ensuing surgical anesthesia (Hoover, 1984, op. cit.). These clinical data should provide reference values for evaluating ECG changes

and cardiovascular diseases of American river otters contained in zoological collections and used in relocation studies.

The author thanks Dr. E. M. Jones, Ellen K. Morgan, and Carla P. Wilder for the technical assistance given, Suzanne B.

Spears for figure illustration, Robert T. Doyle for photographic reproduction, and Dr. James E. Breazile, Dr. Anthony E. Castro, and James M. Hellwege for assistance with the preparation of the manuscript.