

## **A Sphaerospora-like Myxosporidean from the Kidneys of Atlantic Salmon (*Salmo salar*)**

Authors: Bennett, R. O., and Wolke, R. E.

Source: Journal of Wildlife Diseases, 22(2) : 268-271

Published By: Wildlife Disease Association

URL: <https://doi.org/10.7589/0090-3558-22.2.268>

---

The BioOne Digital Library (<https://bioone.org/>) provides worldwide distribution for more than 580 journals and eBooks from BioOne's community of over 150 nonprofit societies, research institutions, and university presses in the biological, ecological, and environmental sciences. The BioOne Digital Library encompasses the flagship aggregation BioOne Complete (<https://bioone.org/subscribe>), the BioOne Complete Archive (<https://bioone.org/archive>), and the BioOne eBooks program offerings ESA eBook Collection (<https://bioone.org/esa-ebooks>) and CSIRO Publishing BioSelect Collection (<https://bioone.org/csiro-ebooks>).

Your use of this PDF, the BioOne Digital Library, and all posted and associated content indicates your acceptance of BioOne's Terms of Use, available at [www.bioone.org/terms-of-use](http://www.bioone.org/terms-of-use).

Usage of BioOne Digital Library content is strictly limited to personal, educational, and non-commercial use. Commercial inquiries or rights and permissions requests should be directed to the individual publisher as copyright holder.

---

BioOne is an innovative nonprofit that sees sustainable scholarly publishing as an inherently collaborative enterprise connecting authors, nonprofit publishers, academic institutions, research libraries, and research funders in the common goal of maximizing access to critical research.

## **A *Sphaerospora*-like Myxosporidean from the Kidneys of Atlantic Salmon (*Salmo salar*)**

**R. O. Bennett and R. E. Wolke**, Department of Fisheries, Aquaculture and Pathology, University of Rhode Island, Kingston, Rhode Island 02881, USA

Adult Atlantic salmon obtained from a hatchery in New Brunswick, Canada were maintained in a partial reuse system at the Aquaculture Center of the University of Rhode Island. Salmon were treated with a formalin bath to alleviate an outbreak of branchial copepodiasis (*Salmonicola*

sp.). Following treatment, a female salmon 76.0 cm in fork length died (University of Rhode Island Accession No. L 161; U.S. National Parasite Collection No. 78760). At necropsy gross observations revealed copepods parasitizing the gills and numerous cestodes (*Eubothrium* sp.) within the pyloric cecae.

Tissues from the salmon were fixed in

Received for publication 24 January 1985.

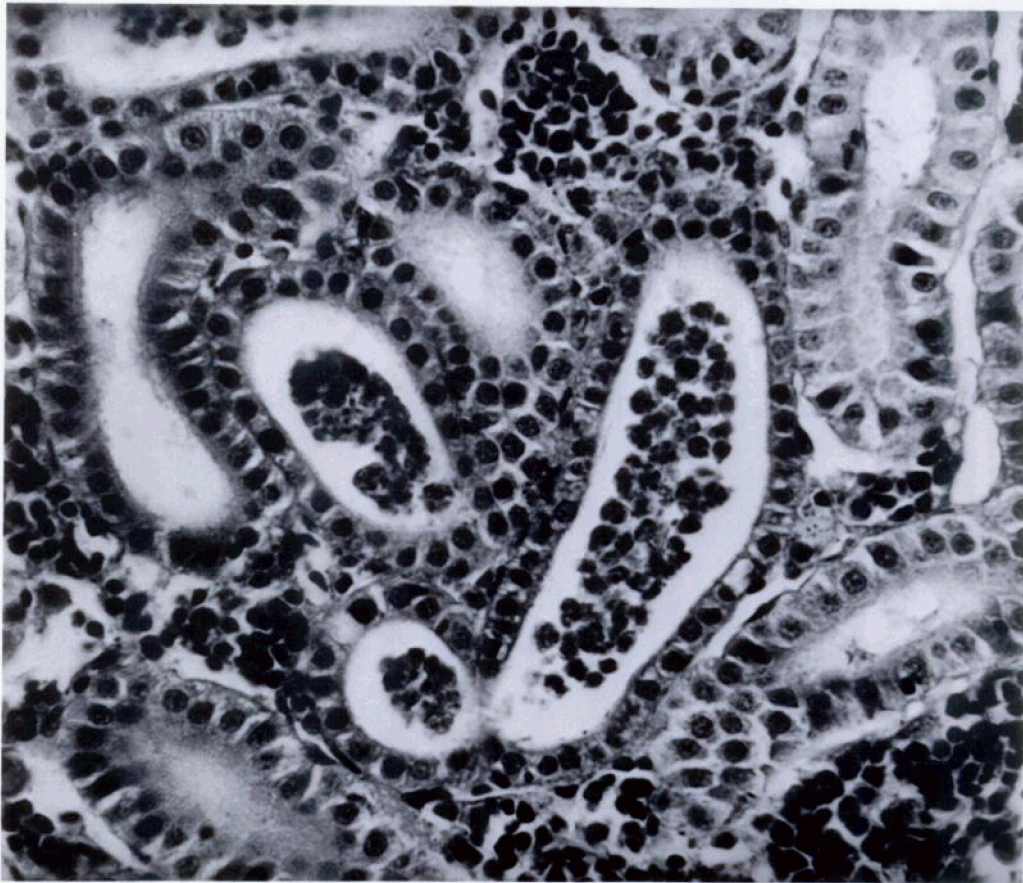


FIGURE 1. Renal tubules of an Atlantic salmon containing *Sphaerospora*-like organisms. H&E,  $\times 400$ .

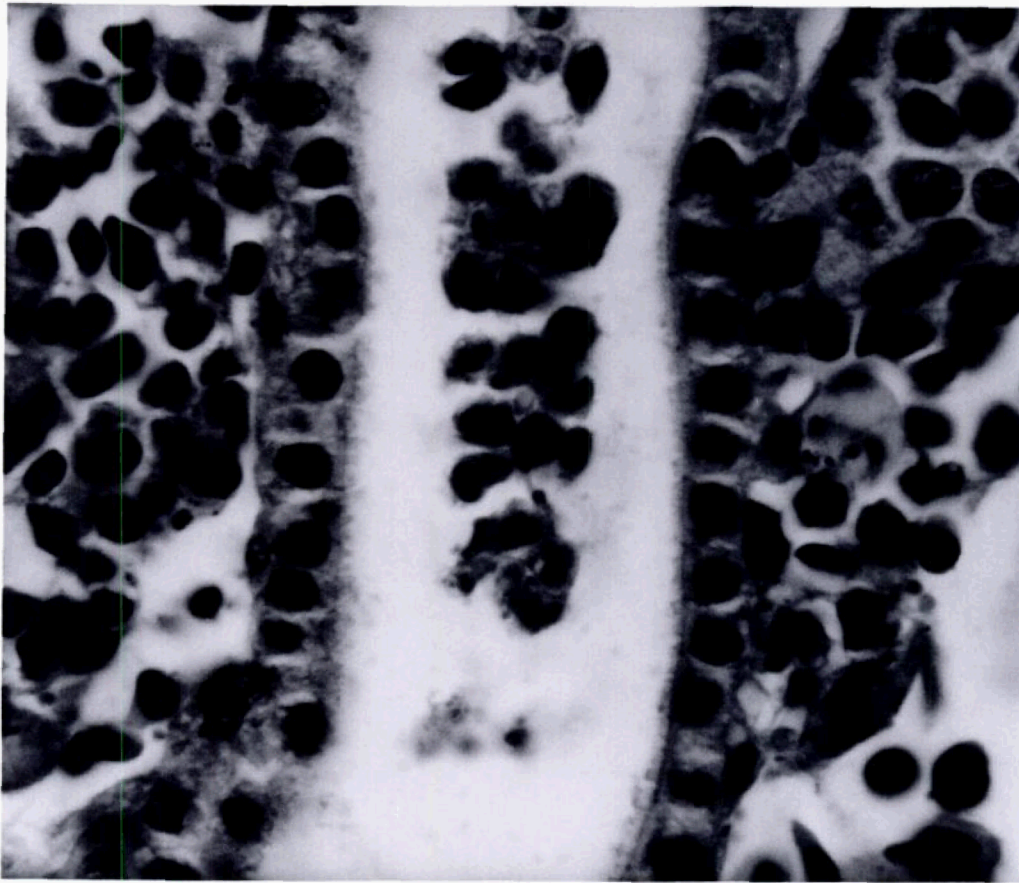


FIGURE 2. Proximal convoluted tubule of an Atlantic salmon containing *Sphaerospora*-like pansporoblasts. H&E,  $\times 1,000$ .

10% neutral buffered formalin, paraffin embedded, sectioned at  $6\ \mu\text{m}$  and stained with hematoxylin and eosin. Histological examination showed that the proximal convoluted tubules of the kidney were often occluded by a protozoan (Fig. 1). Morphologically the protozoan resembled *Sphaerospora angulata* as described by Molnar (1980a, J. Fish Dis. 3: 11–19; 1980b, *In Fish Diseases*, 3rd COPRAQ Session, Ahne (ed.), Springer-Verlag, Berlin, Germany, pp. 157–164). Pansporoblasts were the predominant developmental stages seen in the proximal tubules (Fig. 2). The pansporoblasts were multinucleated, round or ellipsoid, and 12–15  $\mu\text{m}$  in width. Positive identification by spore collection from fixed tissue was un-

successful. Impression smears and spore collection performed on fresh tissue from 10 Atlantic salmon that subsequently died were negative. Histological examination also revealed that these fish were free of the renal parasite.

*Sphaerospora angulata* is usually associated with the proximal tubules in mild infections while heavy infections involve the intermediate and distal segments as well (Molnar, 1980a, op. cit.). Similarly, Molnar noted that the earliest developmental stages of *S. angulata* were restricted mainly to the proximal tubules.

Multinucleated pansporoblasts and what appeared to be pairs of spores could be located within the proximal tubules of the dead salmon. No presporoblastic stages



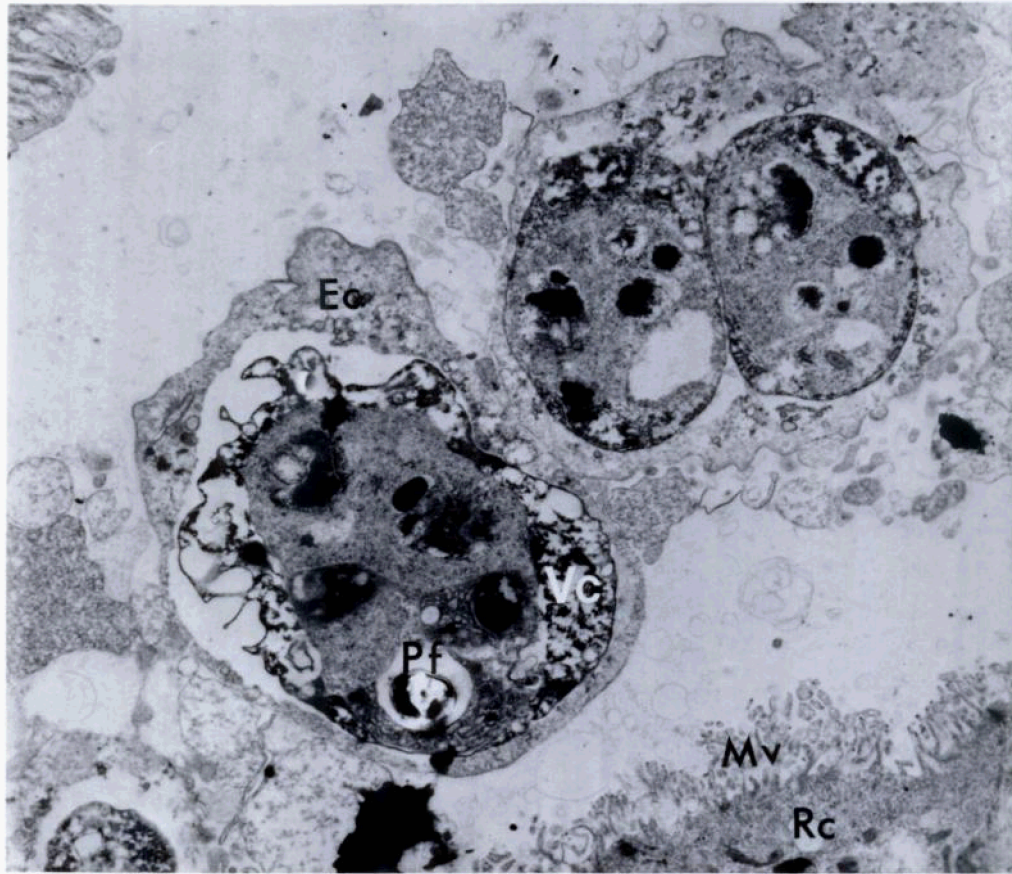


FIGURE 3. The lumen of a proximal convoluted tubule of an Atlantic salmon containing *Sphaerospora*-like organism. The polar filament (Pf) can be seen in one organism. Developing spores can be seen within the cytoplasm of the envelope cell (Ec). Peripherally arranged valvogenic cells (Vc) can also be seen. Rc, renal tubule epithelium; Mv, microvilli of one of the renal tubule epithelial cells.  $\times 20,000$ .

were found. Molnar (1980a, op. cit.) suggested that the early stages of *S. angulata* probably develop in non-renal locations.

Histopathologically an inflammatory response was lacking and evidence of invasion or damage to the tubular epithelium and microvilli was not observed. Affected tubules were dilated. This concurs with the findings of Molnar (1980a, op. cit.; 1980b, op. cit.). *Sphaerospora angulata*, a coelozoic parasite, utilizes nutrients excreted, but not yet reabsorbed by the kidney. Nephrosis may occur as a result of mechanical obstruction of tubules by sphaerospores and/or debris from spore

development. Precipitating salt crystals from retained urine can also have the same effect (Molnar, 1980b, op. cit.). Renal sphaerosporosis is not usually associated with mortality and apparently was not the cause of death of the salmon examined in this study.

Fresh tissue for electron microscopy was not available. Formalin fixed material from the kidneys was washed in 0.1 M sodium phosphate buffer, treated for 1 hr in a 1% solution of osmium tetroxide in the same buffer, dehydrated in alcohol and embedded in Spurr's resin. Thin sections were cut and stained with uranyl acetate

and lead citrate and examined with a Hitachi HS-9 transmission electron microscope.

Examination by electron microscopy established the ultrastructure of the protozoan in question. The parasite is remarkably similar ultrastructurally to *Sphaerospora angulata* (Desser et al., 1983, J. Protozool. 30: 415-422) suggesting that the protozoan is indeed a sphaerosporan. The sections had some loss of contrast and detail due to initial formalin fixation. However, developing paired spores were seen clearly within the cytoplasm of the envelope cell (Fig. 3). A disporous pansporoblast is characteristic of *S. angulata* (Desser et al., 1983, op. cit.).

Mature spores containing polar filaments were seen in some of the pansporoblasts indicating that the development of the protozoan was asynchronous as is *S. angulata* (Desser et al., 1983, op. cit.; Molnar, 1980a, op. cit.; Molnar, 1980b, op. cit.). Desser et al. (1983, op. cit.) observed that one of the spores formed in the pansporoblast was absent leaving a large lucent space. This was also found in pansporoblasts from the Atlantic salmon, except the lucent space was not as large, possibly a result of fixation (Fig. 3).

Valvogenic and capsulogenic cells participate in spore formation and were paired in *S. angulata* (Desser et al., 1983, op. cit.). Valvogenic cells were evident within the pansporoblasts found in the kidney tubules of the Atlantic salmon. Capsulogenic cells appear to be present, but due to fixation were not easily discerned (Fig. 3).

Based on histological, pathological, and ultrastructural similarities to *S. angulata*, it is suggested that the organism present in the tubules of the Atlantic salmon is a species of *Sphaerospora*. This appears to be the first observation of renal sphaerosporosis in Atlantic salmon. Molnar (1980, op. cit.) stated that developing stages of *Sphaerospora* spp. were easily detected in the kidney of species of fish other than carp. He suggested that different *Sphaerospora* spp. causing renal sphaerosporosis in fishes are more common than the literature indicates.

The authors thank Dr. L. T. Smith for providing the salmon. Contribution No. 2255 of the Agricultural Experiment Station, University of Rhode Island.