

## **Myopathy Associated with Megaloschizonts of *Haemoproteus meleagridis* in a Wild Turkey from Florida**

Authors: Atkinson, Carter T., and Forrester, Donald J.

Source: Journal of Wildlife Diseases, 23(3) : 495-498

Published By: Wildlife Disease Association

URL: <https://doi.org/10.7589/0090-3558-23.3.495>

---

The BioOne Digital Library (<https://bioone.org/>) provides worldwide distribution for more than 580 journals and eBooks from BioOne's community of over 150 nonprofit societies, research institutions, and university presses in the biological, ecological, and environmental sciences. The BioOne Digital Library encompasses the flagship aggregation BioOne Complete (<https://bioone.org/subscribe>), the BioOne Complete Archive (<https://bioone.org/archive>), and the BioOne eBooks program offerings ESA eBook Collection (<https://bioone.org/esa-ebooks>) and CSIRO Publishing BioSelect Collection (<https://bioone.org/csiro-ebooks>).

Your use of this PDF, the BioOne Digital Library, and all posted and associated content indicates your acceptance of BioOne's Terms of Use, available at [www.bioone.org/terms-of-use](http://www.bioone.org/terms-of-use).

Usage of BioOne Digital Library content is strictly limited to personal, educational, and non-commercial use. Commercial inquiries or rights and permissions requests should be directed to the individual publisher as copyright holder.

---

BioOne is an innovative nonprofit that sees sustainable scholarly publishing as an inherently collaborative enterprise connecting authors, nonprofit publishers, academic institutions, research libraries, and research funders in the common goal of maximizing access to critical research.

## Myopathy Associated with Megaloshizonts of *Haemoproteus meleagridis* in a Wild Turkey from Florida

Carter T. Atkinson<sup>1</sup> and Donald J. Forrester, Department of Infectious Diseases, College of Veterinary Medicine, University of Florida, Gainesville, Florida 32610, USA. <sup>1</sup> Present address and address for reprints: Institute of Pathology, Case Western Reserve University, Cleveland, Ohio 44121, USA

**ABSTRACT:** Necropsy of an emaciated adult wild turkey (*Meleagris gallopavo osceola*) that died in captivity soon after capture revealed numerous macroscopic 1–2 mm white cysts in the pectoral muscles. Microscopic, aseptate protozoan megaloshizonts, 50–150  $\mu$ m in diameter, corresponded to the cysts in histological sections. The megaloshizonts were surrounded by a thick, hyaline wall and packed with spherical merozoites <1  $\mu$ m in diameter. Muscle fibers surrounding most of the megaloshizonts exhibited early signs of dystrophic calcification. The fibers were swollen, pale and hyaline and contained scattered basophilic granules. The megaloshizonts were morphologically distinct from sarcocysts of *Sarcocystis* sp. and *Besnoitia* sp. and the thin-walled tissue cysts of *Toxoplasma gondii*. They were identical in structure and host reaction to the second-generation megaloshizonts of *Haemoproteus meleagridis*, reported previously from experimentally infected domestic turkeys. While the precise cause of death of the wild turkey could not be determined, the most prominent lesions were associated with the numerous intramuscular megaloshizonts.

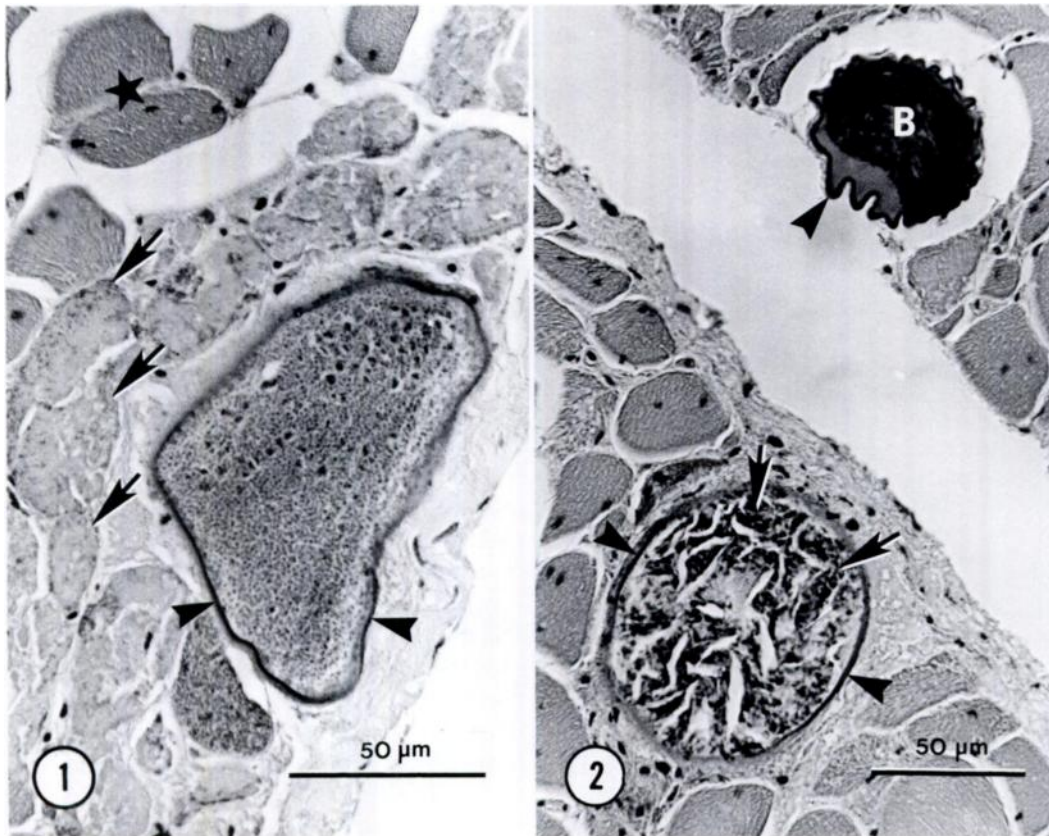
**Key words:** Wild turkey, *Meleagris gallopavo osceola*, myopathy, *Haemoproteus meleagridis*, megaloshizont, Florida.

*Haemoproteus meleagridis* is a common haemosporidian that occurs in wild and domestic turkeys throughout the Nearctic range of the host (Greiner and Forrester, 1980). The parasite is transmitted by *Culicoides* spp. and is most common in the southeastern United States where prevalences may be as high as 80–90% in wild turkeys (Forrester et al., 1974b; Atkinson et al., 1983). Eve et al. (1972a, b) speculated that *H. meleagridis* might be a potential pathogen of wild turkeys, but evidence was circumstantial and based

on observations that high parasitemias seemed to coincide with periods of high mortality in wild birds.

Atkinson et al. (1986) recently documented two generations of pre-erythrocytic schizogony in cardiac and skeletal muscle of domestic turkeys infected experimentally with *H. meleagridis*. An intense inflammatory reaction occurred following the rupture of first generation schizonts which caused acute lameness in experimental birds. During the development of second generation megaloshizonts, muscle fibers adjacent to growing parasites exhibited early signs of necrosis and were swollen, pale and hyaline. In this report, we document the occurrence of morphologically identical megaloshizonts in a naturally infected wild turkey (*Meleagris gallopavo osceola*) collected in central Florida and describe a similar myopathy associated with the mature megaloshizonts.

During an investigation of the parasites and diseases of wild turkeys in Florida, an adult gobbler in poor physical condition was captured by hand on 16 November 1970 near Lake Apopka, Orange County, Florida. Soon after capture, the bird died and the carcass was frozen. At necropsy, 3 wk later, cutaneous granulomatous nodules were noted on the skin of the head. After the bird was skinned, examination of the pectoral muscles revealed scattered white 1–2 mm diameter cysts which were similar grossly to the sarcocysts of *Sarcocystis* spp. The peritoneal cavity was opened using aseptic techniques and swabs of the liver, spleen, intestinal contents and



FIGURES 1, 2. 1. Megaloshizont of *H. meleagridis* from the pectoral muscle of a naturally infected wild turkey. The megaloshizont is surrounded by a thick, hyaline wall (arrowheads) and is packed with spherical merozoites. Muscle fibers surrounding the megaloshizont are swollen, pale and hyaline and contain scattered basophilic granules (arrows). Note adjacent normal muscle tissue (\*). H&E. 2. Degenerating megaloshizonts of *H. meleagridis* from pectoral muscle of a wild turkey. The megaloshizonts are surrounded by a thick, hyaline wall (arrowheads) and contain either amorphous basophilic material (B) or pale, eosinophilic material with scattered basophilic masses (arrows). The partially collapsed wall of one megaloshizont and surrounding extracellular space and the large clefts within the interior of the other megaloshizont are freezing artifacts introduced prior to the fixation of the tissue. H&E.

cloaca were prepared and cultured for pathogenic bacteria as described by Forrester et al. (1977). Gross examination of the major organs revealed few abnormal changes. The lining of the gizzard had reddish lesions on the surface, associated with two underlying nematodes. All other organs appeared normal. The major organs were then processed for the routine collection of helminth parasites as described by Forrester et al. (1974a). Representative cutaneous nodules from the head and pieces of pectoral muscle were fixed in

buffered 10% formalin and processed for histological examination. Blood smears were not prepared because the carcass had been frozen.

Histological sections of pectoral muscle contained numerous megaloschizonts ranging from 50–150  $\mu\text{m}$  in diameter in cross section. In sections stained with hematoxylin and eosin, the megaloschizonts were surrounded by a thick, hyaline wall and were usually packed with spherical merozoites  $<1 \mu\text{m}$  in diameter (Fig. 1). Some megaloschizonts were in different

stages of degeneration. Some were partially collapsed and filled with amorphous, basophilic material (Fig. 2). Other megaloschizonts contained pale, eosinophilic material with scattered basophilic masses of variable sizes. The material was often divided by large clefts (Fig. 2). Muscle fibers surrounding most of the megaloschizonts exhibited early signs of dystrophic calcification. The fibers were swollen, pale and hyaline and contained scattered basophilic granules (Fig. 1).

Histological sections of skin from the head revealed granulomas of mycotic origin under the epidermis. A variety of helminths were recovered from the gastrointestinal tract, including three specimens of *Dispharynx nasuta* from the proventriculus, two specimens of *Cyrnea* sp. from under the lining of the gizzard, three specimens of *Heterakis gallinarum* from the ceca, one specimen of *Strigea* sp. and 42 scolices of *Metrolia sthes lucida* from the small intestine. Several filarid nematodes, including two specimens of *Aproctella stoddardi* and one specimen of *Singhifilaria hayesi*, were found in the body cavity. Pathogenic bacteria were not recovered from the intestinal contents of the turkey. A *Corynebacterium* sp., not further identified, was recovered from the spleen and liver.

While the precise cause of death of this turkey could not be determined, the low numbers of helminths recovered from the gastrointestinal tract and peritoneal cavity and the restricted distribution of mycotic lesions on the head were unlikely causes of morbidity or mortality. The presence of a *Corynebacterium* sp. in the liver and spleen could be significant. However, the most prominent lesions were associated with the numerous intramuscular megaloschizonts and were characteristic of a chronic wasting condition.

Several morphological features distinguished the megaloschizonts observed in the wild turkey from developmental stages

of tissue cyst-forming coccidian parasites such as species of the genera *Sarcocystis*, *Besnoitia* and *Toxoplasma*. The intramuscular sarcocysts of *Sarcocystis* spp. are compartmentalized by internal septae, contain long, slender merozoites and are surrounded by a thick wall composed of numerous protrusions (Tadros and Laarman, 1982). Tissue cysts of *Besnoitia* spp. are similar in morphology, but lack internal septae. *Besnoitia* cysts also have a thick, fibrillar wall of host origin which surrounds a multinucleated and hypertrophied parasitized host cell. They normally develop in a variety of host tissues (Tadros and Laarman, 1982). Tissue cysts of *Toxoplasma gondii* are thin-walled and much smaller in size. The megaloschizonts we observed were identical in size and morphology to second generation megaloschizonts of *H. meleagridis*. Necrotic megaloschizonts observed in this study were similar to those reported in domestic turkeys with experimental infections of *H. meleagridis* (Atkinson et al., 1986). The collapsed walls and internal clefts described in this report, however, probably represent freezing artifacts introduced prior to fixation of the tissue.

Second generation megaloschizonts of *H. meleagridis* are similar morphologically to species that have been reported in birds with natural infections of *H. handai* (= *H. deseri*) and *Arthrocystis galli* (Atkinson et al., 1986). Gardiner et al. (1984) described related megaloschizonts from pen-reared northern bobwhites (*Colinus virginianus*) and reviewed the literature dealing with similar species from other families of birds. Most of the megaloschizonts have an associated host myopathy ranging from acute hemorrhagic inflammatory infiltrates to chronic necrosis and dystrophic calcification of adjacent muscle fibers (Opitz et al., 1982). The megaloschizonts can be a cause of severe mortality in chickens (Opitz et al., 1982) and in psittacine birds (Garnham, 1973).

The necrosis of muscle tissue surrounding megaloschizonts from the wild turkey is similar to necrotic changes that occur in association with 17-day-old megaloschizonts of *H. meleagridis* (Atkinson et al., 1986). Atkinson (1985) observed acute hemorrhagic inflammatory infiltrates followed by extensive calcification of muscle tissue in association with older, 19- to 22-day-old megaloschizonts in experimentally infected domestic turkeys during a more extensive pathogenicity experiment. The occurrence of similar lesions in experimentally infected domestic turkeys and a naturally infected wild turkey suggests that the potential pathogenicity of *H. meleagridis* in populations of wild turkeys should be reassessed.

The authors would like to thank Larry Martin of the Florida Game and Fresh Water Fish Commission for obtaining the turkey, K. P. C. Nair for assistance with the necropsy and Franklin H. White for the bacteriological examinations. Supported in part by grant #1270G from the Florida Game and Fresh Water Fish Commission. Florida Agricultural Experiment Station Journal Series No. 7569.

#### LITERATURE CITED

- ATKINSON, C. T. 1985. The epizootiology and pathogenicity of *Haemoproteus meleagridis* Levine, 1961 in Florida turkeys. Ph.D. Dissertation. University of Florida, Gainesville, Florida, 294 pp.
- , E. C. GREINER, AND D. J. FORRESTER. 1983. Experimental vectors of *Haemoproteus meleagridis* from wild turkeys in Florida. *Journal of Wildlife Diseases* 19: 366–368.
- , ———, AND ———. 1986. Pre-erythrocytic development and associated host responses to *Haemoproteus meleagridis* (Haemosporina: Haemoproteidae) in experimentally infected domestic turkeys. *Journal of Protozoology* 33: 375–381.
- EVE, J. H., F. E. KELLOG, AND R. W. BAILEY. 1972a. Blood parasitisms of wild turkeys of eastern West Virginia. *Journal of Wildlife Management* 36: 624–627.
- , ———, AND F. A. HAYES. 1972b. Blood parasitisms of wild turkeys in the southeastern U.S.A. *Journal of the American Veterinary Medical Association* 161: 638–640.
- FORRESTER, D. J., A. O. BUSH, L. E. WILLIAMS, JR., AND D. J. WEINER. 1974a. Parasites of greater sandhill cranes (*Grus canadensis tabida*) on their wintering grounds in Florida. *Proceedings of the Helminthological Society of Washington* 41: 55–59.
- , L. T. HON, L. E. WILLIAMS, JR., AND D. H. AUSTIN. 1974b. Blood protozoa of wild turkeys in Florida. *Journal of Protozoology* 212: 494–497.
- , J. M. GASKIN, F. H. WHITE, N. P. THOMPSON, J. A. QUICK, JR., J. C. WOODARD, AND W. D. ROBERTSON. 1977. An epizootic of waterfowl associated with a red tide in Florida. *Journal of Wildlife Diseases* 13: 160–167.
- GARDINER, C. H., H. J. JENKINS, AND K. S. MAHONEY. 1984. Myositis and death in bobwhites, *Colinus virginianus* (L.), due to hemorrhagic cysts of a haemosporozoan of undetermined taxonomic status. *Journal of Wildlife Diseases* 20: 308–318.
- GARNHAM, P. C. C. 1973. Epizootics of *Leucocytozoon* infections in parakeets in England. *Progress in Protozoology*, Universite de Clermont, Clermont, France, p. 149.
- GREINER, E. C., AND D. J. FORRESTER. 1980. *Haemoproteus meleagridis* Levine, 1961: Redescription and developmental morphology of the gametocytes in turkeys. *Journal of Parasitology* 66: 652–658.
- OPITZ, H. M., H. J. JAKOB, E. WIENSENHUETTER, AND V. VASANDRA DEVI. 1982. A myopathy associated with protozoan schizonts in chickens in commercial farms in peninsular Malaysia. *Avian Pathology* 11: 527–534.
- TADROS, W., AND J. J. LAARMAN. 1982. Current concepts on the biology, evolution and taxonomy of tissue cyst-forming eimeriid coccidia. *Advances in Parasitology* 20: 293–468.

Received for publication 29 September 1986.