

## **Visceral and Subcutaneous Acariasis Caused by Hypopi of *Hypodectes propus bulbuci* in the Cattle Egret**

Authors: Hendrix, Charles M., Kwapien, Robert P., and Porch, John R.

Source: Journal of Wildlife Diseases, 23(4) : 693-697

Published By: Wildlife Disease Association

URL: <https://doi.org/10.7589/0090-3558-23.4.693>

---

The BioOne Digital Library (<https://bioone.org/>) provides worldwide distribution for more than 580 journals and eBooks from BioOne's community of over 150 nonprofit societies, research institutions, and university presses in the biological, ecological, and environmental sciences. The BioOne Digital Library encompasses the flagship aggregation BioOne Complete (<https://bioone.org/subscribe>), the BioOne Complete Archive (<https://bioone.org/archive>), and the BioOne eBooks program offerings ESA eBook Collection (<https://bioone.org/esa-ebooks>) and CSIRO Publishing BioSelect Collection (<https://bioone.org/csiro-ebooks>).

Your use of this PDF, the BioOne Digital Library, and all posted and associated content indicates your acceptance of BioOne's Terms of Use, available at [www.bioone.org/terms-of-use](http://www.bioone.org/terms-of-use).

Usage of BioOne Digital Library content is strictly limited to personal, educational, and non-commercial use. Commercial inquiries or rights and permissions requests should be directed to the individual publisher as copyright holder.

---

BioOne is an innovative nonprofit that sees sustainable scholarly publishing as an inherently collaborative enterprise connecting authors, nonprofit publishers, academic institutions, research libraries, and research funders in the common goal of maximizing access to critical research.

## Visceral and Subcutaneous Acariasis Caused by Hypopi of *Hypodectes propus bulbuci* in the Cattle Egret

Charles M. Hendrix,<sup>1</sup> Robert P. Kwapien,<sup>1</sup> and John R. Porch,<sup>2</sup> <sup>1</sup> Department of Pathology and Parasitology, College of Veterinary Medicine, Auburn University, Alabama 36849, USA; <sup>2</sup> Department of Zoology and Wildlife, College of Science and Mathematics, Auburn University, Alabama 36849, USA

**ABSTRACT:** Twenty-one of 24 adult male and female cattle egrets (*Bubulcus ibis ibis*) collected in Geneva County, Alabama had numerous white cyst-like structures (1,466  $\mu\text{m} \times 354 \mu\text{m}$ ) found within the loose connective tissues of the skeletal muscles of the inguinal region, beneath the serosa of the proventriculus and in the heart beneath the epicardium (one adult male bird). These were identified as hypopi of *Hypodectes (Hypodectoides) propus bulbuci*. Histologic sections were prepared from the subcutis, proventriculus and heart. The histopathologic changes consisted of cross sections of mites surrounded by macrophages often containing basophilic or clear intracytoplasmic vacuoles and by plasma cells. A minimal fibrous encapsulation was rarely seen surrounding the mites.

**Key words:** *Bubulcus ibis ibis*, cattle egret, Hypoderatidae, *Hypodectes (Hypodectoides) propus bulbuci*, hypopal nymph, histopathology, acari, case report.

In 21 of 24 adult male and female cattle egrets (*Bubulcus ibis ibis*) collected for a parasitologic survey in Geneva County, Alabama, numerous white cyst-like structures were noted within the loose connective tissue of the skeletal muscles (Fig. 1), especially those along medial and lateral aspects of the thighs and in the inguinal region. There were no other significant lesions in these birds. Similar cyst-like structures were found beneath the serosa of the proventriculus and in the heart beneath the epicardium of one adult male bird. Several of the subcutaneous cyst-like structures were removed, cleared in Hoyer's medium and recognized as hypopi (heteromorphic deutonymphs) of mites of the family Hypoderatidae (Murray, 1877; OConnor, 1985). These were identified as *Hypodectes (Hypodectoides) propus bulbuci*.

Hypopi have been reported from a variety of wild North American birds. They

are found primarily in the subcutaneous tissues of the limbs and the breast muscles (Pence, 1972) and are reported in a number of visceral sites, including (1) the walls of the large veins of the heart (Garman, 1884), (2) thymus (Kellicott, 1892), (3) peritracheal connective tissue, lungs and pericardial sac, between muscle bundles of the neck and chest (Spurlock and Emlen, 1942), (4) under the upper eyelid (Boyd, 1967), and (5) the gular pouch (Fain and Amerson, 1968). Fain (1967) first described *Hypodectes (Hypodectoides) propus bulbuci* from the subcutaneous tissues of the cattle egret in Africa. Pence (1972) reported hypopi of this species from 9/11 cattle egrets in Louisiana. They were recovered from the subcutaneous tissues of the neck, inguinal area and axillae (D. B. Pence, pers. comm.).

The purpose of this paper is to emphasize the apparent common occurrence of these Acari in numerous wild bird species from many geographical regions. More specifically, because they are rarely mentioned in veterinary medical literature, it should be of practical value to practicing zoo and wildlife veterinarians. We describe the gross morphological appearance in situ in terms of recognition, and the gross and histopathologic changes. Representative specimens of hypopi of *H. propus bulbuci* are deposited in the National Parasite Collection, Beltsville, Maryland 20705, USA (Accession No. 79690).

The elliptical hypopi from the cattle egret measured 1,200 to 1,600  $\mu\text{m}$  ( $\bar{x} = 1,466 \mu\text{m}$ )  $\times$  270 to 460  $\mu\text{m}$  ( $\bar{x} = 354 \mu\text{m}$ ;  $n = 18$ ). The hypopus possessed four pairs of very short legs (Fig. 2). The two anterior pairs of legs (Fig. 2a) were widely separated from the two posterior pairs (Fig.

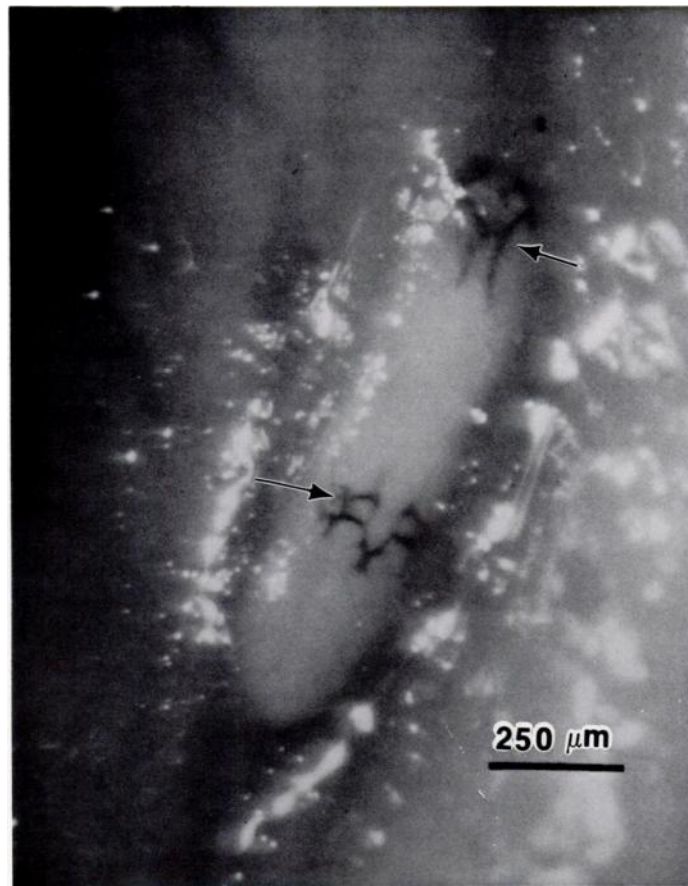


FIGURE 1. Hypopus of *Hypodectes propus bulbuci* within the loose connective tissue at the medial aspect of the thigh of *Bubulcus ibis ibis*. Note the deeply pigmented coxal apodemes of the mite (arrows).

2b). Coxal apodemes surrounded both the anterior and posterior pairs of legs. These chitinous structures function as attachment sites for muscles and as supports for the short, stumpy legs (Beebe, 1902), and were easily discernible using a hand lens or dissecting microscope (Fig. 1). Garman (1884) reported that there were no mouthparts in the hypopus of *H. propus*.

Representative specimens of hypopi were excised with surrounding tissue from the subcutis, proventriculus and heart. These were fixed in buffered 10% formalin, processed by routine histologic procedures, sectioned at 5  $\mu\text{m}$ , and stained with hematoxylin and eosin and the periodic acid-Schiff reaction (PAS).

Histopathologic changes were associated with hypopi of *H. propus bulbuci* in all tissues examined. The subcutaneous tissues adjacent to the skeletal muscle from the thigh contained several cross sections of hypopi. The mites were located within clear spaces surrounded by a thin infiltrate of inflammatory cells, primarily macrophages. Some macrophages contained lightly basophilic or clear vacuoles. The PAS reaction did not stain the vacuoles. However, areas positive with the PAS reaction were observed in the mites. Scattered mites were embedded in the adipose tissue adjoining the wall of the proventriculus. Mites were surrounded by a slight inflammatory infiltrate, mostly macro-

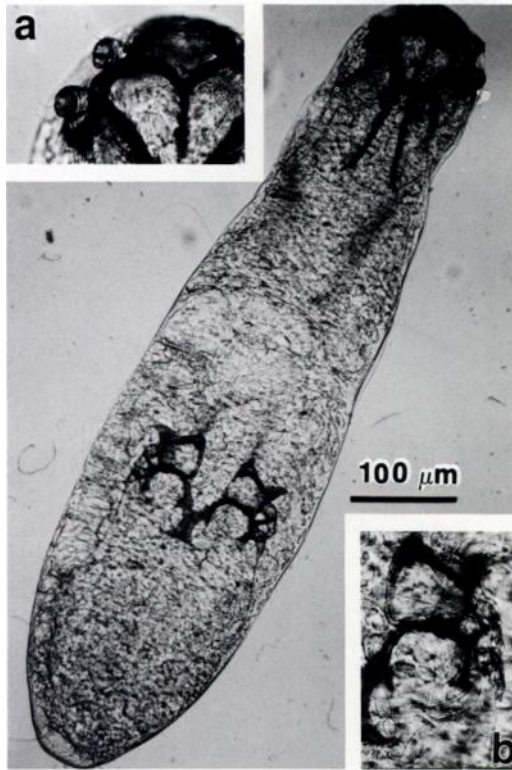


FIGURE 2. Cleared hypopus of *Hypodectes propus bulbuci* from *Bubulcus ibis ibis*. Figure 2a (insert) details head and anterior legs. Figure 2b (insert) details four posterior legs.

phages and plasma cells. A minimal fibrous encapsulation was found around a few hypopi. A few mites embedded in the subepicardial stroma of the heart were surrounded by an inflammatory infiltrate containing macrophages and a few mononuclear inflammatory cells (Fig. 3). Some macrophages contained multiple, pale basophilic vacuoles similar to those in the subcutaneous tissues.

Mites of the family Hypoderatidae live as deutonymphs in the subcutaneous tissues of many orders of birds and occasionally in desert dwelling rodents. Postdeutonymphal stages (adults) of the mites live in the nests of their hosts (OConnor, 1985). Hypopi were theorized to be heteromorphic deutonymphs of feather mites (Robin and Megnin, 1877; Ward, 1894; Boyd,

1967). However, it is now known that many hypopi represent parasitic nymphal stages of free-living adult mites (Fain, 1967; Fain and Bafort, 1967; Pence, 1972; Fain and Philips, 1981; OConnor, 1981, 1985) such as the pigeon hypopus, *Hypodectes propus* (Fain, 1967; Fain and Bafort, 1967). Many of the adult stages associated with these hypopi are unknown (Fain, 1968; Fain and Amerson, 1968; Pence, 1971a, b; Pence, 1973; Pence and Courtney, 1973; Fain and Laurence, 1974, 1979; Young and Pence, 1979; OConnor, 1985). However, in three species of hypopi the adult stage is the only stage that has been described (Fain and Beaucournu, 1972; OConnor, 1981; Fain, 1984).

Clinical signs and/or significant patho-

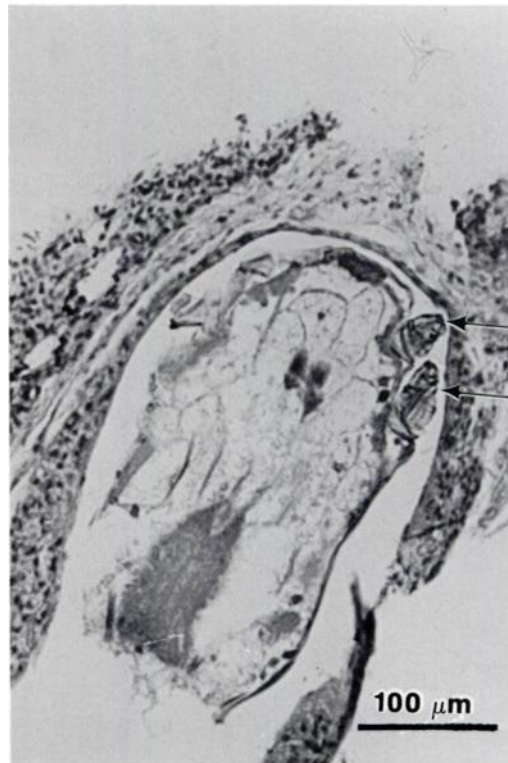


FIGURE 3. Longitudinal section of *Hypodectes propus bulbuci* in subepicardial stroma of the heart of *Bubulcus ibis ibis*. Note the jointed appendages (arrows) and presence of an inflammatory infiltrate containing macrophages and a few mononuclear cells, H&E.

logic findings have not been ascribed to infections of hypoderatid mites. Hypopi usually are found incidentally at necropsy and most studies indicate that hypopi have little effect on their hosts (Beebe, 1902; Spurlock and Emlen, 1942; Pence, 1972). Grünberg and Kutzer (1962) described histopathologic changes associated with infection of hypopi in the Indian white-headed ibis, *Tantalus leucocephalus*: "The pathology was localized in the subcutaneous tissues where there was evidence of a slight proliferation of the lymph and small blood vessels, connective tissue infiltration around some of the hypopi, infiltrated and swollen ground substance with abundant collagen fibers in some areas, and a large amount of lipid in and around the hypopi with some evidence of lipid absorption by the parasite." Schwan and Sileo (1978) reported hypopi of *Neottialges* (*Pelecanectes*) *evansi* in the subcuticular connective tissue of the axillae, thorax and thigh of a white-necked cormorant, *Phalacrocorax carbo*. The mites produced a raised, rough, brownish mass in the dermis. Hypopal nymphs were embedded in tissue comprised of a few fusiform fibroblastic cells between infiltrations of macrophages that contained cytoplasmic vacuoles of variable sizes. Foci of lymphocytes were scattered also throughout the mass. The only evidence of encapsulation was the circumferentially oriented histiocytes. There are no reports of movement or tracts due to the migration of hypopi in tissue. Although it has been noted that hypopi do not visibly move within their cysts, slow waving movements of the legs and subsequent abdominal constrictive movements have been observed when the parasites were extracted from cysts and placed in water (Spurlock and Emlen, 1942).

Antemortem diagnosis of the mites in situ has been reported by incising the skin over the breast muscle and by examining for the presence of hypopi in the subcutis. Although treatment with iodine has been recommended (Beebe, 1902), this thera-

peutic regimen is ineffective (Ward, 1902). Because ivermectin is a potent acaricide against *Knemidocoptes* spp. and many other parasitic mites in fowl, it may be an effective treatment for hypopal acariasis in wild and domestic birds (Clubb, 1986).

We thank Barry M. O'Connor of the Museum of Zoology, The University of Michigan, Ann Arbor, Michigan and Benjamin Tuggle of the Grambling Cooperative Wildlife Project, Grambling State University, Louisiana for assistance in identifying the hypopi. This is publication number 1883 of the Auburn University College of Veterinary Medicine.

#### LITERATURE CITED

- BEEBE, C. W. 1902. Preliminary observations on a subdermal mite occurring among the birds in the New York zoological park. *Science* 15: 754-755.
- BOYD, E. M. 1967. Deutonymphs as endoparasites of the Eastern belted kingfisher and the Eastern green heron in North America. *Proceedings of the Entomological Society of Washington* 69: 73-81.
- CLUBB, S. L. 1986. Therapeutics. Individual and flock treatment regimens. In *Clinical avian medicine and surgery, including aviculture*, G. J. Harrison and L. R. Harrison (eds.). W. B. Saunders Co., Philadelphia, Pennsylvania, pp. 327-355.
- FAIN, A. 1967. Les hypopes parasites des tissus cellulaires des oiseaux (Hypodectidae: Sarcoptiformes). *Bulletin de l'Institut Royal des Sciences Naturelles de Belgique* 43: 1-139.
- . 1968. A new heteromorphic deutonymph (hypopus) of a sarcoptiform mite parasitic under the skin of a toucan. *Journal of Natural History* 2: 459-461.
- . 1984. A new hypoderid mite from the nest of a vulture in South Africa. *Revue de Zoologie Africaine* 98: 719-724.
- , AND A. B. AMERSON, JR. 1968. Two new heteromorphic deutonymphs (hypopi) (Acarina: Hypoderidae) from the great frigatebird (*Fregata minor*). *Journal of Medical Entomology* 5: 320-324.
- , AND J. BAFORT. 1967. Cycle évolutif et morphologie de *Hypodectes* (*Hypodectoides*) *propus* (Nitzsch) acarien nidicole à deutonymphe parasite tissulaire des pigeons. *Bulletin de l'Académie Royale Belgique, Classe des Sciences* 53: 501-533.
- , AND J. C. BEAUCOURNU. 1972. Observations sur le cycle évolutif de *Pelecanectes evansi*

- Fain et description d'une espèce nouvelle du genre *Phalacrodes* Fain (Hypoderidae: Sarcop-  
tiformes). *Acarologia* 13: 374-382.
- , AND B. R. LAURENCE. 1974. A guide to the  
heteromorphic deutonymphs or hypopi (Acarina:  
Hypoderidae) living under the skin of birds,  
with the description of *Ibisidectes debilis* gen.  
and sp. nov. from the scarlet ibis. *Journal of Nat-  
ural History* 8: 223-230.
- , AND ———. 1979. *Neottialges* (*Peleca-  
nectes*) *platalea* sp. nov. and other hypoderid  
mites (Acarina, Astigmata, Hypoderidae) from  
the spoonbill, *Platalea leucorodia* L. *Journal of  
Natural History* 13: 333-336.
- , AND J. R. PHILIPS. 1981. Astigmatic mites  
from nests of birds of prey in U.S.A. VI. The  
adult forms of *Echimyopus orphanus* Fain &  
Philips, 1977 and of *Dermacarus pilitarsus* Fain  
& Philips, 1977. *International Journal of Aca-  
rology* 7: 235-238.
- GARMAN, H. 1884. *Pterolichus falciger* Megnin,  
observed in the United States. *American Natu-  
ralist* 18: 430-431.
- GRÜNBERG, W., AND E. KUTZER. 1962. Deutonym-  
phen von federmilben in der subkutis von *Tan-  
tulus leucocephalus* (indischer nimmersatt). *Zeit-  
schrift für Parasitenkunde* 21: 542-599.
- KELLCOTT, D. S. 1892. *Hypoderas columbae*—A  
note. *Insect Life* 5: 77-78.
- MURRAY, A. 1877. *Economic entomology*, Aptera.  
Chapman & Hall, Piccadilly, England, pp. 227-  
330.
- O'CONNOR, B. M. 1981. A new genus and species  
of Hypoderidae (Acari: Astigmata) from the nest  
of an owl (Aves: Strigiformes). *Acarologia* 22:  
299-304.
- . 1985. Hypoderatid mites (Acari) associated  
with cormorants (Aves: Phalacrocoracidae), with  
description of a new species. *Journal of Medical  
Entomology* 22: 324-331.
- PENCE, D. B. 1971a. *Toucanectes dryocopi* sp. n.  
(Acarina: Hypoderidae) from the pileated wood-  
pecker, *Dryocopus pileatus* L. *The Journal of  
Parasitology* 57: 1318-1320.
- . 1971b. The hypopi (Acarina: Hypoderidae)  
from the subcutaneous tissues of the white ibis,  
*Eudocimus albus* L. *The Journal of Parasitology*  
57: 1321-1323.
- . 1972. The hypopi (Acarina: Sarcop-  
tiformes: Hypoderidae) from the subcutaneous tis-  
sues of birds in Louisiana. *Journal of Medical  
Entomology* 9: 435-438.
- . 1973. Hypopi (Acarina: Hypoderidae) from  
the subcutaneous tissues of the wood ibis, *My-  
cteria americana* L. *Journal of Medical Ento-  
mology* 10: 240-243.
- , AND C. H. COURTNEY. 1973. The hypopi  
(Acarina: Hypoderidae) from the subcutaneous  
tissues of the brown pelican, *Pelecanus occiden-  
talis carolinensis* Gmelin. *The Journal of Par-  
asitology* 59: 711-718.
- ROBIN, C., AND P. MÉGNIN. 1877. Mémoire sur les  
sarcoptides plumicoles. X. Description particu-  
lière des genres et des espèces de sarcoptides  
plumicoles. *Journal l'Anatomie et de la Physio-  
logie Normales et Pathologiques de l'Homme et  
des Animaux* 13: 391-429.
- SCHWAN, T. G., AND L. SILEO. 1978. *Neottialges*  
(*Pelecanectes*) *evansi* (Sarcoptiformes: Hypo-  
deridae) parasitizing a white-necked cormorant  
in Kenya. *Journal of Medical Entomology* 14:  
522.
- SPURLOCK, G. M., AND J. T. EMLIN. 1942. *Hypo-  
dectes chapini* n. sp. (Acarina) from the red-  
shafted flicker. *The Journal of Parasitology* 28:  
341-344.
- WARD, H. B. 1894. On the pigeon mite, *Hypodectes*  
*filippi*. *Psyche* 8: 95-100.
- . 1902. The subdermal mite occurring among  
birds. *Science* 15: 911.
- YOUNG, V. E., AND D. B. PENCE. 1979. *Neottialges*  
(*Pelecanectes*) *ibisicola* sp. n. (Acari: Hypode-  
ridae) from the subcutaneous tissues of the white-  
faced ibis, *Plegadis chihi* (Ciconiiformes: Thres-  
kiornithidae). *The Journal of Parasitology* 65: 659-  
661.

Received for publication 18 December 1986.