

## **BLUETONGUE IN FREE-RANGING PRONGHORN ANTELOPE (ANTILOCAPRA AMERICANA) IN WYOMING: 1976 AND 1984**

Authors: Thorne, E. T., Williams, E. S., Spraker, T. R., Helms, W., and Segerstrom, T.

Source: Journal of Wildlife Diseases, 24(1) : 113-119

Published By: Wildlife Disease Association

URL: <https://doi.org/10.7589/0090-3558-24.1.113>

---

The BioOne Digital Library (<https://bioone.org/>) provides worldwide distribution for more than 580 journals and eBooks from BioOne's community of over 150 nonprofit societies, research institutions, and university presses in the biological, ecological, and environmental sciences. The BioOne Digital Library encompasses the flagship aggregation BioOne Complete (<https://bioone.org/subscribe>), the BioOne Complete Archive (<https://bioone.org/archive>), and the BioOne eBooks program offerings ESA eBook Collection (<https://bioone.org/esa-ebooks>) and CSIRO Publishing BioSelect Collection (<https://bioone.org/csiro-ebooks>).

Your use of this PDF, the BioOne Digital Library, and all posted and associated content indicates your acceptance of BioOne's Terms of Use, available at [www.bioone.org/terms-of-use](http://www.bioone.org/terms-of-use).

Usage of BioOne Digital Library content is strictly limited to personal, educational, and non-commercial use. Commercial inquiries or rights and permissions requests should be directed to the individual publisher as copyright holder.

---

BioOne is an innovative nonprofit that sees sustainable scholarly publishing as an inherently collaborative enterprise connecting authors, nonprofit publishers, academic institutions, research libraries, and research funders in the common goal of maximizing access to critical research.

## BLUETONGUE IN FREE-RANGING PRONGHORN ANTELOPE (*ANTILOCAPRA AMERICANA*) IN WYOMING: 1976 AND 1984

E. T. Thorne,<sup>1,6</sup> E. S. Williams,<sup>2</sup> T. R. Spraker,<sup>3</sup> W. Helms,<sup>4</sup> and T. Segerstrom<sup>5</sup>

<sup>1</sup> Wyoming Game and Fish Department, Box 3312, University Station,  
Laramie, Wyoming 82071, USA

<sup>2</sup> Department of Veterinary Sciences, University of Wyoming, 1190 Jackson,  
Laramie, Wyoming 82070, USA

<sup>3</sup> Wild Animal Disease Center, Department of Pathology,  
College of Veterinary Medicine and Biomedical Sciences,  
Colorado State University, Fort Collins, Colorado 80523, USA

<sup>4</sup> Wyoming Game and Fish Department, Box 635, Lusk, Wyoming 82225, USA

<sup>5</sup> Wyoming Game and Fish Department, 116B Four Corners Rd., Gillette, Wyoming 82716, USA

<sup>6</sup> Author to whom correspondence should be addressed

**ABSTRACT:** At least 3,200 pronghorn (*Antilocapra americana*) died during a bluetongue (BT) epizootic in eastern Wyoming during late September and early October 1976. In August and September 1984, another BT epizootic occurred in northeastern Wyoming resulting in 300 known pronghorn deaths. In 17 pronghorn examined postmortem, hemorrhages and edema were the most common gross pathologic changes. Microscopic changes included hemorrhage, edema, arterial fibrinoid necrosis, lymphoid depletion in splenic and lymphatic follicles, and neuronal necrosis. Bluetongue virus serotype 17 was isolated from pronghorn in both epizootics. Mortalities ceased with the advent of cool weather in late September and October. Seventy-six of 94 pronghorn killed by hunters during the latter period of the 1976 epizootic, and 14 of 24 pronghorn killed 1 yr later had serologic evidence of exposure to BT virus. The reproductive rate in pronghorn was depressed to 47 fawns per 100 does in August 1977, but returned to 93 fawns per 100 does by 1978. Following the 1984 outbreak, the reproductive rate was similarly depressed, but the cause was confounded by other environmental and range conditions. Deer, mostly mule deer (*Odocoileus hemionus*), also died during both epizootics of what was presumed to be BT.

**Key words:** Bluetongue virus, *Antilocapra americana*, pronghorn, epizootic, reproductive rate, mule deer, *Odocoileus hemionus*.

### INTRODUCTION

Bluetongue (BT) is an important viral disease of domestic sheep and has been recognized as a significant disease of cattle (Luedke et al., 1964, 1970; Goltz, 1978). Prior experience with BT virus has been demonstrated serologically and/or by virus isolation in a number of North American wild ruminants including elk (*Cervus elaphus nelsoni*), bighorn sheep (*Ovis canadensis*), moose (*Alces alces*), mule deer (*Odocoileus hemionus*), black-tailed deer (*O. hemionus columbianus*), white-tailed deer (*O. virginianus*), and pronghorn (*Antilocapra americana*) (Trainer and Jochim, 1969; Hoff and Trainer, 1978, 1981; Johnson et al., 1986). Bluetongue virus infection was produced experimentally in white-tailed deer (Karstad and Trainer, 1967; Vosdingh et al., 1968; Thomas and Trainer, 1970), elk (Murray and Trainer, 1970; Stott et al., 1982), and pronghorn

(Hoff and Trainer, 1972). Bluetongue and/or epizootic hemorrhagic disease (EHD) were diagnosed as the cause of death of two captive pronghorn in Oregon (Kistner et al., 1975).

Bluetongue has been diagnosed in free-ranging white-tailed deer (Stair et al., 1968; Prestwood et al., 1974; Thomas, 1981), mule deer (Kistner et al., 1975) and desert bighorn sheep (Robinson et al., 1967). Bluetongue was suspected as a cause of illness and death of free-ranging pronghorn in Oregon, but the virus was not isolated from affected animals (Kistner et al., 1975). The purpose of this report is to describe two epizootics of BT that occurred among free-ranging pronghorn in eastern Wyoming in 1976 and 1984, respectively.

### HISTORY

On 8 September 1976, pronghorn mortalities in Campbell and Sheridan counties,

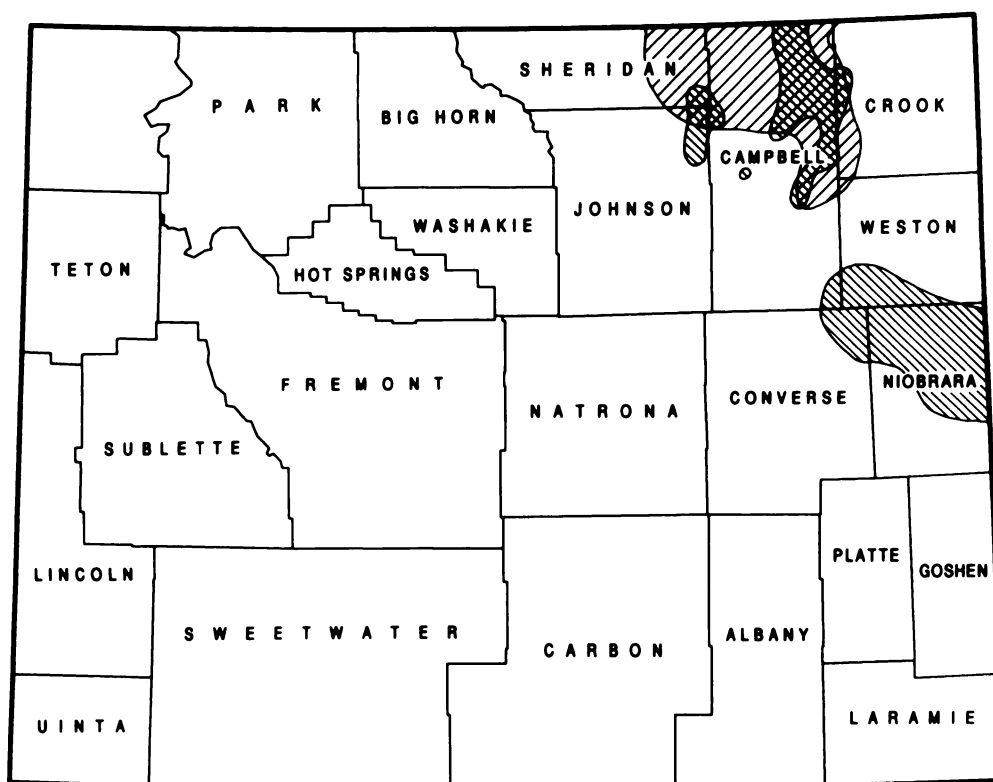


FIGURE 1. Map of the state of Wyoming depicting the counties and distribution of pronghorn mortalities associated with bluetongue virus during the 1976 (▨) and 1984 (▩) epizootics.

Wyoming (Fig. 1) were reported to a game warden who examined a dead animal in the field and collected samples for laboratory examination. Two days later in Niobrara County, additional deaths were reported and a diseased pronghorn was shot and submitted for necropsy. Over a 24-day period beginning 8 September, losses occurred in seven counties (Fig. 1) and 11 pronghorn were necropsied. Tissue samples from four additional pronghorn were examined. The pronghorn and samples were collected in four contiguous counties (Campbell, Niobrara, Converse, and Weston) and BT was subsequently diagnosed. Pronghorn mortalities were reported in Goshen County, but were not documented. Deer losses were reported but carcasses were not available for necropsy.

In late August 1984, numerous pronghorn mortalities were investigated near

Gillette in Campbell County. A recently dead pronghorn was transported to the Wyoming State Veterinary Laboratory (University of Wyoming, Laramie, Wyoming 82071, USA) where a gross diagnosis of hemorrhagic disease was made. Several days later an additional pronghorn carcass with similar lesions was examined at the laboratory. Pronghorn mortalities were documented in Sheridan, Campbell, Crook, Weston, and Johnson counties (Fig. 1). White-tailed and mule deer losses were reported in Campbell County.

#### MATERIALS AND METHODS

Tissue specimens collected at necropsy were fixed in 10% neutral buffered formalin, embedded in paraffin, sectioned at 7  $\mu$ m and stained with hematoxylin and eosin. Selected samples were removed aseptically for standard bacteriologic studies. For virus isolation in 1976, portions of spleens were collected and stored at  $-70^{\circ}\text{C}$ .

C or minced and stored in oxalate-phenol-glycerine at 4 C. In 1984, spleens and whole blood mixed with ethylene-diamine tetraacetic acid were refrigerated. Virus isolations were conducted by the National Veterinary Services Laboratory (U.S. Department of Agriculture, Ames, Iowa 50010, USA) by inoculation of specimens onto Vero monolayer cell cultures grown in roller tubes (Bando, 1975) and intravenously into embryonated chicken eggs (Foster and Luedke, 1968). These systems were tested for the presence of BT and epizootic hemorrhagic disease (EHD) viruses by the fluorescent antibody cell culture technique (Jochim et al., 1974). Isolated viruses were serotyped (Barber and Jochim, 1975; Jochim and Jones, 1976) at the Arthropod-borne Animal Disease Research Laboratory (ABADRL; U.S. Department of Agriculture, Denver, Colorado 80225, USA).

Sera were collected from blood samples taken from moribund pronghorn killed for necropsy and from hunter-killed pronghorn, mule deer, and a few white-tailed deer near Redbird in Niobrara County, one of the most severely affected areas in 1976. In October 1977, additional serum samples were collected from hunter-killed animals. These sera were tested for antibodies against BT and EHD viruses using the modified direct complement fixation (MDCF) test (Robertson et al., 1965; Boulanger et al., 1967) and agar gel precipitin (AGP) test (Jochim and Chow, 1969; Pearson and Jochim, 1979). Serologic tests were conducted by the Wyoming State Veterinary Laboratory (WSVL), National Veterinary Services Laboratory, or the ABADRL.

Splenic tissue from two diseased pronghorn was triturated in Tenbrock grinders, suspended in Earle's saline, centrifuged, and the supernatant fluid was inoculated subcutaneously into 2-mo-old domestic lambs in 1976. Febrile and serologic responses were followed in the lambs which were negative for BT antibody by the MDCF test at the time of inoculation.

Routine pre hunting season fawn: doe ratios were determined by Wyoming Game and Fish Department management personnel in 1977, 1978, 1983, 1984, and 1985.

## RESULTS

### Clinical signs

Observable signs of BT in free-ranging pronghorn persisted from 1 to 6 days. Some animals, which had shown no previous signs of illness, died suddenly when disturbed. Others were anorectic for several days, during which time they became more sed-

entary and finally remained in one area. Many were recumbent and were reluctant to move or run when approached. Tracks and observations indicated that some pronghorn died suddenly while walking or running. Others struggled in lateral recumbency for several hours or longer before dying. All sex and age classes were affected.

### Gross pathology

Hemorrhages and edema were the most common gross pathologic changes observed at necropsy. Pericardial, subepicardial and subendocardial hemorrhage and/or edema and hemorrhage in tunica adventitia of the dorsal aorta and pulmonary artery were present in most pronghorn examined.

Frequently, the most striking pathologic change was a large amount of clear yellow fluid in the thoracic cavity which clotted following exposure to air. Pulmonary edema occurred in most animals and usually was severe. Hemorrhage occasionally was present in the lungs and subintimally in the pulmonary artery. Edema and/or hemorrhages were often observed in the intercartilaginous ligaments of the trachea and subcutaneous tissue of the lower neck, brisket, and hind legs.

Varying degrees of hemorrhage were often present in the gastrointestinal tract, with the abomasum, rumen, and cecum most frequently involved. Ruminal and cecal hemorrhages usually were most pronounced on the serosal surface and were often ecchymotic, while abomasal hemorrhages usually consisted of few to very numerous petechia visible on the mucosal surface. Hemorrhages were occasionally observed in various lymph nodes, urinary bladder, synovial surfaces of joint capsules, conjunctiva, inter- and intramuscularly, renal pelvis, thymus, testicle, and under the parietal peritoneum and pleura.

In some pronghorn, the skeletal musculature was pale and the spleen was soft and engorged with blood. Corneas were opaque in one animal which was reported

to be blind. Most pronghorn were in fair to good physical condition at the time of death, based on the amount of body fat.

#### **Histopathology**

The histopathologic description of BT in pronghorn is based upon a summary of the lesions from nine animals. Mild to severe, acute hemorrhages were in the myocardium and under the epicardium and endocardium. Occasionally thromboses and fibrinoid necrosis of the tunica media of small arteries and arterioles within the lamina propria of the digestive tract and perilymphoid connective tissue were observed. Edema and occasionally hemorrhages were present in the lamina propria and intercartilaginous ligament of the trachea and lamina propria of bronchi. Eosinophilic exudate filled many alveolar spaces and lumina of bronchi and bronchioles. Fibrin and a few macrophages were occasionally present in bronchi, bronchioles and alveolar spaces.

Lymphoid follicles in spleen and lymph nodes often were hypocellular. Vascular congestion and sinusoidal edema and hemorrhage occurred in some lymph nodes. Mild central lobular hepatic lipidosis occurred in a few pronghorn. Numerous small hemorrhages and congested capillaries were seen within the lamina propria of the abomasum. Focal hemorrhages occurred between tubules in the kidney and in the adrenal cortex. In a few pronghorn, congestion and focal necrosis with vacuolation of the neuropil and axonal swelling were observed in cerebellum, cerebral cortex, ventral brain stem and thalamus.

#### **Virology**

Bluetongue virus serotype 17 was isolated from tissues of three of five pronghorns in 1976 and two of two animals in 1984 by inoculation into embryonated chicken eggs. Neither pathogenic bacteria nor EHD virus was isolated. One of the two domestic lambs inoculated with pronghorn splenic suspension died in 3 days of *Clostridium* sp. infection. The other de-

veloped a very mild febrile response during postinoculation days 2 through 7. That sheep also developed a serologic response to the MDCF test against BT and EHD viruses which peaked at 1:40 on day 51 postinoculation.

#### **Serology**

Sera from the three pronghorn from which BT virus was isolated in 1976 were MDCF test positive for BT antibodies at 1:10 through 1:40 dilutions. One sample was EHD antibody negative, one was anticomplementary, and one reacted at the 1:20 dilution to the MDCF test. The AGP test was conducted on one BT virus positive pronghorn and was positive for both BT and EHD antibodies. Serum from another pronghorn in which BT was diagnosed was AGP positive for BT and EHD antibodies, and MDCF test positive for BT antibodies at 1:80. Unfortunately, samples from this animal were not submitted for virus isolation.

Seventy-six (81%) of 94 hunter-killed pronghorn blood samples and 36 (95%) of 38 deer (mostly mule deer) blood samples collected during the last few days of the epizootic in 1976 had serologic evidence of exposure to BT virus by the AGP and/or MDCF tests. Similar percentages were EHD antibody positive on the AGP test.

Blood samples were collected from hunter-killed animals in the same locality 1 yr later. Fifteen (60%) of 25 pronghorn were positive for BT antibody and 12 of 25 were positive for EHD antibody by the AGP test. One (4%) of 25 was positive for BT antibody by the MDCF test. Five (11%) of 45 deer were positive for BT antibody by the MDCF test; 32 (71%) were positive for BT and 25 (56%) were positive for EHD antibodies by the AGP test. Due to hunter selection of adults, few hunter-killed samples were from fawns during either year.

#### **Mortality estimates**

Mortality estimates were based on carcass counts by Wyoming Game and Fish Department personnel during ground and

aerial surveys and from landowner and hunter observations. Usually, mortalities from local areas were difficult to quantify because of very subjective estimates by untrained individuals. Accurate determination of mortalities was difficult due to the large areas involved in the epizootics, rapid decomposition of carcasses in warm weather and scavengers.

At least 3,200 pronghorn mortalities were estimated in the 1976 BT outbreak. Additionally, 1,000 deer (mostly mule deer) were estimated to have died. While deer carcasses suitable for necropsy were not recovered, BT was believed to be responsible for the deaths.

The epizootic apparently followed the drainage of the Cheyenne River. Initially, pronghorn carcasses were noted along drainages or near stock ponds, but subsequent aerial transects revealed dead pronghorn scattered throughout the area with no apparent association with the water courses. Pronghorn mortalities were greatest during the last 2 wk of September and subsided with the advent of cooler weather in early October.

In 1984, 288 pronghorn, 83 mule deer, and 13 white-tailed deer carcasses were found in the area of the epizootic. The total number that died was unknown, but an estimated 2–3% of pronghorn in the area succumbed. In one pronghorn hunt area there was an estimated 4–5% mortality. Based on the population sizes at that time, actual losses could have been 600–1,000 pronghorn. Deer mortality was believed to be <1%.

#### **Postepizootic pronghorn reproduction**

Fawn:doe ratios were obtained in August of 1977 and 1978 near Redbird and in another similar area in Niobrara County that was not affected by the BT epizootic. In 1977, 1 yr after the epizootic, the fawn:doe ratio in the BT affected area was 47:100. Outside the BT affected area it was 101:100. Two yr after the epizootic, fawn:doe ratios were 93:100 in the BT affected area and 86:100 in the unaffected area.

Pronghorn reproduction in 1984, prior to the BT outbreak, was 72 fawns/100 does compared to 106 fawns/100 does in 1983. The 1984 decline was believed to have been caused by a late, severe spring storm that severely stressed females 3 wk prepartum. In 1985, 1 yr following the BT outbreak, reproduction remained depressed to 70 fawns/100 does, but the determination of the cause of the lowered reproductive rate was confounded by simultaneous drought, grasshopper infestation, and a dramatic decline in the alternate prey species for large predators.

#### **DISCUSSION**

Similarities of BT and EHD in white-tailed deer have been noted (Karstad and Trainer, 1967) and an outbreak of hemorrhagic disease in white-tailed deer caused by BT and EHD viruses was reported (Prestwood et al., 1974). Although it is possible that both BT and EHD viruses were responsible for the pronghorn epizootics reported herein, we assume that this did not occur because of failure to isolate EHD virus. The associated deer mortalities were assumed to result from BT because of their occurrence and distribution in areas of BT virus-induced pronghorn deaths.

Pathologic changes in free-ranging pronghorn spontaneously infected with BT virus in Wyoming were similar to those reported in two captive pronghorn infected with BT and/or EHD viruses in Oregon (Kistner et al., 1975). They were more severe than those reported in two captive pronghorn which died following artificial inoculation with BT virus strain BT-8 (Serotype 10) (Hoff and Trainer, 1972). Two additional artificially-inoculated pronghorn which possessed BT virus neutralizing antibody prior to inoculation did not show clinical signs of BT and had no lesions characteristic of BT at necropsy (Hoff and Trainer, 1972). Luedke et al. (1976) noted that in domestic sheep the clinical response to BT virus was more severe in animals infected via vector bites than in those inoculated with infective blood.

Pathology associated with experimental BT in domestic sheep and white-tailed deer has been described (Moulton, 1961; Luedke et al., 1964; Karstad and Trainer, 1967; Thomas and Trainer, 1970). A major difference in the lesions observed in naturally-infected pronghorn dying of acute BT versus those in sheep and white-tailed deer was the absence of oral and foot lesions in pronghorn. Wyoming Game and Fish Department field personnel were asked to watch for lameness in surviving pronghorn, but lame animals were not observed.

Trainer and Jochim (1969) reported serologic evidence of BT infection in eight of 96 hunter-killed pronghorn in central and western Wyoming during the fall of 1963. They also reported regional differences in reactor rates between Wyoming and Colorado and among four geographic areas in Colorado. In 1976 and 1984, BT in pronghorn was also of limited regional distribution in Wyoming. All of 79 hunter-killed pronghorn in late August 1977 in Carbon County, Wyoming, approximately 200 km southwest of Redbird, were negative for BT antibody by the AGP and MDCF tests.

Although observers in the field felt there was a very high mortality rate among pronghorn which became clinically ill, the high prevalence of BT antibody detected late in the 1976 epizootic suggested a high rate of exposure and much lower mortality. Reduced, but relatively high, reactor rates for BT in 1977 indicated reinfection or persistence of BT antibody.

The fawn:doe ratios obtained 1 yr after the BT epizootics in 1976 and 1984 indicated reproductive impairment following the epizootics. The pronghorn breeding season coincided with the epizootics, and surviving does were in very early gestation when exposed to BT virus. Fetal losses and neonatal deaths are reported in cattle, domestic sheep, and white-tailed deer following BT (Thomas and Trainer, 1970; Bowne, 1973; Erasmus, 1975; Hourrigan and Klingsporn, 1975; Luedke, 1985). The possibility that BT may effect pronghorn

populations via reduced reproduction, in addition to causing direct mortality, is of concern to game managers. Effects of BT on pronghorn reproduction deserves additional study.

#### ACKNOWLEDGMENTS

We acknowledge the assistance of personnel of Districts 3 and 7, Game Division, Wyoming Game and Fish Department. Without the effort of these field personnel, who included S. Clark, T. Cram, L. Donahue, D. Early, B. Williams, and R. Wilson, this study would not have been possible. The concern, interest, help, and hospitality of the many ranchers of the area are greatly appreciated. We would like also to acknowledge the assistance of personnel of the National Veterinary Services Laboratory, U.S. Department of Agriculture, Ames, Iowa; the Wyoming State Veterinary Laboratory, Laramie, Wyoming; and the Arthropod-borne Animal Disease Research Laboratory, Denver, Colorado. This investigation was supported in part by Federal Aid to Wildlife Restoration, Wyoming Project FW-3-R.

#### LITERATURE CITED

- BANDO, B. M. 1975. Isolation of bluetongue and epizootic hemorrhagic disease viruses in cell culture. *Proceedings of the American Association of Veterinary Laboratory Diagnosticians* 18: 163-174.
- BARBER, T. L., AND M. M. JOCHIM. 1975. Serotyping bluetongue and epizootic hemorrhagic disease virus strains. *Proceedings of the American Association of Veterinary Laboratory Diagnosticians* 18: 149-162.
- BOULANGER, P., G. M. RUCKERBAUER, G. L. BANNISTER, D. P. GRAY, AND A. GIRARD. 1967. Studies on bluetongue. III. Comparison of two complement-fixation methods. *Canadian Journal of Comparative Medicine and Veterinary Science* 31: 166-170.
- Bowne, J. G. 1973. Is bluetongue an important disease in cattle? *Journal of the American Veterinary Medical Association* 163: 911-914.
- ERASMUS, B. J. 1975. Bluetongue in sheep and goats. *Australian Veterinary Journal* 51: 165-170.
- FOSTER, N. M., AND A. J. LUEDKE. 1968. Direct assay for bluetongue virus by intravascular inoculation of embryonating chicken eggs. *American Journal of Veterinary Research* 29: 749-753.
- GOLTZ, J. 1978. Bluetongue in cattle: A review. *Canadian Veterinary Journal* 19: 95-98.
- HOFF, G. L., AND D. O. TRAINER. 1972. Bluetongue virus in pronghorn antelope. *American Journal of Veterinary Research* 33: 1013-1016.
- , AND ———. 1978. Bluetongue and epi-

- zootic hemorrhagic disease viruses: Their relationship to wild species. *Advances in Veterinary Science and Comparative Medicine* 22: 111–132.
- , AND ———. 1981. Hemorrhagic diseases of wild ruminants. In *Infectious diseases of wild mammals*, 2nd ed., J. W. Davis, L. H. Karstad, and D. O. Trainer (eds.). Iowa State University Press, Ames, Iowa, pp. 45–53.
- HOURLIGAN, J. L., AND A. L. KLINGSPORN. 1975. Bluetongue: The disease in cattle. *Australian Veterinary Journal* 51: 170–174.
- JOCHIM, M. M., T. L. BARBER, AND B. M. BANDO. 1974. Identification of bluetongue and epizootic hemorrhagic disease viruses by the indirect fluorescent antibody procedure. *Proceedings of the American Association of Veterinary Laboratory Diagnosticians* 17: 91–103.
- , AND T. L. CHOW. 1969. Immunodiffusion of bluetongue virus. *American Journal of Veterinary Research* 30: 33–41.
- , AND S. C. JONES. 1976. Plaque neutralization of bluetongue virus and epizootic hemorrhagic disease virus in BHK<sub>21</sub> cells. *American Journal of Veterinary Research* 37: 1345–1347.
- JOHNSON, J. L., T. L. BARBER, M. L. FREY, AND G. NASON. 1986. Serosurvey for selected pathogens in hunter-killed pronghorns in western Nebraska. *Journal of Wildlife Diseases* 22: 87–90.
- KARSTAD, L., AND D. O. TRAINER. 1967. Histopathology of experimental bluetongue disease of white-tailed deer. *Canadian Veterinary Journal* 8: 247–254.
- KISTNER, T. P., G. E. REYNOLDS, L. D. KOLLER, C. E. TRAINER, AND D. L. EASTMAN. 1975. Clinical and serological findings on the distribution of bluetongue and epizootic hemorrhagic disease viruses in Oregon. *Proceedings of the American Association of Veterinary Laboratory Diagnosticians* 18: 135–147.
- LUEDKE, A. J. 1985. Effect of bluetongue virus on reproduction in sheep and cattle. In *Bluetongue and related orbiviruses*, T. L. Barber and M. M. Jochim (eds.). Alan R. Liss, Inc., New York, New York, pp. 71–78.
- , J. G. BOWNE, M. M. JOCHIM, AND C. DOYLE. 1964. Clinical and pathologic features of bluetongue in sheep. *American Journal of Veterinary Research* 25: 963–970.
- , M. M. JOCHIM, J. G. BOWNE, AND R. H. JONES. 1970. Observations on latent bluetongue virus infection in cattle. *Journal of the American Veterinary Medical Association* 156: 1871–1879.
- , R. J. JONES, AND M. M. JOCHIM. 1976. Serial cyclic transmission of bluetongue virus in sheep and *Culicoides variipennis*. *Cornell Veterinarian* 66: 536–550.
- MOULTON, J. E. 1961. Pathology of bluetongue of sheep. *Journal of the American Veterinary Medical Association* 138: 493–498.
- MURRAY, J. O., AND D. O. TRAINER. 1970. Bluetongue virus in North American elk. *Journal of Wildlife Diseases* 6: 144–148.
- PEARSON, J. E., AND M. M. JOCHIM. 1979. Protocol for the immunodiffusion test for bluetongue. *Proceedings of the American Association of Veterinary Laboratory Diagnosticians* 22: 463–471.
- PRESTWOOD, A. K., T. P. KISTNER, F. E. KELLOGG, AND F. A. HAYES. 1974. The 1971 outbreak of hemorrhagic disease among white-tailed deer in the southeastern United States. *Journal of Wildlife Diseases* 6: 144–148.
- ROBERTSON, A., M. APPEL, G. L. BANNISTER, G. M. RUCKERBAUER, AND P. BOULANGER. 1965. Studies of bluetongue. II. Complement-fixing activity of ovine and bovine sera. *Canadian Journal of Comparative Medicine and Veterinary Science* 29: 113–117.
- ROBINSON, R. M., T. L. HAILEY, C. W. LIVINGSTON, AND J. W. THOMAS. 1967. Bluetongue in the desert bighorn sheep. *The Journal of Wildlife Management* 31: 165–168.
- STAIR, E. L., R. M. ROBINSON, AND L. P. JONES. 1968. Spontaneous bluetongue in Texas white-tailed deer. *Veterinary Pathology* 5: 164–173.
- STOTT, J. L., L. H. LAUERMAN, AND A. J. LUEDKE. 1982. Bluetongue virus in pregnant elk and their calves. *American Journal of Veterinary Research* 43: 423–428.
- THOMAS, F. C. 1981. Hemorrhagic disease. In *Diseases and parasites of white-tailed deer*, W. R. Davidson, F. A. Hayes, V. F. Nettles, and F. E. Kellogg (eds.). Tall Timbers Research Station, Tallahassee, Florida, pp. 87–96.
- , AND D. O. TRAINER. 1970. Bluetongue virus in white-tailed deer. *American Journal of Veterinary Research* 31: 271–278.
- TRAINER, D. O., AND M. M. JOCHIM. 1969. Serologic evidence of bluetongue in wild ruminants of North America. *American Journal of Veterinary Research* 30: 2007–2011.
- VOSDINGH, R. A., D. O. TRAINER, AND B. C. EASTERDAY. 1968. Experimental bluetongue disease in white-tailed deer. *Canadian Journal of Comparative Medicine and Veterinary Science* 32: 382–387.

Received for publication 1 December 1986.