

An Internal X-Cell Pseudotumor in a Black Croaker (*Cheilotrema saturnum*)

Authors: Kent, M. L., Myers, M. S., Wellings, S. R., and Elston, R. A.

Source: Journal of Wildlife Diseases, 24(1) : 142-145

Published By: Wildlife Disease Association

URL: <https://doi.org/10.7589/0090-3558-24.1.142>

BioOne Complete (complete.BioOne.org) is a full-text database of 200 subscribed and open-access titles in the biological, ecological, and environmental sciences published by nonprofit societies, associations, museums, institutions, and presses.

Your use of this PDF, the BioOne Complete website, and all posted and associated content indicates your acceptance of BioOne's Terms of Use, available at www.bioone.org/terms-of-use.

Usage of BioOne Complete content is strictly limited to personal, educational, and non - commercial use. Commercial inquiries or rights and permissions requests should be directed to the individual publisher as copyright holder.

BioOne sees sustainable scholarly publishing as an inherently collaborative enterprise connecting authors, nonprofit publishers, academic institutions, research libraries, and research funders in the common goal of maximizing access to critical research.

An Internal X-Cell Pseudotumor in a Black Croaker (*Cheilotrema saturnum*)

M. L. Kent,¹ M. S. Myers,² S. R. Wellings,³ and R. A. Elston,¹ ¹ Battelle Marine Research Laboratory, 439 West Sequim Bay Road, Sequim, Washington 98382, USA; ² Environmental Conservation Division, Northwest and Alaska Fisheries Center, National Marine Fisheries Service, Seattle, Washington 98112, USA; ³ 1920 H. Roche Harbor Road, Friday Harbor, Washington 98250, USA

ABSTRACT: Cells closely resembling X-cells were the primary cellular component of a large pseudotumor in the viscera of a black croaker (*Cheilotrema saturnum*). The fish was captured in coastal waters off San Diego, California and was maintained at the Scripps Aquarium. After 2 years in captivity the fish exhibited extreme abdominal swelling due to a visceral mass, which weighed approximately one-fifth the total body weight. The cells associated with the pseudotumor were identified as X-cells due to their great variability in size, vesicular nuclei which stained negative for DNA and their formation of a pseudotumor. This is the first report of an X-cell pseudotumor in the visceral cavity. We agree with the hypothesis that the X-cell is a protozoan, and the description here of X-cells in a visceral pseudotumor in a fish of the family Sciaenidae associates an additional type of lesion with this enigmatic parasite.

Key words: X-cell, black croaker, *Cheilotrema saturnum*, visceral pseudotumor, case report.

A black croaker (*Cheilotrema saturnum*; family Sciaenidae) was captured in coastal waters off San Diego, California and maintained in captivity 2 yr at the Scripps Aquarium-Museum (Scripps Institution of Oceanography, La Jolla, California 92093, USA). Although it was otherwise healthy and actively swimming, the fish exhibited an extremely swollen abdomen for several months prior to necropsy. The fish was submitted for necropsy to the Office of Animal Resources (University of California-San Diego, La Jolla, California 92093, USA) on 27 April 1981.

Dissection of the fish revealed a lobulated, cream colored mass in the visceral cavity (Fig. 1). The visceral mass weighed 188 g in a fish with a weight of 885 g. Tissues were fixed in 10% buffered formalin, processed for histological examination using standard techniques and sections were stained with hematoxylin and

eosin, Feulgen's stain for DNA, or periodic acid-Schiff (Humason, 1979). Microscopically, the mass was composed of large aggregates of amorphous cells surrounded by a network of fibrous connective tissue (Figs. 2, 3). These cells exhibited remarkable morphological similarities to the unique cells, termed X-cells, found in papillomatous pseudotumors in the skin of several flatfish species (family Pleuronectidae) (Brooks et al., 1969; Harshbarger, 1984) and are henceforth referred to as X-cells. Small aggregates of the X-cells were dispersed also throughout the visceral fat. The X-cells at the periphery of the mass were intact, while those in the center appeared degenerative (Fig. 3). The intact cells had a pale eosinophilic cytoplasm, a large nucleus occupying the majority of the cell and a prominent eosinophilic nucleolus. The nucleus, including the nucleolus, stained negative for DNA with Feulgen's stain. Periodic acid-Schiff stain did not reveal a prominent glycocalyx-like coat on the cell membrane. The X-cells varied greatly in size, ranging in diameter from 5 to 15 μm . Multinucleated forms or cells undergoing mitosis were not detected. Histological examination of the gills, gut, kidney and liver did not reveal X-cells, and X-cell papillomatous lesions in the skin were not observed.

The presence of a large, vesicular nucleus with a prominent, eosinophilic nucleolus, great variability in size, association with a tumor-like mass and negative staining for nucleolar DNA indicate that the cell described here was closely related to X-cells described in other species (Wellings et al., 1976; Alpers et al., 1977; Dawe, 1981). Although Diamat and McVicar (1986) described internal X-cells in the dab

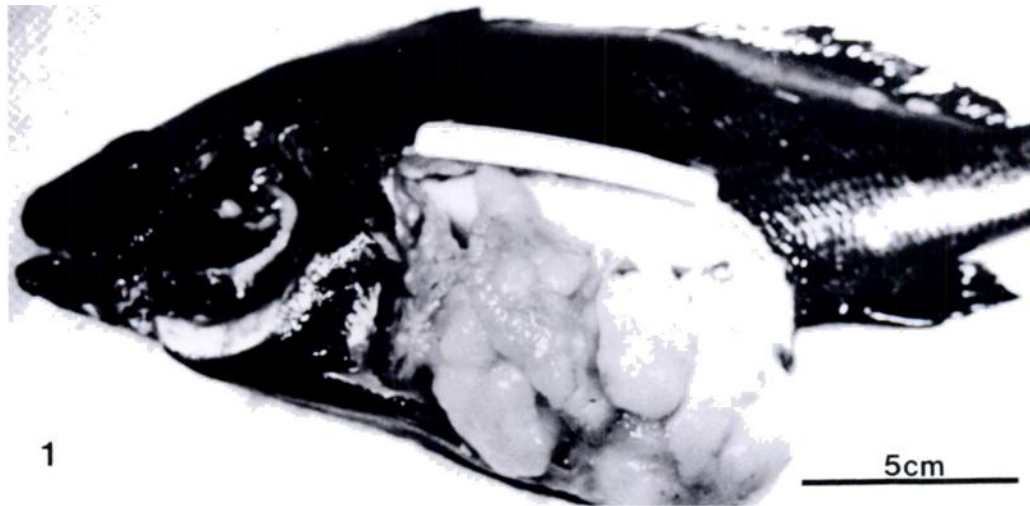


FIGURE 1. Black croaker with X-cell pseudotumor in visceral cavity.

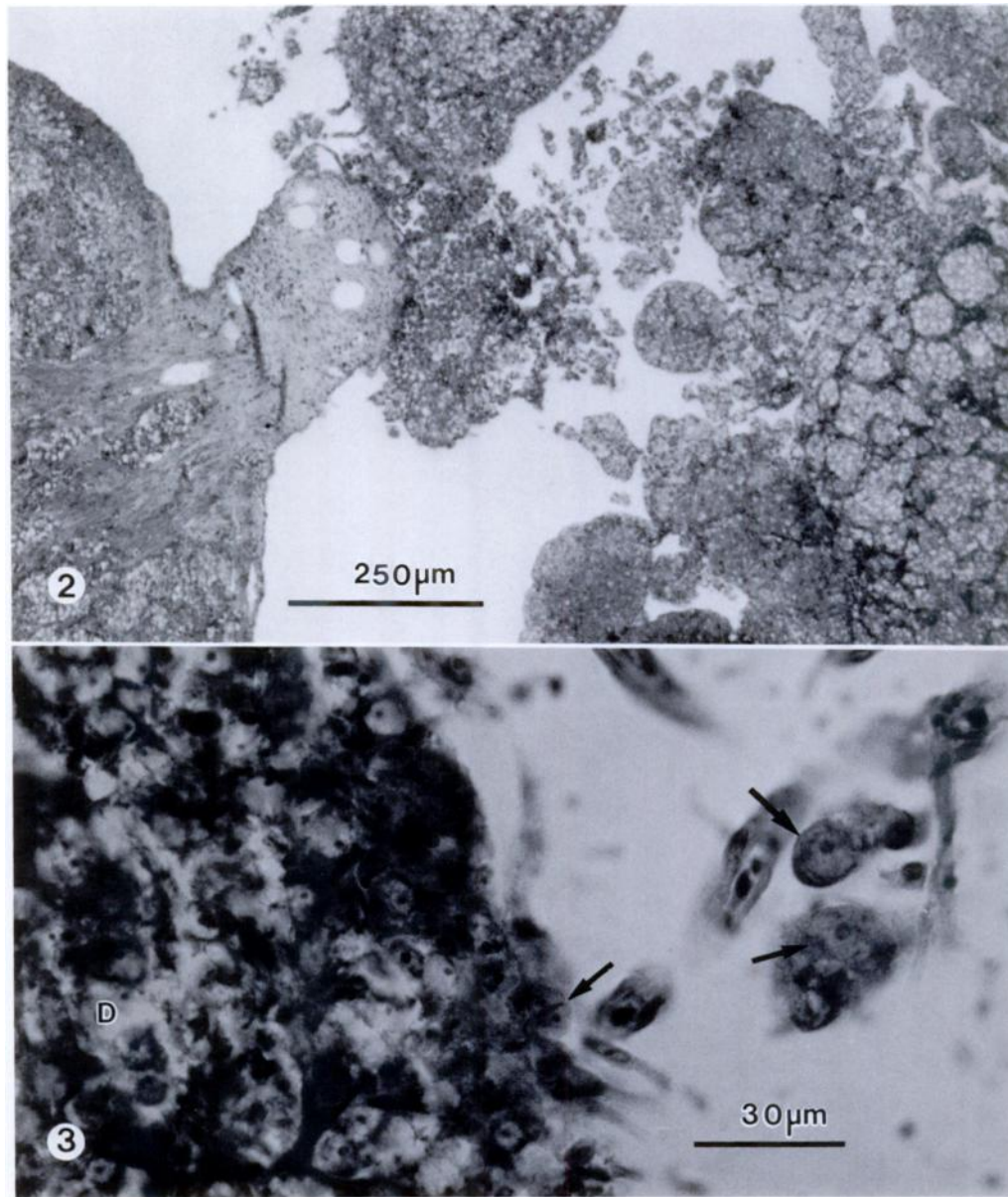
(*Limanda limanda*), this is the first report of X-cells associated with a visceral pseudotumor. The X-cells described here appear similar to those of the flatfishes' (family Pleuronectidae) skin pseudotumors in that they had a single nucleus, were mitotically inactive and degenerated in the center of the lesion (Peters et al., 1981). In contrast, some X-cells in cod (*Gadus macrocephalus*) pseudobranchs are mitotically active, form cysts and are often multinucleated (Alpers et al., 1977).

Theories on the origin of X-cells have been controversial since they were first identified as a common cell type in papillomatous skin lesions of flatfishes (Brooks et al., 1969). It has been suggested that they are neoplastic or virus transformed cells of host origin (Wellings and Chui-nard, 1964; McArn et al., 1968; Angell et al., 1975; Ito et al., 1976; Stich et al., 1977; Peters et al., 1978), but evidence presented by Dawe (1981) and Myers (1981) showed that they are most likely a parasitic protozoan. Dawe's (1981) description of X-cell nuclear division is suggestive of cryptomitosis, in which the nuclear membrane remains intact throughout mitosis, and this form of binary fission is unique to protozoa (Melhorn et al., 1986). Furthermore, X-cells

have approximately one-third the DNA content of normal diploid fish cells and at least six unique isozymes, which support the hypothesis that they are not of host origin (Dawe, 1981).

Concurrently, Myers (1981) presented further morphologic evidence from X-cell pseudotumors in Pacific Ocean perch (*Sebastes alutus*) supporting the interpretation that the X-cell is a parasite resembling amoebae of the *Hartmannella/Acanthamoeba* spp. group, possibly a vahlkampfid amoeba similar to the genus *Naegleria*, or an undescribed genus. This interpretation was based partially on the presence of unusual mitotic figures similar to those described by Dawe (1981). He also reported, for the first time, encysted or encapsulated forms of the X-cell which resembled amoebae cysts. In spite of these highly suggestive observations, no one has cultured the suspected protozoan or transmitted the X-cell disease.

Accepting that X-cells are protozoans, the description of X-cells in numerous families of fishes and various tissues indicates that either the X-cell protozoan is a cosmopolitan parasite with wide host specificity or X-cells represent several species. The description here of X-cells in a visceral



FIGURES 2, 3. X-cell pseudotumor from black croaker visceral cavity. 2. Aggregates of X-cells within a fibrous connective tissue stroma in large tissue masses. H&E. 3. Edge of pseudotumor; intact X-cells (arrows) are at the periphery and free from main tumor mass and degenerative X-cells (D) are found in the center of the pseudotumor. H&E.

pseudotumor in a fish of the family Sciaenidae associates an additional type of lesion with this enigmatic parasite and increases its host and geographical range.

The Battelle Marine Research Laboratory is part of the Pacific Northwest Lab-

oratory, which is operated for the U.S. Department of Energy by Battelle Memorial Institute under contract DE-AC06-76RLO 1830. This work was supported by the U.S. Department of Energy under Contract DE-AC06-76RLO 1830. Support was also pro-

vided by Battelle Memorial Institute, Columbus, Ohio and the Office of Animal Resources and the Scripps Aquarium-Museum, University of California, San Diego.

LITERATURE CITED

- ALPERS, C. E., B. B. MCCAIN, M. S. MYERS, S. R. WELLINGS, M. POORE, J. BAGSHAW, AND C. J. DAWE. 1977. Pathologic anatomy of pseudo-branch tumors in Pacific cod, *Gadus macrocephalus*. *Journal of the National Cancer Institute* 59: 377-398.
- ANGELL, C. L., B. S. MILLER, AND S. R. WELLINGS. 1975. Epizootiology of tumors in a population of juvenile English sole (*Parophrys vetulus*) from Puget Sound, Washington. *Journal of the Fisheries Research Board of Canada* 32: 1723-1732.
- BROOKS, R. E., G. E. MCARN, AND S. R. WELLINGS. 1969. Ultrastructural observations on an unidentified cell type found in epidermal tumors of flounders. *Journal of the National Cancer Institute* 43: 97-109.
- DAWE, C. J. 1981. Polyoma tumors in mice and X-cell tumors in fish. *In* Phyletic approaches to cancer, C. J. Dawe, J. C. Harshbarger, S. Kondo, T. Sugimura, and S. Takayama (eds.). Japanese Science Society Press, Tokyo, Japan, pp. 19-49.
- DIAMAT, A., AND A. H. MCVICAR. 1986. X-cell disease in common dab, *Limanda limanda* L. *Bulletin of the European Association of Fish Pathologists* 6: 112-114.
- HARSHBARGER, J. C. 1984. Pseudoneoplasms in ectothermic animals. *In* Use of small fish species in carcinogenicity testing, K. L. Hoover (ed.). National Cancer Institute Monograph 5, U.S. Government Printing Office, Washington, D.C., pp. 251-273.
- HUMASON, G. L. 1979. Animal tissue techniques. W. H. Freeman and Company, San Francisco, California, 661 pp.
- ITO, Y., I. KIMURA, AND T. MIYAKE. 1976. Histopathological and virological investigations of papillomas in soles and gobies in coastal waters of Japan. *Progress in Experimental Tumor Research* 20: 86-93.
- MCARN, G. E., R. G. CHUINARD, B. S. MILLER, R. E. BROOKS, AND S. R. WELLINGS. 1968. Pathology of skin tumors found in English sole and starry flounder from Puget Sound, Washington. *Journal of the National Cancer Institute* 41: 229-242.
- MELHORN, H., A-O. HEYDORN, AND E. SCHEIN. 1986. Developmental processes in parasitic protozoa. *In* Parasitology-quo vadit?, Proceedings of the Sixth International Congress of Parasitology, M. J. Howell (ed.). Australian Academy of Science, Canberra, Australia, pp. 259-267.
- MYERS, M. S. 1981. Pathological anatomy of papilloma-like tumors in the Pacific Ocean perch *Sebastes alutus* from the Gulf of Alaska. M.S. Thesis. University of Washington, Seattle, Washington, 98 pp.
- PETERS, N., G. PETERS, H. F. STICH, A. B. ACTON, AND G. BRESCHING. 1978. On differences in skin tumors of Pacific and Atlantic flatfish. *Journal of Fish Diseases* 1: 3-25.
- , H. F. STICH, AND H. KRANZ. 1981. The relationship between lymphocystis disease and X-cell papillomatosis in flatfish. *In* Phyletic approaches to cancer, C. J. Dawe, J. C. Harshbarger, S. Kondo, T. Sugimura, and S. Takayama (eds.). Japanese Science Society Press, Tokyo, Japan, pp. 111-121.
- STICH, H. F., A. B. ACTON, K. OISHI, F. YAMAZAKI, T. HARADA, T. HIBINO, AND H. G. MOSER. 1977. Systematic collaborative studies on neoplasms in marine animals as related to the environment. *Annals of the New York Academy of Sciences* 298: 374-388.
- WELLINGS, S. R., AND R. G. CHUINARD. 1964. Epidermal papillomas with virus-like particles in flathead sole, *Hippoglossoides elassodon*. *Science* 146: 932-933.
- , B. B. MCCAIN, AND B. S. MILLER. 1976. Epidermal papillomas in Pleuronectidae of Puget Sound, Washington. *Progress in Experimental Tumor Research* 20: 55-74.

Received for publication 5 May 1987.