

TRICHOMONIASIS IN FREE-LIVING GOSHAWKS (ACCIPITER GENTILIS GENTILIS) FROM GREAT BRITAIN

Authors: Cooper, J. E., and Petty, S. J.

Source: Journal of Wildlife Diseases, 24(1) : 80-87

Published By: Wildlife Disease Association

URL: <https://doi.org/10.7589/0090-3558-24.1.80>

The BioOne Digital Library (<https://bioone.org/>) provides worldwide distribution for more than 580 journals and eBooks from BioOne's community of over 150 nonprofit societies, research institutions, and university presses in the biological, ecological, and environmental sciences. The BioOne Digital Library encompasses the flagship aggregation BioOne Complete (<https://bioone.org/subscribe>), the BioOne Complete Archive (<https://bioone.org/archive>), and the BioOne eBooks program offerings ESA eBook Collection (<https://bioone.org/esa-ebooks>) and CSIRO Publishing BioSelect Collection (<https://bioone.org/csiro-ebooks>).

Your use of this PDF, the BioOne Digital Library, and all posted and associated content indicates your acceptance of BioOne's Terms of Use, available at www.bioone.org/terms-of-use.

Usage of BioOne Digital Library content is strictly limited to personal, educational, and non-commercial use. Commercial inquiries or rights and permissions requests should be directed to the individual publisher as copyright holder.

BioOne is an innovative nonprofit that sees sustainable scholarly publishing as an inherently collaborative enterprise connecting authors, nonprofit publishers, academic institutions, research libraries, and research funders in the common goal of maximizing access to critical research.

TRICHOMONIASIS IN FREE-LIVING GOSHAWKS (*ACCIPITER GENTILIS GENTILIS*) FROM GREAT BRITAIN

J. E. Cooper¹ and S. J. Petty²

¹ Royal College of Surgeons of England, Lincoln's Inn Fields, London WC2A 3PN, England

² Forestry Commission, Wildlife and Conservation Research Branch,
Ardentinn, Dunoon, Argyll PA23 8TS, Scotland

ABSTRACT: The goshawk *Accipiter gentilis* has recently been reintroduced into parts of Great Britain. During the course of a study of one population, lesions of stomatitis were observed in 14 young from five broods and all the affected birds died. Postmortem examination of three birds revealed live *Trichomonas gallinae* in exudate from one, and histological findings consistent with a diagnosis of trichomoniasis were made in this and one other bird. It is suggested that trichomoniasis may be a significant mortality factor in goshawks from Britain.

Key words: Goshawk, *Accipiter gentilis*, trichomoniasis, *Trichomonas gallinae*, reproduction, Great Britain.

INTRODUCTION

The goshawk *Accipiter gentilis* stopped breeding in Great Britain before the end of the last century. Bannerman and Lodge (1956) believed that goshawks last nested at Rohallion in Perthshire, Scotland in 1883. Even in the century prior to this the goshawk was scarce, suggesting that the species' demise was associated with the extensive deforestation that left much of Britain without tree cover by the early 19th century (Godwin, 1975). Subsequently, the few birds that remained in some of the larger forest remnants were easily exterminated by Victorian bird and egg collectors and/or gamekeepers.

Releases by falconers since the mid-1960's resulted in the successful reintroduction of goshawks in many parts of Britain (Marquiss and Newton, 1982). Goshawks have successfully re-established in some of Britain's largest forests, which have been created during the last 50 yr. Here, these birds are sheltered from pressures such as those that resulted in their decline during the last century and which are still preventing them from expanding their range to include many of the richer, but lightly wooded areas in the lowlands (Marquiss and Newton, 1982).

Trichomoniasis is caused by a flagellate protozoan parasite, *Trichomonas gallinae*, of the upper digestive system in birds, par-

ticularly the Columbiformes (Stabler, 1954). Stabler (1969) considered that most wild and almost all domestic pigeons are infected with *T. gallinae*. There are different strains of *T. gallinae*; some cause no clinical signs and may provide immunity against a highly pathogenic strain. However, in a non-immune bird this parasite can cause severe lesions, usually a stomatitis that may obstruct the buccal cavity and pharynx. In some cases, more extensive lesions are found elsewhere in the body. Death usually results from starvation, secondary bacterial infection or, possibly, toxemia.

There are surprisingly few records of trichomoniasis in free-living raptors. Incidental reports from North America include bald eagles (*Haliaeetus leucocephalus*) (Stone and Nye, 1981), a brood of two grey hawks (*Buteo nitidus*) (Stensrude, 1965), and four of 10 fledgling golden eagles (*Aquila chrysaetos*) (Beecham and Kochert, 1975). There are no published records of trichomoniasis in accipiters from Great Britain, and Ratcliffe (1980) did not report it from wild peregrine falcons (*Falco peregrinus*) in Britain, where their main prey were domestic pigeons (*Columba livia*).

In this paper we report the diagnosis of trichomoniasis in free-living goshawks from Britain and quantify the effect of this

disease on reproductive output. We then discuss how this might affect the growth of an expanding population.

MATERIALS AND METHODS

Study area

The study was undertaken in an upland location in Britain, where extensive areas of forests were interspersed with open moorland and both arable and improved grassland. Because goshawks are rare in Great Britain, the exact location of the study area is not disclosed. The forests were man-made and were composed of exotic conifers, mostly Sitka spruce *Picea sitchensis* and Norway spruce *Picea abies*, grown on short rotations of 45–55 yr. Planting commenced in the 1930's, peaked in the 1950's and 1960's and diminished thereafter. Clear-cutting and the establishment of second generation forests commenced in 1968, thereby breaking up the even-aged structure of the older blocks of forest.

History and origin of the goshawk population

Goshawks were introduced into the study area in the late 1960's or early 1970's. The number and origin of these pioneers were not known. Measurements of primary feathers from molting females corresponded closely to those given by Marquiss (1981) for Finnish birds, many of which were imported into Britain. Breeding was first recorded in 1972, and until 1976 all known nesting attempts failed to produce young. Breeding was first successful in 1977, and from 1979 the number of breeding pairs increased annually to 20 in 1985. The close relationship between successful breeding and the population increase, and the known distribution of goshawks in Britain, suggest that this population is at present self contained.

Field methods

Goshawks have large over-lapping home ranges and within their home range a pair will have one or more nesting areas (Cramp and Simmons, 1980). Nesting areas were located by systematically searching suitable stands and areas where goshawks had been seen repeatedly. A home range was counted as occupied by a pair once an existing nest had been refurbished or a new one built. Once an occupied nest was found, visits were made to count clutch size, brood size at hatching and fledging and the number of young leaving a nesting area. On each visit, chicks were measured, the buccal cavity and pharynx checked for lesions or swelling and other abnormalities recorded. Chicks were banded before they fledged.

Goshawk prey were identified from food re-

TABLE 1. Productivity data from 46 goshawk nests in the study area from 1973 to 1985.

Parameter	Total	Mean (SD) (n = 46)	% of maxi- mum produc- tion
Eggs laid	173	3.76 (0.79)	100
Unhatched eggs	39	0.85	23
Chicks hatching	134	2.91 (1.50)	78
Chicks dying in nest	30	0.65	17
Chicks fledging	104	2.26 (1.36)	60
Juveniles dying after fledging	9	0.20	5
Juveniles leaving nesting area	95	2.06 (1.41)	55

mains found in occupied nesting areas or by locating kills in the forest. For avian prey, the sternum was used to count and identify prey items and for mammals the skull was used. We used a reference collection of sterna and skulls (S. J. Petty, pers. collection).

Postmortem and clinical methods

Three dead birds were examined; particular attention was paid to external examination, especially of the buccal cavity and pharynx, where swabs were taken. Whole body radiography was done on two birds. Subsequent postmortem investigation involved the gross examination of internal organs and the selection of tissues for histopathology and parasitology as outlined by Cooper (1978, 1987). Organ samples were fixed in buffered formol-saline, embedded in paraffin wax, cut in 6- μ m sections and then stained with either hematoxylin and eosin, Gram stain, periodic acid-Schiff (PAS) or Giemsa. Parasitological examination of the gastrointestinal tract, including the buccal cavity, was of wet preparations in warm saline. Tissues were frozen for subsequent toxicological investigation.

One live goshawk was examined clinically on arrival in the laboratory. Blood samples were collected from the basilic vein and placed in EDTA for hematological investigations. Blood smears were fixed with 90% methanol and stained with Giemsa. The bird was observed daily and its weight, food intake and behavior were monitored.

RESULTS

Goshawk productivity

In 76 breeding attempts from 1972 to 1985, the complete histories of 46 nests were known (Table 1). Potential repro-

TABLE 2. Time of death for goshawk chicks dying from stomatitis and other natural causes.

Age of chicks	Number of chicks dying (%) from:	
	Stomatitis	Other natural causes
0-17 days (early nestling stage)	0 (0)	16 (73)
18-35 days (late nestling stage)	12 (86)	2 (9)
35-50 days (postfledging)	2 (14)	4 (18)*
Total	14 (100)	22 (100)

* Excludes one brood of three chicks, which was shot soon after fledging.

ductive output was reduced through a variety of losses. These were greatest during incubation, less during the nestling stage and least in the postfledging period. These combined losses resulted in 55% of the 173 eggs producing independent juveniles.

Incidence of trichomoniasis

Lesions of stomatitis were recorded in 14 chicks from five broods in the years 1981, 1983, and 1985. Once present, the lesions developed until they completely blocked the pharynx and prevented the chicks from feeding, resulting in a slow loss of weight and death, usually among an abundance of uneaten food. Characteristic flecks of dried food accumulated on the feathers around the beak, as the chicks repeatedly shook food from side to side, in an attempt to swallow it. All 14 chicks that developed these clinical signs eventually died, but at a later stage than chicks dying from other causes (Table 2). When death occurred before fledging (Table 2), plucked remains and bands were found in the nest, suggesting that the dead nestling had been eaten by the adults, their siblings, or both. In two broods, clinical signs first occurred in one "runt" chick. After their remains were found in the nest, stomatitis developed in the remaining chicks. In three further broods, where chicks with stomatitis and lesions were removed before they were eaten, the other

chicks remained unaffected. Death associated with stomatitis was responsible for 39% of the mortality between hatching and independence.

Postmortem and clinical findings

Bird 1 was a male from a brood of three in 1981. It was in good body condition but the head was swollen with a dark raised mass in the buccal cavity. The bird showed signs of postmortem decomposition and there were dipterous larvae, later identified as first instar *Lucilia* sp., around the orifices of the head. Internal organs appeared normal macroscopically but interpretation was marred by freezing. Wet preparations did not reveal any protozoan or helminth parasites. Histological examination of the buccal lesion showed it consisted of cellular debris and blood clots. Bacteria were visible on the surface. Stains failed to demonstrate either protozoan or metazoan parasites. Other tissues showed no significant lesions.

Bird 2 was a male from a brood of four in 1985. It was in moderate body condition. The left mandible was swollen (Fig. 1) and caseous material was visible within the buccal cavity (Fig. 2). The internal organs showed no gross lesions. The stomach was empty and it and the small intestine were bile-stained. Wet preparations from the buccal lesion showed small numbers of mobile flagellate organisms which, on the basis of their size and morphology, were identified as *Trichomonas gallinae*. Intestinal parasites were not detected. Histological examination of the buccal lesions showed cellular debris similar to that seen in Bird 1 but preservation was better and, with Giemsa stain, occasional organisms were visible which appeared to be trichomonads. The lung showed a moderate granulocytic infiltrate of the interstitium and an excess of granulocytes in the lumina of blood vessels. There were scattered foci of inflammatory cells, mainly granulocytes, in the liver and kidney. Wholebody radiography of the carcass revealed no skeletal lesions.




FIGURE 1. Male goshawk showing swelling of the left mandibular region, associated with trichomoniasis.

Bird 3 was a female from a brood of four in 1985. It was in moderate body condition but the right side of the bird's head was swollen, especially around the temporo-mandibular joint and caseous material was visible in the buccal cavity. Internal organs showed no gross abnormalities. Wet preparations from the buccal cavity and intestine did not reveal any parasites. Histological examination of the buccal lesions showed changes similar to those in Bird 2. Other tissues were congested. The lung showed a minimal degree of edema and the sinusoids of the liver were dilated and edematous. There was a slight excess of granulocytes in the spleen. Whole body radiography of the carcass revealed no skeletal lesions.

A live male goshawk, from the same brood as Bird 3, appeared active and in good general condition. The bird showed no clear evidence of stomatitis other than a possible excess of saliva in the buccal cavity. Wet preparations of the latter failed to reveal any parasites, but a course of oral

metronidazole (Flagyl, May and Baker Ltd., Dagenham, Essex RM10 7XS, England) (100 mg/day) was started and continued for 10 days. Over the next week the bird's weight dropped from 717 g to 460 g and a hematocrit (PCV) estimation showed a value of 27–28%. The bird was given an oral vitamin/mineral supplement (SA 37, Intervet Laboratories Ltd., Science Park, Milton Road, Cambridge CB4 4BT, England) and supplementary feeding was introduced. Seven days later (14 days after arrival) the bird's weight was 730 g, the PCV was 42% and the serum protein was 3 g/dl. Fecal cultures showed only *Escherichia coli* and *Proteus* sp. and there was no evidence of parasites. The goshawk was successfully fostered into a similar sized brood.

Pigeons as goshawk prey

Pigeons were an important part of the goshawks' diet. Of 1,389 prey items that were identified between 1977 and 1983, 466 (34%) were feral pigeons and 320 (23%)

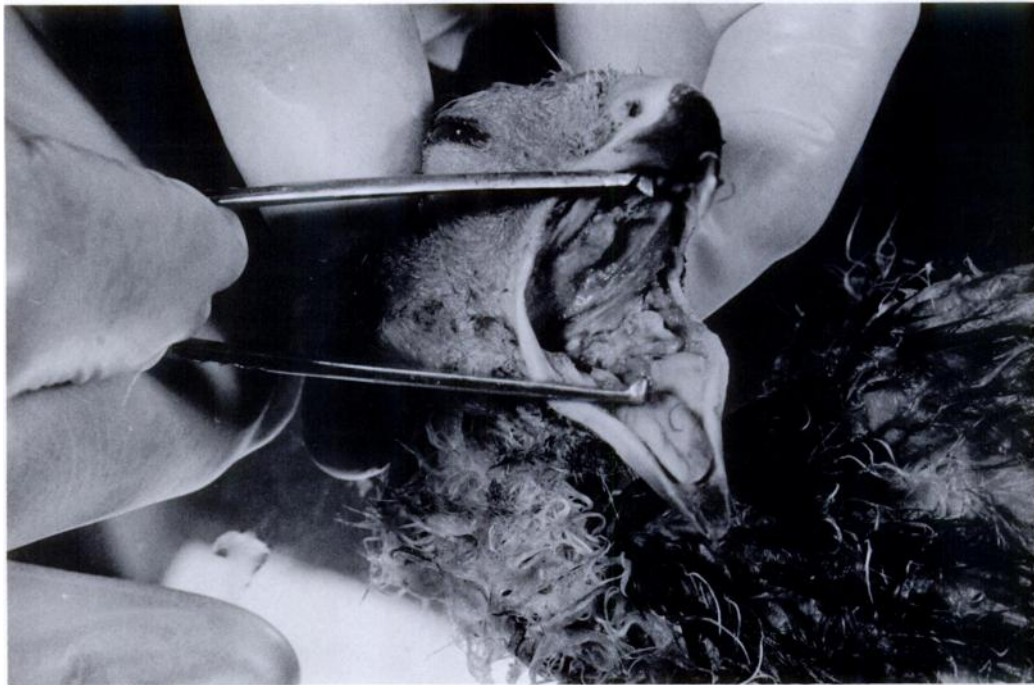


FIGURE 2. Male goshawk with beak opened. Note the caseous debris caused by *Trichomonas gallinae* infection.

were woodpigeons (*Columba palumbus*). There was little annual variation in the percentage of pigeons taken, ranging from 51% in 1983 to 67% in 1979 (annual mean ± 1 SD = 57.6 ± 6.0). Prey samples were not evenly distributed throughout the year but they were heavily biased towards the spring and summer. However, they were collected in a consistent manner each year and these percentages do provide an index of annual variation in pigeon prey. There were seasonal variations also in the number of pigeons taken, the highest percentage being in June and July (Table 3). This coincided with the period when large goshawk chicks were present in nests. Fledging of young spanned the period 19 June to 18 July.

DISCUSSION

This is the first published report of trichomoniasis in free-living raptors in Britain. The absence of any previous reports in goshawks is not surprising since

this bird has only recently been reintroduced and become the subject of research (Marquiss and Newton, 1982). The apparent absence of records of trichomoniasis in free-living raptors from Britain may not reflect the actual incidence of the condition, for two reasons. First, most people involved in field studies on birds of prey in Britain are concerned with population dynamics, rather than disease, and it is possible that mouth lesions in birds may have been missed. Secondly, as this study has shown, the demonstration of *Trichomonas gallinae* is not easy, especially in postmortem material. Therefore, specific diagnoses may have proved impossible. Nevertheless, if the disease were at all prevalent some records of stomatitis would have been expected even if the etiology was obscure; particularly as in this study, death occurred among well grown nestlings and juveniles, in contrast to other causes of mortality which were mainly in younger chicks (Table 2).

In only one bird in the present study were trichomonads demonstrated. Failure to observe living organisms does not, however, preclude a diagnosis of trichomoniasis. The causal organisms die rapidly and often cannot be detected if a bird has been dead for more than a few hours. In postmortem cases histological examination can play a part in making, or confirming, a diagnosis. The oral lesions in Birds 2 and 3 resembled those described by Mesa et al. (1961) and organisms, believed to be trichomonads, were observed also. Nevertheless, distinguishing these protozoa in histological sections is difficult and should not be relied upon when making a diagnosis. Trichomoniasis was not confirmed in the live goshawk examined; however, its history suggested that it might be infected and there appeared to be a clinical response to oral metronidazole.

The source of *T. gallinae* in the goshawks in this study was probably feral pigeons, although we cannot exclude the possibility that woodpigeons were infected also. According to Stabler (1969) *T. gallinae* is present in an asymptomatic form in approximately 75% of "wild common pigeons" and some of these may harbor virulent strains which can infect their own young or predators which devour them. It is unclear why the goshawks in this study appear to have been affected particularly by trichomoniasis. Peregrines also capture and eat substantial numbers of pigeons and yet no reports have been located of the disease in this species. It is possible that a particularly virulent strain of the organism may be present in the area in which the goshawks have succumbed, or that these birds were particularly susceptible. Weak or debilitated captive birds are particularly liable to show clinical signs of disease (Emanuelson, 1983). In two broods, stomatitis was first detected in 'runt' chicks. Their remains were found later in the nest, suggesting that the female had eaten them or fed them to the remaining chicks, thereby passing on the disease. Removing infected chicks prior to death may prevent

TABLE 3. Seasonal variation in the number (%) of pigeons taken as goshawk prey, 1975–1983.

Prey category	November– March	April	May	June	July	August	September– October	Total
Feral pigeon (<i>Columba livia</i>)	6 (12)	30 (32)	45 (39)	80 (43)	265 (35)	32 (20)	8 (26)	466 (34)
Woodpigeon (<i>Columba palumbus</i>)	3 (6)	4 (4)	12 (10)	23 (12)	218 (29)	54 (33)	6 (19)	320 (23)
Other prey	43 (83)	59 (64)	58 (50)	83 (45)	267 (36)	76 (47)	17 (55)	603 (43)
Total prey items	52 (100)	93 (100)	115 (100)	186 (100)	750 (100)	162 (100)	31 (100)	1,389 (100)

the loss of the rest of the brood. So far, only young hawks have been found infected with trichomoniasis. Sick or dead adult birds are less likely to be located than are nestlings and therefore one can only speculate as to whether some adult hawks also are affected clinically. It is possible that the latter are harboring the organism, in which case the young may be infected from their parents rather than by ingesting organisms from pigeons. A survey of infections in adult goshawks and prey species in the study area is planned.

In this study, stomatitis was the single most important cause of chick mortality. It occurred later than other causes of natural deaths (Table 2), at an age when most chicks could be expected to leave the nesting area successfully. If those chicks that died of the disease had survived, then 109 rather than 95 juvenile hawks would have reached independence, a 15% increase over the present number. Although this did not prevent the expansion of the goshawk population, it may have slowed it.

There could be a genetic explanation for the susceptibility of this population of goshawks to the disease. The entire population may be derived from the one pair of birds, which first successfully bred in 1977. This limited gene pool may in some way predispose the birds to trichomoniasis; an increased susceptibility to disease has been reported in other small (presumably inbred) populations of birds (Cooper et al., 1981). Biometrics suggest that the goshawks originated from Finland, where they are dependent on tetraonid populations for food and they rarely take pigeons (Huhtala and Sulkava, 1981; Wikman and Linden, 1981). Therefore, there may have been no selection for birds with a degree of resistance to trichomoniasis as might have been the case in other goshawk populations which eat pigeons in quantity, and in other pigeon-eating raptors such as peregrines.

Stabler (1969) wrote of *T. gallinae*; "It is the writer's opinion that this parasite has not in the past, nor will in the future, have any appreciable effect on the survival,

either generally or locally, of any of the pigeon and dove-eating populations of feral hawks." Our results suggest that *T. gallinae* may locally affect the reproductive potential of goshawks and that it might be one factor affecting the population dynamics of this species. This would support the view of Newton (1979) who, while expressing doubt over the role of disease in the control of raptor populations, stressed the need for more research on this topic.

ACKNOWLEDGMENTS

We are indebted to staff at the Royal College of Surgeons who participated in the care of the sick bird and in the examination of postmortem material, particularly veterinary students Michèle Miskimins, Wendy Wilkens and Andrew Cunningham. We thank Ian Newton for his valuable comments on an earlier draft of this paper. Numerous Forestry Commission rangers, particularly David Anderson, and foresters helped with the field study and the Nature Conservancy Council kindly supplied the licences that were required.

LITERATURE CITED

- BANNERMAN, D. A., AND G. E. LODGE. 1956. The birds of the British Isles, Vol. 5. Oliver and Boyd, Edinburgh, Scotland, pp. 230-243.
- BEECHAM, J. J., AND M. N. KOCHERT. 1975. Breeding biology of the golden eagle in southwestern Idaho. *Wilson Bulletin* 87: 506-513.
- COOPER, J. E. 1978. Veterinary aspects of captive birds of prey. Standfast Press, Saul, England, pp. 28-37.
- . 1987. Pathology. In *Raptor management techniques manual*, B. A. Millsap, K. W. Cline, D. M. Bird, and B. G. Pendleton (eds.). National Wildlife Federation, Washington, D.C., pp. 331-347.
- , C. G. JONES, AND A. W. OWADALLY. 1981. Morbidity and mortality in the Mauritius kestrel (*Falco punctatus*). In *Recent advances in the study of raptor diseases*, J. E. Cooper and A. G. Greenwood (eds.). Chiron Publications, Keighley, England, pp. 31-38.
- CRAMP, S., AND K. E. L. SIMMONS (editors). 1980. The birds of the western Palearctic, Vol. II. Oxford University Press, Oxford, England, pp. 148-157.
- EMANUELSON, S. 1983. Avian trichomoniasis. In *Current veterinary therapy*, Vol. VIII, Small animal practice, R. W. Kirk (ed.). W. B. Saunders, Philadelphia, Pennsylvania, pp. 619-621.
- GODWIN, H. 1975. The history of the British flora.

- Cambridge University Press, Cambridge, England, 541 pp.
- HUHTALA, K., AND S. SULKAVA. 1981. Environmental influences on goshawk breeding in Finland. *In* Understanding the goshawk, R. E. Kenward and M. Lindsay (eds.). International Association for Falconry, London, England, pp. 89–103.
- MARQUISS, M. 1981. The goshawk in Britain—Its provenance and current status. *In* Understanding the goshawk, R. E. Kenward and M. Lindsay (eds.). International Association for Falconry, London, England, pp. 43–55.
- , AND I. NEWTON. 1982. The goshawk in Britain. *British Birds* 75: 243–260.
- MESA, C. P., R. M. STABLER, AND M. BERTHRONG. 1961. Histopathological changes in the domestic pigeon infected with *Trichomonas gallinae* (Jones' Barn Strain). *Avian Diseases* 5: 48–60.
- NEWTON, I. 1979. Population ecology of raptors. Poyser, Berkhamsted, England, 399 pp.
- RATCLIFFE, D. A. 1980. The peregrine falcon. Poyser, Berkhamsted, England, 416 pp.
- STABLER, R. M. 1954. *Trichomonas gallinae*: A review. *Experimental Parasitology* 3: 358–402.
- . 1969. *Trichomonas gallinae* as a factor in the decline of the peregrine falcon. *In* Peregrine falcon populations: Their biology and decline, J. J. Hickey (ed.). University of Wisconsin Press, Madison, Wisconsin, pp. 435–437.
- STENSRUDE, C. 1965. Observations on a pair of grey hawks in southern Arizona. *Condor* 67: 319–321.
- STONE, W. B., AND P. E. NYE. 1981. Trichomoniasis in bald eagles. *Wilson Bulletin* 93: 109.
- WIKMAN, M., AND H. LINDEN. 1981. Influences of food supply on population size. *In* Understanding the goshawk, R. E. Kenward and M. Lindsay (eds.). International Association for Falconry, London, England, pp. 105–113.

Received for publication 1 December 1986.