

PREVALENCE, ULTRASTRUCTURE OF THE CYST WALL AND INFECTIVITY FOR THE DOG AND CAT OF SARCOCYSTIS SP. FROM FALLOW DEER (CERVUS DAMA)

Authors: Poli, A., Mancianti, F., Marconcini, A., Nigro, M., and Colagreco, R.

Source: Journal of Wildlife Diseases, 24(1) : 97-104

Published By: Wildlife Disease Association

URL: <https://doi.org/10.7589/0090-3558-24.1.97>

BioOne Complete (complete.BioOne.org) is a full-text database of 200 subscribed and open-access titles in the biological, ecological, and environmental sciences published by nonprofit societies, associations, museums, institutions, and presses.

Your use of this PDF, the BioOne Complete website, and all posted and associated content indicates your acceptance of BioOne's Terms of Use, available at www.bioone.org/terms-of-use.

Usage of BioOne Complete content is strictly limited to personal, educational, and non - commercial use. Commercial inquiries or rights and permissions requests should be directed to the individual publisher as copyright holder.

BioOne sees sustainable scholarly publishing as an inherently collaborative enterprise connecting authors, nonprofit publishers, academic institutions, research libraries, and research funders in the common goal of maximizing access to critical research.

PREVALENCE, ULTRASTRUCTURE OF THE CYST WALL AND INFECTIVITY FOR THE DOG AND CAT OF *SARCOCYSTIS* SP. FROM FALLOW DEER (*CERVUS DAMA*)

A. Poli,¹ F. Mancianti,¹ A. Marconcini,¹ M. Nigro,² and R. Colagreco¹

¹ Dipartimento di Patologia Animale, Scuola di Medicina Veterinaria, Università di Pisa, 56100 Pisa, Italy

² Istituto di Zoologia e Anatomia Comparata, Università di Pisa, 56100 Pisa, Italy

ABSTRACT: The prevalence of *Sarcocystis* sp. (Protozoa: Sarcocystidae) in fallow deer (*Cervus dama*) in Tuscany, Italy was determined by digestion technique and histological examination. Forty-four of 45 fallow deer were infected. Infections occurred in adult deer and in fawns. Samples from the heart were more intensively parasitized than samples from tongue, oesophagus and diaphragm muscle. With transmission electron microscopy, the primary cyst wall was folded and formed narrow, overlapping, sinuous projections which were often parallel to the cyst surface. Dogs fed heart samples from infected fallow deer shed sporocysts after 10–11 days. Cats fed the same samples did not shed any sporocysts.

Key words: *Sarcocystis* sp., fallow deer, *Cervus dama*, prevalence, ultrastructure, infectivity, dog, cat, experimental infection.

INTRODUCTION

Recent studies have demonstrated the pathogenicity of *Sarcocystis* spp. in domestic (Johnson et al., 1975; Leek et al., 1977) and wild intermediate hosts (Hudkins and Kistner, 1977; Koller et al., 1977; Martinez-Gomez et al., 1985). These observations stimulated intensive studies on *Sarcocystis* spp. in the Cervidae. Several species of *Sarcocystis*, differentiated on the basis of cyst morphology by electron microscopy, were identified in moose (*Alces alces*) (Colwell and Mahrt, 1981), roe deer (*Cervus capreolus*) (Entzeroth, 1982), white-tailed deer (*Odocoileus virginianus*) (Entzeroth et al., 1982; Dubey and Lozier, 1983), mule deer (*Odocoileus hemionus*) (Dubey and Speer, 1985, 1986; Speer and Dubey, 1986), reindeer (*Rangifer tarandus tarandus*) (Gjerde, 1985a, b, c, d, e, f), American elk (*Cervus canadensis*) (Speer and Dubey, 1982) and red deer (*Cervus elaphus*) (Hernandez-Rodriguez et al., 1981a; Entzeroth et al., 1983). At present, the only morphological studies on *Sarcocystis* spp. from fallow deer (*Cervus dama*) are on three specimens in West Germany (Entzeroth et al., 1985) and on three specimens in Tuscany, Italy (Poli et al., 1986).

The purpose of the present study was to report the prevalence and intensity of *Sarcocystis* sp. in fallow deer in Tuscany, to conduct a detailed ultrastructural investigation on the cyst wall of this species and to determine the role of the dog and cat in the life-cycle of this parasite.

MATERIALS AND METHODS

From January to May 1986 samples of tongue, oesophagus, diaphragm muscle and heart from 45 fallow deer, 31 fawns (0.5–1.0 yr old) and 14 adults, were collected from S. Rossore, Migliarino Natural Park (Pisa, Italy, lat. 43°48'N, long. 10°20'E).

All samples were processed by pepsin digestion technique; representative specimens were fixed in buffered 10% formalin (pH 7.4) and embedded in paraffin. Five- μ m sections were stained by haematoxylin and eosin and periodic acid Schiff (PAS) stain. One-mm³ pieces of heart and tongue from 10 of the 45 fallow deer were fixed in Karnovsky's fixative, rinsed overnight in 0.1 M phosphate buffer at pH 7.3 and post-fixed in 1% osmium tetroxide in the same buffer for 2 hr. Following fixation, fragments were dehydrated in a graded series of ethanol, placed in propylene oxide and embedded in an Epon-araldite mixture. One- μ m-thick and ultrathin sections were cut using a LKB Ultratome III (Bromma, Sweden) by glass or diamond knives. Thick sections were stained with toluidine blue. Ultrathin sections were stained with uranyl acetate and lead citrate and examined with an El-

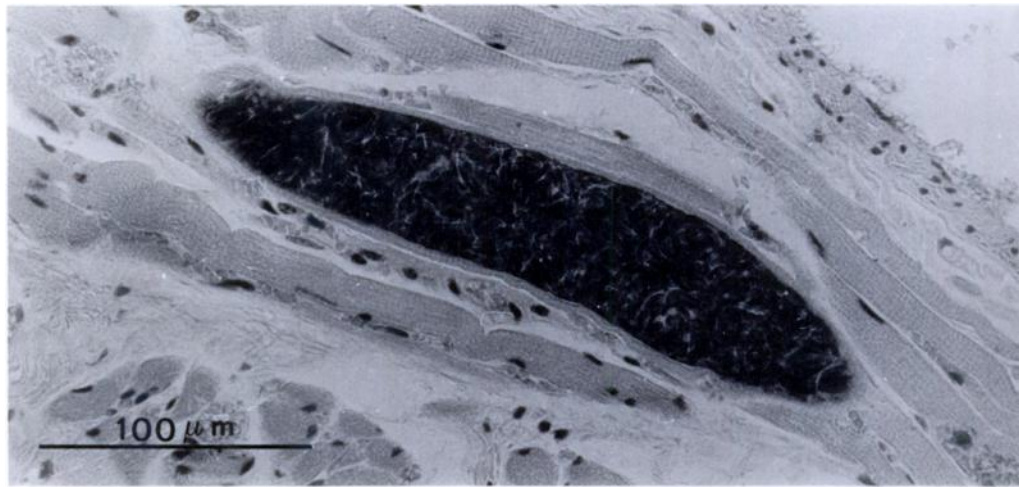


FIGURE 1. Thin-walled *Sarcocystis* sp. in section of tongue muscle of a fallow deer. H&E.

miskop 101 (Siemens, Berlin, Federal Republic of Germany) electron microscope.

In order to determine whether or not dogs or cats could serve as final hosts of this *Sarcocystis* sp., samples of heart from infected fallow deer were used to feed these potential definitive hosts. Seven dogs and four cats were raised on canned milk (Parmalat, Parma, Italy) and canned dog (Laika, International Food, Rivolta d'Adda, Italy) and cat (Wiskas Effen Inc. and Cia, Madrid, Spain) food until 4 wk old. Thereafter, they were fed dry food (Loyal soupe, Unisabi s.a., Chapelle Vendomoise, France). These animals were not fed raw meat until the experiment began. Feces were examined for several days before the beginning of the experiment and all dogs and cats were found free from *Sarcocystis* spp. infection. Dogs were 4–5 wk old and cats were 5–6 wk old at the beginning of the experiment. Five dogs and two cats, housed individually, were each fed 250 g of heart from naturally-infected fallow deer. Two dogs and two cats were used as controls. Feces were collected and examined daily for sporocysts of *Sarcocystis* spp. after flotation. Dogs were killed at 30, 40, 45, 50 and 60 days postinfection and cats at 30 and 40 days. Control dogs and cats were sacrificed at 30 days after the beginning of the experiment. Intestinal mucosa and submucosa were scraped from the muscularis externa with a glass slide and the sporocysts were collected and stored in a balanced salt solution at 4 C as described by Dubey (1980).

Representative specimens of *Sarcocystis* sp. from this study are deposited in the U.S. National Parasite Collection (Animal Parasitology Institute, U.S.D.A., Building 1180 BARC-East,

Beltsville, Maryland 20705, USA; Accession Number 79926).

RESULTS

Using pepsin digestion, *Sarcocystis* sp. was diagnosed in 30 of 31 fawn (97%) and 14 of 14 adult (100%) fallow deer examined (overall prevalence was 98%). Banana shaped bradyzoites measured 13.2–21 μm (\bar{x} = 15.1 μm , SD = 2.42 μm , n = 30) in length and 3.3–5.5 μm (\bar{x} = 3.5 μm , SD = 0.6 μm , n = 30) in width. Metrocytes measured 11 μm (SD = 0.1 μm) by 3.3 μm (SD = 0, n = 20).

By light microscopy, 38 of 45 fallow deer, 24 of 31 fawns (77%) and 14 of 14 adults (100%), showed the presence of thin-walled muscle cysts of *Sarcocystis* sp. (Fig. 1). Intensity of *Sarcocystis* sp. in fawns was significantly lower than in adult deer. The mean number of cysts observed per cm^2 of section of tongue muscle was 4.3 (SD = 3.6) in fawns and 14.2 (SD = 10.8) in adults. The mean number of cysts observed per cm^2 of section of heart muscle was 10.1 (SD = 7.1) in fawns and 95.6 (SD = 49.2) in adults. Longitudinally cut sarcocystis measured 88–220 μm (n = 30) in heart and 210–360 μm (n = 30) in the tongue.

All the cysts examined ultrastructurally were intracellular and showed a unique

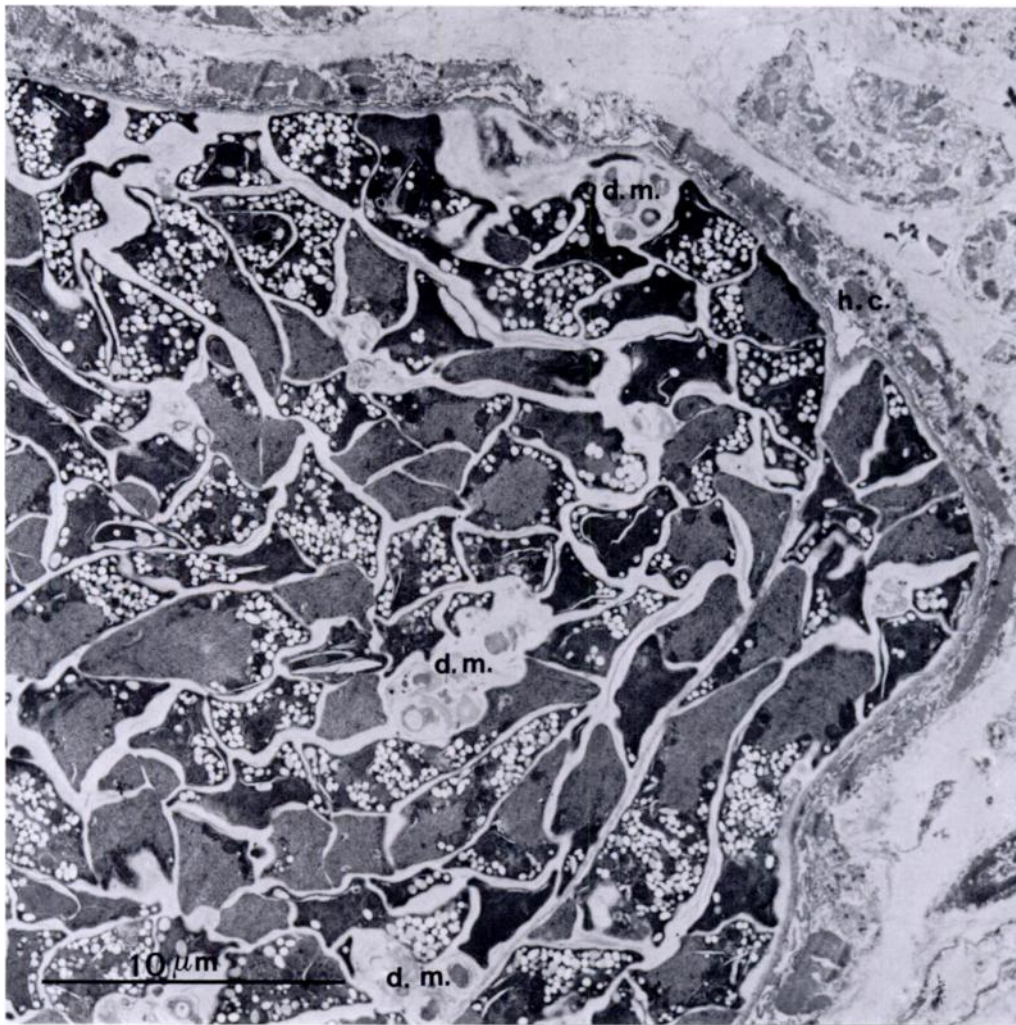


FIGURE 2. Electron micrograph of a heart muscle showing a marginal portion of a cyst of *Sarcocystis* sp. hc = host cell, dm = degenerating material.

primary cyst wall (PCW) morphology (Fig. 2). A secondary cyst wall was absent. The PCW was 20–30 nm thick and composed of a unit membrane, the parasitophorous vacuolar membrane (PVM) and an electron-dense layer immediately beneath the PVM. The PCW was highly folded forming sheet-like (cristae) projections over the surface of the cyst. In all the micrographs observed the projections appear as elongated digitations of variable length (2–3 μm) and relatively constant width (40–60 nm) (Fig. 3). The projections of PCW were thicker at their bases (190–200 nm thick).

Tangential sections of the PCW revealed the laminar arrangement of the sheet-like projections which were sinuous or tortuous always running in parallel with the cyst surface and overlapping each other, forming at most 4–5 layers. The zone of folded and overlapped projections reached a total thickness of 0.5–0.6 μm and corresponded to the “thin wall” observed by light microscopy. The projections of the PCW were often bifurcated at their tips (Fig. 4). The bifurcated tips were often adjacent to mitochondria and myofibrillae of the host cell. The whole surface of the cyst showed nu-

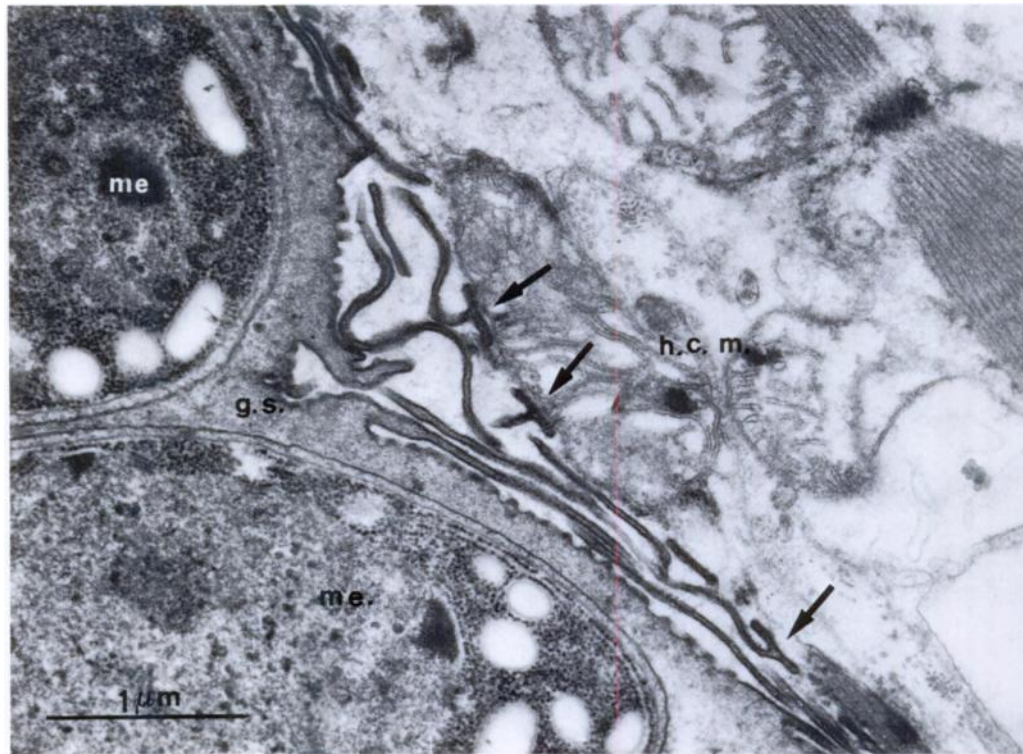


FIGURE 3. Details of the cyst wall of *Sarcocystis* sp. showing the projections of the primary cyst wall some of which appear branched at their tip (arrows) and adjacent to host cell mitochondria and myofibrils. The small invaginations of the cyst surface are visible also. me = metrocytes, gs = ground substance, hcm = host cell mitochondria.

merous regularly distributed invaginations of the primary cyst wall. These invaginations, up to 75 nm deep, appeared in tangential sections of the cyst wall as numerous electron-lucent spots (Fig. 5). Immediately beneath the PCW, there was a moderately electron-dense fibrogranular layer, 0.4–0.6 μm thick that extended into the projections of the PCW and also into the septa of the cyst, delimiting compartments containing numerous bradyzoites, few metrocytes and a few spheroid masses of degenerating material.

Bradyzoites were elongate with ultrastructural features typical of coccidian zoites such as a three membrane pellicle, an apical complex, a dense cytoplasm containing abundant free ribosomes, amylopectin, dense granules and mitochondria with tubular cristae. Their nucleus was lo-

cated posteriorly, and contained a prominent nucleolus and a few clumps of condensed chromatin. Metrocytes were spherical or ovoid with low electrodensity of their cytoplasm.

Of the five dogs that ingested *Sarcocystis* sp. infected meat, one shed sporocysts in its feces 10 days later, whereas four others shed sporocysts at 11 days, the two control dogs did not shed sporocysts. The dogs killed at 30 and 40 days postinfection were positive for the presence of sporocysts, the other three experimentally-infected dogs shed sporocysts continually for 40 days. None of the cats fed infected tissues shed sporocysts. Sporocysts measured $15.4 \times 8.8 \mu\text{m}$ ($\text{SD} = 0$, $n = 30$) and contained four sporozoites in addition to a central or terminal cluster of residual granules 7 μm in diameter (Fig. 6).

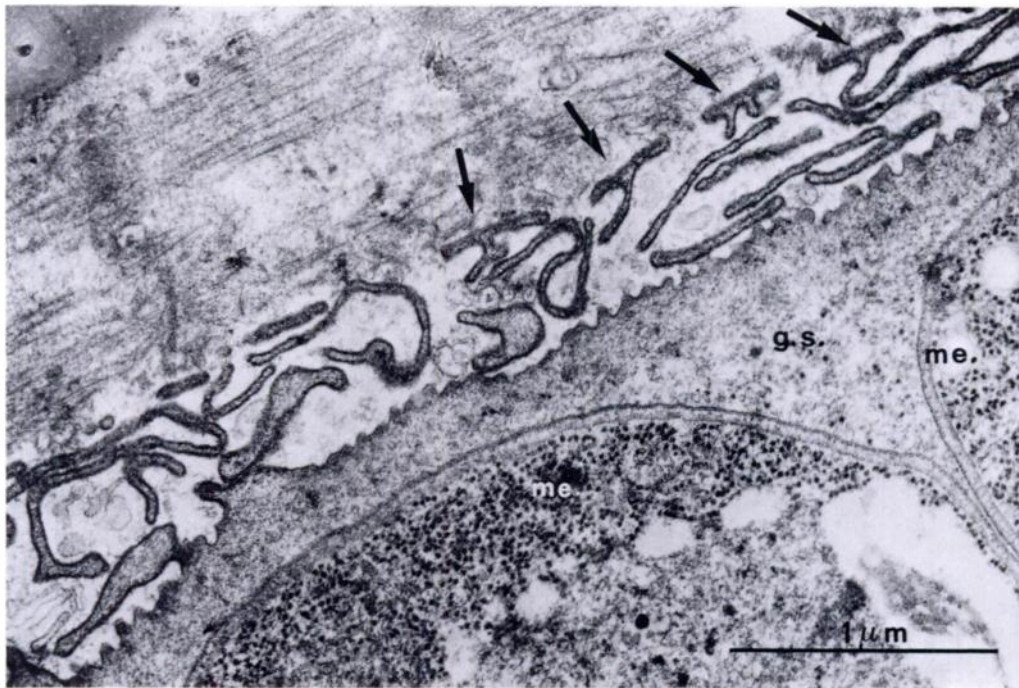

FIGURE 4. Same as Figure 3 except higher magnification.

DISCUSSION

The prevalence of *Sarcocystis* sp. infection in fallow deer of Natural Park of S. Rossore, Migliarino seems to be very high. It is comparable with the prevalence reported in other cervids, especially in animals >2 yr old (Mahrt and Colwell, 1980; Crum and Prestwood, 1982; Martinez-Gomez et al., 1985). However, in our study we did not find a significant difference in the prevalence between fawns and adults. Perhaps this may result from the high intensity of the infection.

We found that the digestion technique was a reliable method for detecting *Sarcocystis* sp. infection. However, as suggested by Crum and Prestwood (1982), a combination of both histologic and digestive examination would result in a more accurate estimate of prevalence.

The higher intensity of cysts found in histological sections of heart versus the tongue, oesophagus or muscle diaphragm corresponds with the report on *Sarcocystis cervicanis* in red deer from Spain (Mar-

tinez-Gomez et al., 1985). This is in contrast with the observations that in white-tailed deer (Mahrt and Colwell, 1980; Crum and Prestwood, 1982) and in mule deer (Sayama, 1952) the tongue is a major source of cysts.

All the cysts observed in fallow deer had a thin wall (<1 μm thick) that was ultrastructurally similar to those observed in type IV cysts from roe deer (Entzeroth, 1982) and to cysts of *S. cervicanis* (Hernandez-Rodriguez et al., 1981a), of *Sarcocystis* sp. from red deer (Entzeroth et al., 1983), of *Sarcocystis wapiti* from American elk (Speer and Dubey, 1982) and of *Sarcocystis grueneri* from reindeer (Gjerde, 1985a) and to a lesser extent similar to those of *Sarcocystis* sp. type A from moose (Colwell and Mahrt, 1981). Slight differences in the thickness of the cyst wall and/or in the spatial arrangement of the projections of the PCW exist between our findings reported herein and those of *Sarcocystis* spp. from these other cervids. However, some of these differences may be due

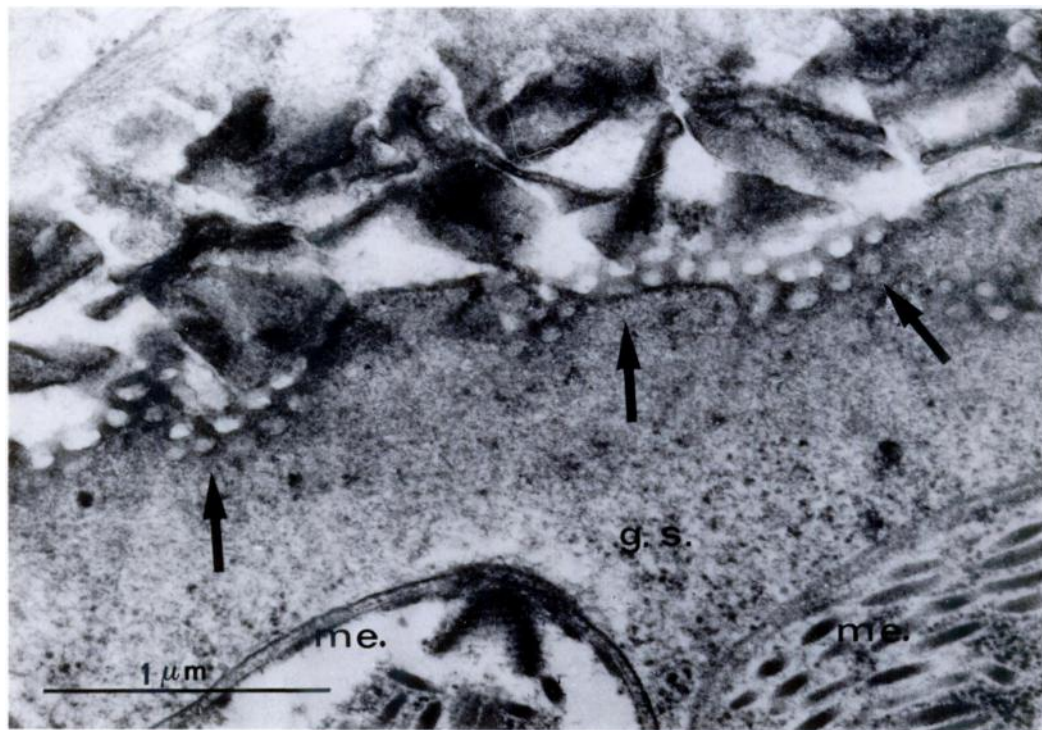


FIGURE 5. Tangential section through the cyst wall of *Sarcocystis* sp. The small invaginations of the cyst surface appear as lucid spots (arrows) and the projections reveal their flattened shape. me = metrocytes, gs = ground substance.

to the different methods employed for processing of specimens as well as to the interpretation of electron micrographs, rather than to real differences between the cysts from the various hosts.

Experimental infections indicated that the dog, but not the cat, is the definitive host of *Sarcocystis* sp. from fallow deer. Various species of Canidae have been demonstrated repeatedly to be infected by cystozoites of the genus *Sarcocystis* derived from several cervid species such as reindeer (Gjerde, 1984), red deer (Hernandez-Rodriguez et al., 1981b), American elk (Speer and Dubey, 1982), moose (Colwell and Mahrt, 1983) and possibly roe deer (Blazek et al., 1978).

Although the idea that *Sarcocystis* spp. are highly specific for the intermediate host, according to Dubey and Lozier (1983) morphology and life-cycle studies are not always reliable means of differentiating

among similar *Sarcocystis* spp. that occur in different cervid hosts (Entzeroth et al., 1985; Gjerde, 1985b). Nevertheless, cross-transmission experiments involving hosts that harbour morphologically similar *Sarcocystis* spp. seem to substantiate the idea of a high host specificity. For instance, sheep fed sporocysts of *Sarcocystis capracanis* and *Sarcocystis hircicanis* and two

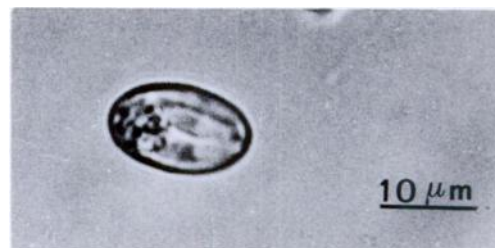


FIGURE 6. Light micrograph of a sporocyst of *Sarcocystis* sp. in fecal preparation from experimentally infected dog.

goats fed sporocysts of *Sarcocystis ovicanis* and *Sarcocystis tenella* did not become infected (Unterholzner, 1983). Other cross-transmission studies have established also that *S. ovicanis* and *S. capracanis* are separate species, although they have similar cyst wall structure (Aryeetey et al., 1980). Cysts of *Sarcocystis tarandi* from reindeer (Gjerde, 1985b) resemble morphologically those of *Sarcocystis hirsuta* from cattle (Gestrich et al., 1975). None of the *Sarcocystis* spp. from reindeer use the domestic cat as a definitive host (Gjerde, 1984).

Our findings support the idea that different *Sarcocystis* spp. may form morphologically indistinguishable cysts in related intermediate hosts and accordingly each cyst described from cervids could represent a different species. However, this problem can only be resolved by extensive cross-transmission and/or comparative biochemical (isoenzyme) studies of the *Sarcocystis* spp. from different cervids.

ACKNOWLEDGMENTS

This research was financed by a grant from Consiglio Nazionale Ricerche (Italy) and Amministrazione Provinciale, Pisa (Italy).

LITERATURE CITED

- ARYEETAY, M., H. MEHLHORN, AND A. O. HEYDORN. 1980. Electron microscopic studies on the development of *Sarcocystis capracanis* in experimentally infected goats. *Zentralblatt für Bakteriologie, Parasitenkunde, Infektionskrankheiten und Hygiene, Erste Abteilung Originale, Reihe A* 247: 543–556.
- BLAZĚK, K., J. SHRAMLOVÁ, AND R. IPPEN. 1978. Dog as definitive host of sarcosporidia infecting roe deer. *Folia Parasitologica* 25: 95–96.
- COLWELL, D. D., AND J. L. MAHRT. 1981. Ultrastructure of the cyst wall and merozoites of *Sarcocystis* from moose (*Alces alces*) in Alberta, Canada. *Zeitschrift für Parasitenkunde* 65: 317–329.
- , AND ———. 1983. Development of *Sarcocystis alceslatrans* Dubey, 1980, in the small intestine of dogs. *American Journal of Veterinary Research* 44: 1813–1818.
- CRUM, J. M., AND A. K. PRESTWOOD. 1982. Prevalence and distribution of *Sarcocystis* spp. among white-tailed deer of the southeastern United States. *Journal of Wildlife Diseases* 18: 195–203.
- DUBEY, J. P. 1980. Coyote as final host for *Sarcocystis* species of goats, sheep, cattle, elk, bison and moose in Montana. *American Journal of Veterinary Research* 41: 1227–1229.
- , AND S. M. LOZIER. 1983. *Sarcocystis* infection in white-tailed deer (*Odocoileus virginianus*) in Montana: Intensity and description of *Sarcocystis odoi* n. sp. *American Journal of Veterinary Research* 44: 1738–1743.
- , AND C. A. SPEER. 1985. Prevalence and ultrastructure of three types of *Sarcocystis* in mule deer *Odocoileus hemionus*, in Montana. *Journal of Wildlife Diseases* 21: 210–228.
- , AND ———. 1986. *Sarcocystis* infection in mule deer (*Odocoileus hemionus*) in Montana and the description of three new species. *American Journal of Veterinary Research* 47: 1052–1055.
- ENTZEROTH, R. 1982. A comparative light and electron microscope study of the cyst of *Sarcocystis* species of roe deer (*Capreolus capreolus*). *Zeitschrift für Parasitenkunde* 66: 281–292.
- , B. CHOBOTAR, AND E. SCHOLTYSECK. 1982. Ultrastructure of *Sarcocystis* sp. from the muscle of a white-tailed deer (*Odocoileus virginianus*). *Zeitschrift für Parasitenkunde* 68: 33–38.
- , ———, ———, AND L. NEMESERI. 1985. Light and electron microscope study of *Sarcocystis* sp. from fallow deer (*Cervus dama*). *Zeitschrift für Parasitenkunde* 71: 33–39.
- , L. NEMESERI, AND E. SCHOLTYSECK. 1983. Prevalence and ultrastructure of *Sarcocystis* sp. from the red deer (*Cervus elaphus* L.) in Hungary. *Parasitologica Hungarica* 16: 47–52.
- GESTRICH, R., H. MEHLHORN, AND A. O. HEYDORN. 1975. Licht und elektronenmikroskopische Untersuchungen an Cysten von *Sarcocystis fusiformis* in der Muskulatur von Kalbern nach experimenteller Infektion mit Oöcysten und Sporocysten der grossen Form von *Isospora bigemina* der Katze. *Zentralblatt für Bakteriologie, Parasitenkunde, Infektionskrankheiten und Hygiene, Erste Abteilung Originale, Reihe A* 233: 261–276.
- GJERDE, B. 1984. *Sarcocystis hardangeri* and *Sarcocystis rangi* n. sp. from the domestic reindeer (*Rangifer tarandus tarandus*) in northern Norway. *Acta Veterinaria Scandinavica* 25: 411–418.
- . 1985a. Ultrastructure of the cyst of *Sarcocystis grueneri* from cardiac muscle of reindeer (*Rangifer tarandus tarandus*). *Zeitschrift für Parasitenkunde* 71: 189–198.
- . 1985b. Ultrastructure of the cyst of *Sarcocystis tarandi* from skeletal muscle of reindeer (*Rangifer tarandus tarandus*). *Canadian Journal of Zoology* 63: 2913–2918.
- . 1985c. Ultrastructure of the cyst of *Sarcocystis rangi* from skeletal muscle of reindeer (*Rangifer tarandus tarandus*). *Rangifer* 2: 43–53.

- . 1985d. Ultrastructure of the cyst of *Sarcocystis tarandivulpes* from skeletal muscle of reindeer (*Rangifer tarandus tarandus*). *Acta Veterinaria Scandinavica* 26: 91–104.
- . 1985e. Ultrastructure of the cyst of *Sarcocystis rangiferi* from skeletal muscle of reindeer (*Rangifer tarandus tarandus*). *Canadian Journal of Zoology* 63: 2669–2675.
- . 1985f. Ultrastructure of the cyst of *Sarcocystis hardangeri* from skeletal muscle of reindeer (*Rangifer tarandus tarandus*). *Canadian Journal of Zoology* 63: 2676–2683.
- HERNANDEZ-RODRIGUEZ, S., F. MARTINEZ-GOMEZ, I. NAVARRETE, AND I. ACOSTA-GARCIA. 1981a. Estudio al microscopio optico y electronico del quiste de *Sarcocystis cervicanis*. *Revista Iberica de Parasitologia* 41: 351–361.
- , I. NAVARRETE, AND F. MARTINEZ-GOMEZ. 1981b. *Sarcocystis cervicanis*, nueva especie parasita del ciervo (*Cervus elaphus*). *Revista Iberica de Parasitologia* 41: 43–51.
- HUDKINS, G., AND T. P. KISTNER. 1977. *Sarcocystis hemionilatrantis* (sp. n.) life cycle in mule deer and coyotes. *Journal of Wildlife Diseases* 13: 80–84.
- JOHNSON, A. J., P. K. HILDERBRANDT, AND R. FAYER. 1975. Experimentally induced sarcocystis infection in calves: Pathology. *American Journal of Veterinary Research* 36: 995–999.
- KOLLER, L. D., T. P. KISTNER, AND G. G. HUDKINS. 1977. Histopathologic study of experimental *Sarcocystis hemionilatrantis* infection in fawns. *American Journal of Veterinary Research* 38: 1205–1209.
- LEEK, R. G., R. FAYER, AND A. J. JOHNSON. 1977. Sheep experimentally infected with *Sarcocystis* from dogs. I. Disease in young lambs. *The Journal of Parasitology* 63: 642–650.
- MAHRT, J. L., AND D. D. COLWELL. 1980. *Sarcocystis* in wild ungulates in Alberta. *Journal of Wildlife Diseases* 16: 571–576.
- MARTINEZ-GOMEZ, S., S. HERNANDEZ-RODRIGUEZ, I. NAVARRETE, AND I. ACOSTA-GARCIA. 1985. Sarcocystosis in red deer (*Cervus elaphus*). Sonderdruck aus Verhandlungsbericht des 27. Internationalen Symposiums über die Erkrankungen der Zootiere, St. Vincent (Torino), Italia, pp. 155–157.
- POLI, A., M. ARISPICI, M. NIGRO, AND F. MANCIANTI. 1986. Morphological studies on *Sarcocystis* in fallow deer (*Dama dama*). Sonderdruck aus Verhandlungsbericht des 28. Internationalen Symposium über die Erkrankungen der Zootiere, Rostock, Deutsche Demokratische Republik, pp. 365–368.
- SAYAMA, K. 1952. *Sarcocystis* in deer and elk of California. *California Fish and Game* 38: 99–104.
- SPEER, C. A., AND J. P. DUBEY. 1982. *Sarcocystis wapiti* sp. n. from the North American wapiti (*Cervus elaphus*). *Canadian Journal of Zoology* 60: 881–888.
- , AND ———. 1986. An unusual structure in the primary cyst wall of *Sarcocystis hemionilatrantis*. *Journal of Protozoology* 33: 130–132.
- UNTERHOLZNER, J. 1983. Zur Entwicklung einer neuen von Hund übertragenen Sarkosporidienart (*Sarcocystis* sp. (Z.)) der Ziege. *Veterinär Medizin Dissertationen, Freien Universität Berlin, Berlin, Federal Republic of Germany*, 64 pp.

Received for publication 8 January 1987.