

CANINE DISTEMPER IN BLACK-FOOTED FERRETS (MUSTELA NIGRIPES) FROM WYOMING

Authors: Williams, E. S., Thome, E. T., Appel, M. J. G., and Belitsky, D. W.

Source: Journal of Wildlife Diseases, 24(3) : 385-398

Published By: Wildlife Disease Association

URL: <https://doi.org/10.7589/0090-3558-24.3.385>

BioOne Complete (complete.BioOne.org) is a full-text database of 200 subscribed and open-access titles in the biological, ecological, and environmental sciences published by nonprofit societies, associations, museums, institutions, and presses.

Your use of this PDF, the BioOne Complete website, and all posted and associated content indicates your acceptance of BioOne's Terms of Use, available at www.bioone.org/terms-of-use.

Usage of BioOne Complete content is strictly limited to personal, educational, and non - commercial use. Commercial inquiries or rights and permissions requests should be directed to the individual publisher as copyright holder.

BioOne sees sustainable scholarly publishing as an inherently collaborative enterprise connecting authors, nonprofit publishers, academic institutions, research libraries, and research funders in the common goal of maximizing access to critical research.

CANINE DISTEMPER IN BLACK-FOOTED FERRETS (*MUSTELA NIGRIPES*) FROM WYOMING

E. S. Williams,¹ E. T. Thorne,² M. J. G. Appel,³ and D. W. Belitsky⁴

¹ Department of Veterinary Sciences, University of Wyoming, 1190 Jackson, Laramie, Wyoming 82070, USA

² Wyoming Game and Fish Department, Box 3312 University Station, Laramie, Wyoming 82071, USA

³ James A. Baker Institute for Animal Health, Department of Microbiology,
New York State College of Veterinary Medicine, Cornell University, Ithaca, New York 14853, USA

⁴ Wyoming Game and Fish Department, 260 Buena Vista, Lander, Wyoming 82520, USA

ABSTRACT: In September and October 1985, six black-footed ferrets (*Mustela nigripes*) were captured from the only known population, located near Meeteetse, Wyoming for captive propagation. Two days following capture an adult male showed signs of canine distemper and an adult female displayed similar signs 7 days postcapture; these infections were undoubtedly acquired prior to capture. Subsequently the four remaining captive black-footed ferrets also developed canine distemper and all eventually died. Clinical signs included severe pruritus, hyperkeratosis and progressive loss of body condition. A few animals had intermittent diarrhea and respiratory disease. Intranuclear and intracytoplasmic inclusion bodies were numerous in epithelial tissues and two black-footed ferrets had a mild to moderate meningoencephalitis. Canine distemper virus was isolated from four animals and paramyxovirus nucleocapsids were observed by electron microscopy of feces from all affected black-footed ferrets. Antibodies to canine distemper virus were not detected in sera of sick black-footed ferrets. Antibodies to canine distemper virus were found in sera of badgers (*Taxidea taxus*) and coyotes (*Canis latrans*) collected in the Meeteetse area in 1986. Most free-ranging black-footed ferrets in the colony apparently died of canine distemper during the summer and fall of 1985. An attempt was made to capture all surviving animals in the affected area in order to abort the epizootic and provide black-footed ferrets for captive propagation.

Key words: *Mustela nigripes*, black-footed ferret, endangered species, canine distemper, pathology, serology, survey, case report.

INTRODUCTION

Canine distemper (CD) is a common, highly infectious viral disease of domestic and wild, free-ranging and captive Canidae, Procyonidae, and Mustelidae (Budd, 1981). It is frequently diagnosed in Wyoming in free-ranging striped skunks (*Mephitis mephitis*) and raccoons (*Procyon lotor*) and less frequently in coyotes (*Canis latrans*), badgers (*Taxidea taxus*), and mink (*Mustela vison*) (Williams, 1982; Thorne et al., 1985b).

In the fall of 1985, CD was diagnosed in an adult male and an adult female black-footed ferret (*Mustela nigripes*) shortly after capture from the only known population. Subsequently, four additional captive black-footed ferrets developed CD. Most of the free-ranging animals disappeared; they presumably died from canine distemper virus (CDV) infection (Thorne, 1987).

This report documents the clinical and pathologic features of CD in black-footed ferrets and discusses the implications of this disease for the captive and wild populations of black-footed ferrets.

CASE HISTORY

In September 1981, when black-footed ferrets were thought to be near extinction in the wild, a colony of ferrets was found in a large complex of white-tailed prairie dog (*Cynomys leucurus*) colonies near Meeteetse, Park County, Wyoming, USA (44°05'–44°15'N, 108°55'–109°15'W). Since that time the population has been the subject of intense study by state, federal, and private biologists (Anderson and Inkley, 1985). The importance of disease to the black-footed ferret colony was recognized and precautions were initiated shortly af-



ter their discovery to reduce the opportunity for human-related disease introduction (Thorne et al., 1985a; Thorne, 1987; Thorne, 1988).

Estimates of black-footed ferret numbers were derived from litter surveys conducted in late summer and mark-recapture results (Forrest et al., 1988). Black-footed ferret numbers estimated in July and early August were 61, 88, 129, and 58 in years 1982, 1983, 1984, and 1985, respectively, and 15 animals in 1986 (Wyoming Game and Fish Department, 1987; Forrest et al., 1988; Belitsky, 1988). The peak population estimate of 128 ± 25 black-footed ferrets in fall 1984 was followed by a loss of black-footed ferrets over the winter and spring (Belitsky, 1988; Thorne, 1988) and an estimate of 58 by litter survey in July and early August 1985 (Forrest et al., 1988). This decline was due, in part, to juvenile dispersal and mortality, which has been estimated to be between 60 and 80% each year when disease is not a factor (Forrest et al., 1988) and as suggested by the recapture in 1985 of 6 of 29 adults and none of 49 juvenile black-footed ferrets eartagged in 1984 (Forrest et al., 1988). The population declined further; and by early October, it was estimated by mark-recapture technique to contain 16 ± 4 animals (Forrest et al., 1988).

In June 1985, sylvatic plague (*Yersinia pestis*) was diagnosed in prairie dogs (Urbico et al., 1988), the primary prey of the black-footed ferrets (Sheets et al., 1972). No more than 20% of the area of prairie dog habitat was presumed lost to plague from 1984 to 1985 (Forrest et al., 1988). Domestic ferrets (*Mustela putorius furo*) and Siberian polecats (*Mustela eversmanni*) were shown to be resistant to plague (E. S. Williams et al., unpubl. data), and there was no apparent evidence that plague adversely affected the black-footed ferret population (Forrest et al., 1988).

In late September and early October 1985, while and immediately after the mark-recapture population estimate was being made, six black-footed ferrets were

captured for captive propagation at the Wyoming Game and Fish Department's Sybille Wildlife Research and Conservation Education Unit (Thorne, 1987). Black-footed ferrets were captured in tubular live traps (Hillman, 1972), examined while in the trap for condition, health, age, and sex and placed individually into large wooden boxes which contained burlap (Thorne et al., 1985a). The animals were transported from the Meeteetse area to Sybille in covered vehicles within 18 hr of capture.

Two days following capture the last caught black-footed ferret, an adult male, was observed to be extremely pruritic and an adult female became depressed 7 days postcapture. The disease was diagnosed as CD, and the other four captive black-footed ferrets subsequently developed the disease. Eventually all six captive and probably most free-ranging black-footed ferrets died of CD.

Following diagnosis of CD, a management decision was made to attempt to capture all black-footed ferrets remaining, except those that may have been present in the outlying prairie dog colonies. This was done in an attempt to further reduce the population and interrupt the epizootic; to remove infected animals, if captured, from the population; and to provide animals for captive propagation (Thorne, 1987; Thorne, 1988). Six black-footed ferrets were captured and placed in strict isolation; they did not develop CD.

Surveys of the Meeteetse black-footed ferret habitat during the winter of 1985–1986 indicated minimal ferret activity suggesting very few remaining wild black-footed ferrets (Belitsky, 1988; Thorne, 1988). Additional surveys in the summer of 1986 demonstrated approximately five black-footed ferrets, including two females that produced litters, escaped the distemper epizootic (Belitsky, 1988).

MATERIALS AND METHODS

The six captive black-footed ferrets that died of CD were monitored visually twice daily for signs of disease. They were housed in an $8.5 \times$

2 m room with large windows and daylight spectrum lighting adjusted to the natural photoperiod. Cages for individual black-footed ferrets were 152 × 81 × 61 cm and constructed of painted wood ends and floors with vinyl coated wire mesh on tops, fronts, and backs. Cages were arranged end to end in a row with two solid plywood ends approximately 2.5 cm apart between adjacent cages. The black-footed ferrets that contracted CD in the wild were located in cages 1 and 4. Initially, cages contained a layer of clean dry sand. An unpainted two-chambered wooden nest box was located 1 m below the level of the main cage and was accessed by brown plastic downspout pipe. Clean dry straw or shredded white paper was supplied for nest material. Temperature in the ferret room was maintained between 7 and 18 C. Separate sponges, spatulas, and rolls of paper towels were used for cleaning individual cages; spatulas were soaked in bactericidal and virucidal disinfectant (Nolvasan Solution®, Aveco Company, Inc., Fort Dodge, Iowa 50501, USA) between uses. Access to the black-footed ferrets was limited; a shower and use of a face mask, cap, and clean overalls was required for entry.

Most black-footed ferrets captured during research activities since 1982 were vaccinated subcutaneously with a beta propiolactone inactivated Onderstepoort strain CDV vaccine (supplied by M. J. G. Appel, James A. Baker Institute for Animal Health, Department of Microbiology, New York State College of Veterinary Medicine, Cornell University, Ithaca, New York 14853, USA) without adjuvant (Thorne et al., 1985a). One of the first six black-footed ferrets captured for captive propagation was vaccinated twice in the summer of 1984, and in 1985 all of the original captive black-footed ferrets were vaccinated two or three times with the same vaccine. During the course of disease, these black-footed ferrets were vaccinated one or two times each with the same inactivated CDV vaccine but this time with adjuvant (Fort Dodge Laboratories, Fort Dodge, Iowa 50501, USA).

As soon as signs of CD were recognized, sick black-footed ferrets were isolated from apparently healthy animals by moving them to the Veterinary Medical Research Center (Department of Veterinary Sciences, University of Wyoming, Laramie, Wyoming 82070, USA) and monitored and treated twice daily. Monitoring involved recording clinical signs, including food and water intake, fecal consistency, evidence of urination, attitude, behavior, appearance, and periodic examination of feces by negative staining techniques and electron microscopy for the presence of viral particles morphologically consistent with CDV (Nunamaker and Williams,

1987) and by floatation and direct examination for internal parasites. Feces for parasitology were preserved in 2% potassium dichromate.

Supportive therapy given the black-footed ferrets included subcutaneous administration of lactated Ringer's solution when needed for dehydration; antibiotic treatment with lincomycin (UpJohn Company, Kalamazoo, Michigan 49001, USA), gentamycin (Schering Corporation, Bloomfield, New Jersey 07003, USA) or tribissen (Burroughs Wellcome Company, Kansas City, Missouri 64108, USA); and nutritional support including skinned prairie dog pieces, whole mice, and nutritional supplement (Nutri-cal®, Evsco Pharmaceuticals, Immunogenetics, Inc., Buena, New Jersey 08310, USA).

Canine distemper incubation periods were estimated by two methods using development of clinical signs as endpoints. A maximum incubation period for four animals was estimated from the date the first black-footed ferret developed clinical CD to the date of development of clinical signs in these four animals. Minimum incubation periods were estimated from the date of last exposure to an affected animal and development of clinical signs.

Black-footed ferrets were necropsied minutes to several hours after death. Blood was collected by syringe from the heart or from severed peripheral vessels and allowed to clot, and serum was removed and frozen. Liver, lung, lymph nodes and spleen were collected for virus isolation and stored at -70 C until cultured for viruses. Lung, liver and swabs of the external auditory meatus were cultured by routine bacteriologic methods for pathogenic bacteria. Portions of a wide variety of organs were fixed in 10% neutral buffered formalin; embedded in paraffin; sectioned at 6-7 µm; stained with hematoxylin and eosin and, for selected tissues, with periodic acid-Schiff techniques; and examined by light microscopy. Impression smears of urinary bladder and conjunctiva from two animals were air dried and stained with Wright's stain and with hematoxylin and eosin.

Canine distemper virus isolations were made in dog lung macrophage cultures in Leighton tubes (Appel and Jones, 1967). A 10% suspension in Eagles medium (Gibco Laboratories, Grand Island, New York 14072, USA) was prepared from lung tissues from four black-footed ferrets. The presence of CDV caused syncytia formation and was confirmed by specific immunofluorescence (Appel and Jones, 1967; Appel and Gillespie, 1972). Virus titrations were made in dog lung macrophage cultures in 96 well microplates (Corning Glassware, Corning, New York 14830, USA) in three-fold dilution steps. Isolated virus was identified by neutralization with CDV anti-serum (Appel and Robson, 1973).

Three young adult CD susceptible domestic ferrets were obtained (Marshall Farms, North Rose, New York 14516, USA) and kept in isolation units of the J. A. Baker Institute for Animal Health (New York State College of Veterinary Medicine, Cornell University, Ithaca, New York 14853, USA). They were fed commercial cat food (Purina Cat Chow, Ralston Purina Company, St. Louis, Missouri 63164, USA) and water. After a 3-wk observation period, each domestic ferret was inoculated intraperitoneally with 0.5 ml of a 10% black-footed ferret lung suspension in Eagles medium. The lung suspension had a virus titer of $1 \times 10^{6.2}$ mean infectious doses/ml when titrated in dog lung macrophage cultures. The animals were observed daily for clinical signs of CD. At necropsy, imprints on glass microscope slides were prepared from lymph nodes and lungs and stained with CDV specific fluorescent antibody for detection of CDV antigen (Appel and Gillespie, 1972).

Canine distemper virus serum neutralizing antibody titers were determined by serial dilutions in 96 well microplates (Appel and Robson, 1973). Sera were collected from six healthy black-footed ferrets which did not develop CD, including one mature and five juvenile females following subcutaneous vaccination. The mature female received one dose of inactivated CDV vaccine without adjuvant followed by two doses of inactivated vaccine with adjuvant over a 77-day period. One juvenile received two doses of inactivated CDV vaccine without adjuvant followed by two doses of inactivated vaccine with adjuvant over a 51-day period. Sera were collected from these animals 13 days after the last vaccination. Three juvenile black-footed ferrets were vaccinated three times with inactivated CDV vaccine with adjuvant over a 23-day period and sera were collected 19 days after the last vaccination. One juvenile black-footed ferret was vaccinated twice with inactivated CDV vaccine with adjuvant over a 33-day period and serum was collected 8 days after the last vaccination.

From December 1985 through September 1986, four skunks, four raccoons, 14 badgers, 10 coyotes and a long-tailed weasel (*Mustela frenata*) from the Meeteetse area were shot or trapped and killed to survey for diseases. Blood was collected by syringe or by draining blood into clean, dry glass tubes from the heart or severed jugular vein or peripheral vessels. The carcasses and blood samples were packed in ice in styrofoam coolers and transported by air, generally within 24 hr of death, from Cody, Wyoming to Laramie where they were examined for evidence of CDV infection. Serum was collected and frozen, the animals were necropsied, and tissues were collected for histopathology.

Feces were examined for particles consistent with CDV nucleocapsids by electron microscopy.

RESULTS

Clinical signs

Minimum and maximum incubation periods were calculated as days from the most recent and earliest, respectively, exposure to CDV until development of detectable clinical signs of CD. Incubation periods were estimated for four black-footed ferrets to be a minimum of 13 and a maximum of 52 days, with incubation period ranges for three animals determined to be between 16 and 35 days. Two black-footed ferrets were assumed to have been incubating the disease when captured and thus incubation periods could not be estimated. The duration of clinical disease prior to death ranged from 14 to 48 days (Table 1).

Clinical signs of CD in black-footed ferrets are shown in Table 1. The most striking initial clinical sign in most animals was severe pruritus. Affected black-footed ferrets rubbed their faces and trunk along the wire of the cage, in the sand flooring, or on the edges of the holes into the nest boxes. Occasionally, black-footed ferrets scratched the anterior portions of their bodies with claws of their hind feet. Vigorous head shaking was observed in two black-footed ferrets.

Wrinkling and hyperemia of the skin of the forehead and slight hyperemia of the ears and chin were observed in all animals. As the disease progressed the skin, ears, nose, eyelids and footpads became increasingly hyperkeratotic (Fig. 1). The ears frequently became so hyperkeratotic they cracked and most ear tags were dislodged. A few animals lost considerable hair and one female was diffusely hyperkeratotic and nearly alopecic when she died (Fig. 1). Secretions of the anal scent glands of the males were inspissated and the glands were firm.

All sick black-footed ferrets became depressed and often had a dull facial expres-

TABLE 1. Clinical signs and pathology of black-footed ferrets infected with canine distemper virus.

	Ferret number					
	640 (30) ^a	649 (48)	653 (25)	680 (15)	684 (14)	686 (42)
Clinical signs						
Hyperkeratosis	+ ^b	+	+	+	+	+
Depression	+	+	+	+	+	+
Skin hyperemia	+	+	+	+	+	+
Pruritus	+	+	+	+	+	— ^c
Diarrhea	+	+	+	—	—	+
Anorexia	+	—	—	+	+	+
Polydipsia	—	+	+	+	—	+
Alopecia	—	+	—	—	—	+
Nasal discharge	—	+	+	—	—	—
Photophobia	—	—	+	—	—	—
Conjunctivitis	—	—	—	—	+	—
Gross lesions						
Hyperkeratosis	+	+	+	+	+	+
Emaciation	+	—	+	—	+	+
Intestinal hemorrhage	—	+	+	—	+	—
Alopecia	—	+	—	—	—	+
Gastric hemorrhage	—	—	—	+	+	—
Thymic atrophy	—	+	—	+	—	+
Chronic nephritis	—	—	+	—	+	—
Bronchopneumonia	—	+	—	—	—	—
Hepatic lipidosis	—	—	—	+	—	—
Dehydration	—	—	—	—	+	—
Conjunctivitis	—	—	—	—	+	—
Lymphadenopathy	—	+	—	—	—	—
Splenomegaly	—	+	—	—	—	—
Histopathologic lesions						
Hyperkeratosis	+	+	+	+	+	+
Lymphoid depletion	+	+	+	+	+	+
Hepatic lipidosis	+	+	+	+	+	+
Dermatitis	+	+	+	+	+	+
Inclusions in epithelium	+	+	+	+	+	+
Inclusions in brain	—	+	+	+	—	+
Interstitial pneumonia	—	+	+	+	—	+
Bronchitis	+	+	—	—	+	—
Sialoadenitis	—	+	—	+	+	—
Intestinal protozoa	+	—	+	—	+	—
Pyelonephritis	—	—	+	—	+	—
Chronic nephritis	—	—	+	—	+	—
Nonsuppurative meningoencephalitis	—	+	—	—	—	+
Keratitis	—	—	—	—	+	—
Ureteritis	—	+	—	—	—	—
Suppurative bronchopneumonia	—	+	—	—	—	—
Tracheal protozoa	+	—	—	—	—	—
Muscle protozoa	+	—	—	—	—	—
Focal meningitis	+	—	—	—	—	—

^a Duration of clinical disease in days (d).^b Sign or lesion present.^c Sign or lesion not observed.



FIGURE 1. Diffuse hyperkeratosis and alopecia in a black-footed ferret with canine distemper.

sion. There was considerable individual variation in black-footed ferret reaction to human presence. Some black-footed ferrets, especially adults, were relatively calm during treatments while others were aggressive until late in the course of disease. Several black-footed ferrets were anorexic from the initial stages of disease, some had fluctuating appetites, and two black-footed ferrets continued to eat relatively normal quantities until several days before death. Sick black-footed ferrets drank as much as 50 ml of water in 24 hr, compared to healthy captive black-footed ferrets which drink relatively little water.

One black-footed ferret had a slight serous nasal discharge in the early stages of disease which disappeared within several days. In the few days before death, two animals showed evidence of respiratory disease; one had a mild mucopurulent nasal exudate and the other was slightly dyspneic. Only one black-footed ferret developed keratoconjunctivitis; the other animals had varying degrees of eyelid hy-

perkeratosis without significant conjunctival exudate.

Feces were usually of normal to soft consistency throughout the course of disease. Occasionally, diarrheic feces were passed and three black-footed ferrets had melena and/or bloody diarrhea at the time of death.

Signs of nervous system disease were not observed in these black-footed ferrets, with the exception of one animal that bit at her rear leg repeatedly for several minutes on the day before she died and again just prior to death. This behavior may have been an attempt by a weak animal to bite the handler; however, microscopic lesions were present in the brain of this individual.

Results of examination of feces from 12 black-footed ferrets are shown in Table 2. Canine distemper virus-like particles (Fig. 2) were detected in every fecal sample tested from animals with clinical CD. In one case, viral particles were detected 20 days prior to development of clinical signs of CD (Table 2). Six healthy black-footed

TABLE 2. Results of examination of black-footed ferret feces by electron microscopy for canine distemper virus-like particles.

Animal number	Date clinical disease recognized	Date of fecal examination	Results
640	9 Nov 1985	11 Nov 1985	+
649	10 Nov 1985	21 Oct 1985	+
		11 Nov 1985	+
		27 Dec 1985	+
		21 Oct 1985	+
653	19 Oct 1985	23 Oct 1985	+
		21 Oct 1985	+
680	6 Nov 1985	7 Nov 1985	+
684	8 Oct 1985	21 Oct 1985	+
686	27 Nov 1985	11 Nov 1985	— ^b
		1 Dec 1985	+
		7 Jan 1986	+
		3 Dec 1985	—
		5 Dec 1985	—
Six clinically healthy black-footed ferrets		10 Dec 1985	—
		17 Dec 1985	—
		2 Jan 1986	—
			—

* Canine distemper virus-like particles present.

^b Canine distemper virus-like particles not observed.

ferrets which did not develop CD were always negative for these particles in their feces.

Examination of feces for parasites showed the presence of two species of *Eimeria* in all sick black-footed ferrets, occasionally in large numbers. Coccidian oocysts, in low numbers, were present in feces of approximately 30% of healthy animals. Skin scrapings from several black-footed ferrets were negative for ectoparasites.

Pathology

Results of postmortem examinations are shown in Table 1. Gross lesions included severe hyperkeratosis of skin, foot pads, eyelids, ears, and nose; emaciation; hemorrhagic gastroenteritis in one black-footed ferret; hemorrhagic colitis in two animals; and focal bronchopneumonia in one animal. Atrophy of the thymus was grossly apparent in juvenile black-footed ferrets and enlargement of mesenteric and peripheral lymph nodes was observed in one animal. Scattered pitting and irregularity of the renal cortex was observed in two black-footed ferrets and in one of these

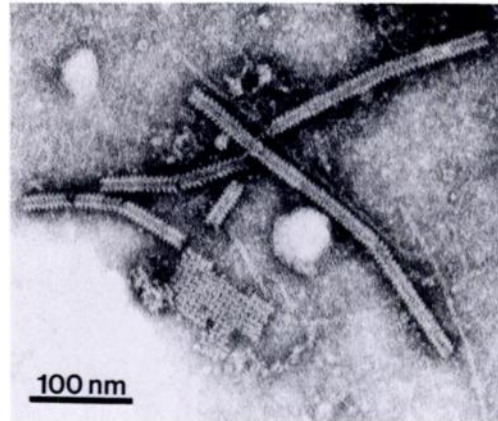


FIGURE 2. Negatively stained transmission electron micrograph of paramyxovirus-like nucleocapsids in the feces of a ferret with clinical signs of canine distemper.

animals the renal pelvis was gritty when sectioned.

Microscopic examination of a variety of organs revealed numerous large eosinophilic cytoplasmic and intranuclear inclusion bodies in epithelial cells of urinary bladder (Fig. 3), renal pelvis, epididymis, bronchi and bronchioles, bile ducts, pancreatic ducts and islets, tongue, stomach, skin, conjunctiva, ependyma and macrophages in many locations in the body including meninges. Impression smears of conjunctiva and urinary bladder also contained inclusion bodies in epithelial cells.

Skin lesions were characterized by marked hyperkeratosis (Fig. 4), focal necrosis with neutrophilic infiltration, and the presence of bacterial colonies on the surface and in hair follicles. Cytoplasmic inclusion bodies were in cells of the epidermis and multinucleated cells were occasionally present.

In black-footed ferret 684, developmental forms of a large *Eimeria* sp. were present in many epithelial cells of the distal one-half of the villi in jejunum and ileum (Fig. 5). Crypt cells were seldom parasitized. The lamina propria was lightly infiltrated with lymphocytes and macrophages. In another black-footed ferret (640), developmental forms of a smaller *Eimeria* sp. were scattered in epithelial

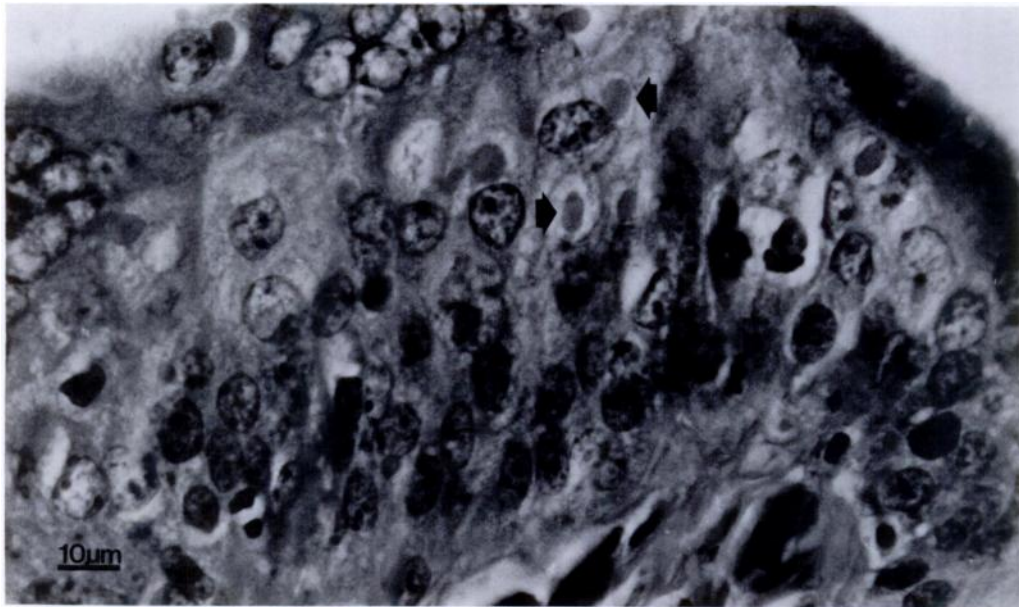


FIGURE 3. Typical intracytoplasmic inclusion bodies of canine distemper (arrows) in urinary bladder epithelium of an affected black-footed ferret. H&E.

cells of the distal small intestine. Inflammatory reaction to this parasite was minimal. Numerous comma shaped protozoa that were identified as *Giardia* sp. on fecal examination were present in the lumen of the distal small intestine and colon of a black-footed ferret (653).

In black-footed ferret 640, epithelial cells lining the trachea, a large bronchus and associated glands contained schizonts of a protozoan parasite. Impression smears of urinary bladder from 684 revealed numerous epithelial cells containing protozoal zoites. Cysts of a protozoan parasite resembling *Sarcocystis* sp. were present in skeletal muscle of black-footed ferret 640.

The anterior portion of the lung of one black-footed ferret contained an alveolar and bronchiolar infiltrate of a few neutrophils. Bronchi and bronchioles contained macrophages and neutrophils in several animals. Alveolar septae were hypercellular and capillaries were congested in four black-footed ferrets. Depletion and necrosis of lymphocytes in germinal centers of lymph nodes and spleen occurred in many black-footed ferrets; sinus histiocytosis and the presence of multinucleated cells were

common; and thinning of the thymic cortex occurred in juvenile black-footed ferrets.

A mild lymphocytic infiltrate was observed in the meninges of one animal. Nonsuppurative meningoencephalitis occurred in the two black-footed ferrets with the longest duration of clinical disease. Degenerative changes were observed in testicles of the males and spermatozoa were not present.

Lesions in the kidneys of two black-footed ferrets were characterized by interstitial fibrosis and a mild mononuclear inflammatory cell infiltrate, and dilated tubules with mineralization of debris within distal tubules and at the renal pelvis.

Virus isolation

Canine distemper virus was isolated from lungs of all four affected black-footed ferrets on which virus isolation was attempted. Virus titers were between $1 \times 10^{4.5}$ and $1 \times 10^{6.2}$ mean cell culture infectious doses/ml of 10% suspension. The isolated virus was neutralized by CDV specific antiserum.

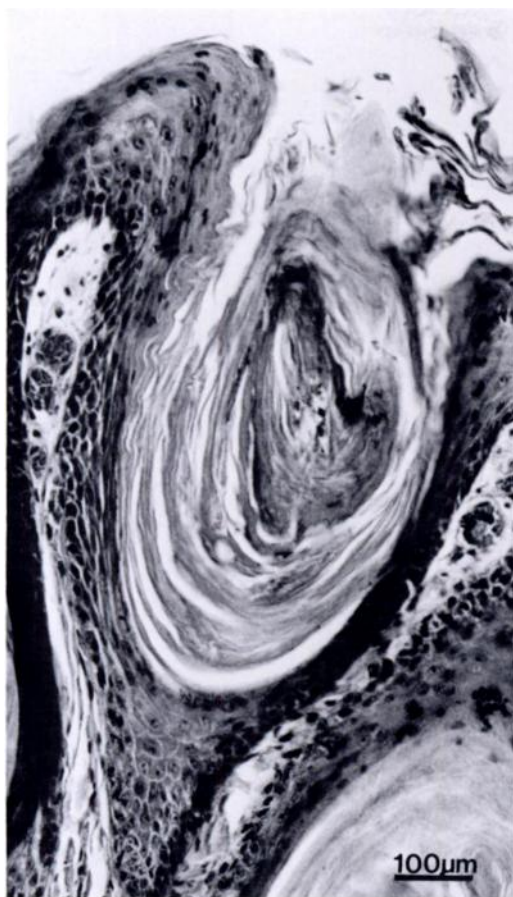


FIGURE 4. Follicular and epidermal hyperkeratosis and dermatitis in a black-footed ferret. H&E.

Domestic ferret inoculations

The three inoculated domestic ferrets died between 21 and 23 days postinoculation. The first signs of disease were seen between 12 and 19 days postinoculation and consisted of anorexia and mucous discharge with crust formation around the eyes. The animals gradually became dehydrated and moribund 4 to 8 days after the appearance of first clinical signs. Imprints from lymphatic tissues and lungs of all domestic ferrets showed CDV antigen by immunofluorescence with specific CDV conjugate.

Serology

Sera from four black-footed ferrets that died of CD did not contain neutralizing

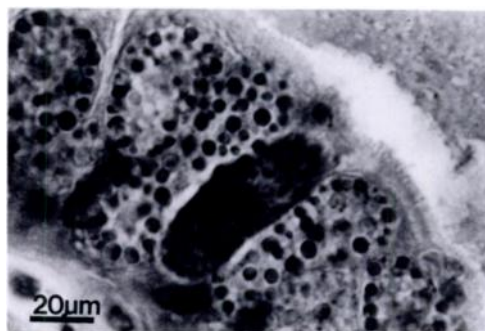


FIGURE 5. Developmental stages of the large *Eimeria* sp. in the small intestine of a ferret with canine distemper. H&E.

antibodies to CDV. Sera from six healthy black-footed ferrets had CDV neutralizing antibody titers of 1:60 to 1:1,000 following vaccination with the inactivated vaccine with adjuvant.

Carnivore survey

Canine distemper virus was not detected in feces and there was no gross or microscopic evidence of active CD in any of the carnivores collected at Meeteetse. Two of 14 badgers and five of 10 coyotes had serum neutralizing antibodies to CDV ranging between approximately 1:100 to 1:1,000. Antibodies to CDV were found only in adult animals. Skunks, raccoons and the weasel were negative for CDV antibodies.

DISCUSSION

Canine distemper caused 100% mortality in six recently captured black-footed ferrets in Wyoming in 1985–1986. Distemper is a well known, usually fatal infection of wild mustelids (Budd, 1981) and the disease is considered essentially 100% fatal in domestic ferrets (Appel et al., 1981; Bernard et al., 1984; Davidson, 1986). Black-footed ferrets may be exceptionally susceptible to CD as shown by their fatal response to a modified-live CDV vaccine demonstrated to be safe in domestic ferrets and Siberian polecats (Carpenter et al., 1976).

The estimated minimum and maximum incubation periods of CD in these black-

footed ferrets, 13 to 52 days, were probably longer than the incubation period (not reported) in the four black-footed ferrets which died within 21 days following inoculation with a CDV vaccine strain (Carpenter et al., 1976). Incubation periods are difficult to determine during an epizootic in contrast to incubation periods derived from experimental exposure in a controlled study, because exact time of exposure is unknown. Our estimates do not take into account possible exposure of healthy black-footed ferrets to CDV shed by subclinically affected animals. Controlled studies would be necessary to determine routes and duration of CDV shedding during the course of the disease. Exposure was assumed to have been by aerosol or fomites as black-footed ferrets were never in direct contact. One black-footed ferret shed CDV for at least 20 days before developing clinical CD. Incubation periods of 7 to 10 days are common in domestic ferrets (Ryland and Gorham, 1978). There is considerable biological variation between CDV strains, which may influence incubation periods (Appel et al., 1981). Another explanation for the relatively long incubation period in these black-footed ferrets is that some animals may have had a marginal immune response to CDV stimulated by the inactivated CDV vaccine.

Clinical signs of CD in these black-footed ferrets were somewhat different than those reported for vaccine-induced CD by Carpenter et al. (1976). Severe pruritus was the most striking early sign of disease we observed; however, pruritus was not described as a sign of vaccine-induced CD in black-footed ferrets (Carpenter et al., 1976) and only rarely is described in domestic ferrets (Davidson, 1986). Ocular and nasal discharges are frequently described in domestic ferrets and were reported previously in black-footed ferrets with vaccine-induced CD (Carpenter et al., 1976). Ocular discharge was observed in only one of this group of black-footed ferrets; one of the six animals had a transient serous

nasal discharge early in the course of disease, and one had a mild mucopurulent nasal discharge shortly before death. Pneumonia was observed in all black-footed ferrets with vaccine-induced CD and often is present in domestic ferrets (Budd, 1981). However, one of these six black-footed ferrets had grossly apparent pneumonia and only mild bronchitis and/or interstitial pneumonia were observed microscopically in the other animals. Absence of severe pulmonary disease may have been due to the aggressive antibiotic therapy used in these black-footed ferrets, thereby reducing the opportunity for secondary bacteria-induced pneumonia. Secondary bronchopneumonia is a commonly recognized sequela of CD in many species (Jubb et al., 1985).

Signs of nervous system disease were not observed in five black-footed ferrets and were equivocal in one animal. Nervous signs were observed in all black-footed ferrets with vaccine-induced CD (Carpenter et al., 1976) and are commonly observed in affected domestic ferrets. Occurrence of nervous signs may be related to the strain of CDV (Appel et al., 1981).

Two *Eimeria* spp. were within the intestines of some of the black-footed ferrets with CD. Carpenter and Hillman (1979) reported coccidia in captive black-footed ferrets, but the parasites were not identified. Similar, possibly the same, species of *Eimeria* were described by Hoare (1927) in a colony of domestic ferrets during an outbreak of CD. Intestinal lesions associated with the coccidia were mild in black-footed ferrets and were similar to those described in domestic ferrets (Hoare, 1935). The presence of schizonts of a protozoan parasite in the epithelial cells of the trachea and bronchi is noteworthy as we are not aware of protozoa being reported from this location in mustelids. Systemic infection by this parasite and the proliferation of coccidia and *Giardia* sp. in the intestinal tract may be associated with immunosuppression caused by CDV (Kauffman et al., 1982) as has been observed with *Tox-*

oplasma gondii in other carnivores infected with CDV (Moller and Nielsen, 1964; Diters and Nielsen, 1978).

Hemorrhagic gastroenteritis and colitis were present as terminal events in three of the black-footed ferrets. These lesions are commonly observed in severely stressed mustelids (Wallach and Boever, 1983).

None of the affected black-footed ferrets developed demonstrable serum antibodies to CDV by the time of death even though they had been vaccinated repeatedly with the inactivated CDV vaccine without adjuvant and the same vaccine in adjuvant. This inactivated CDV vaccine has been used in red pandas (*Ailurus fulgens*) which are known to be susceptible to vaccine-induced CD, even though data indicated lack of high virus neutralizing antibody response to the vaccine (Montali et al., 1983). Addition of the adjuvant to the inactivated vaccine resulted in neutralizing antibody titers in six healthy black-footed ferrets after two or three doses of vaccine. Thus, black-footed ferrets are capable of responding with serum antibodies to CDV antigens. It is not known if these antibodies would be protective against CDV challenge.

It is not known how or when CDV was introduced into the free-ranging black-footed ferret colony. Many susceptible species are present at the Meeteetse site, including skunks, raccoons, coyotes, red fox (*Vulpes vulpes*), badgers, weasels (*M. frenata*, *M. ermina*) and occasional ranch dogs. At the time of the CD outbreak in black-footed ferrets there was no evidence of other susceptible species being affected. However, it was later learned that in July 1985 a cowboy observed a disoriented ataxic badger with matted eyelids in close proximity (approximately 2 km) to the black-footed ferret colony. The badger was discarded and not available for postmortem examination. The clinical signs described suggest the badger had CD (Armstrong, 1942; Farrell, 1957). Evidence from the carnivore survey confirms the involvement of badgers and coyotes in the dis-

temper epizootic. These species could have served to amplify and spread the disease into new regions of black-footed ferret habitat. Lack of evidence of CD in skunks, raccoons and weasels may have been due to the small number tested, their use of different habitats and lack of exposure, or high mortality induced by CD in these species. The presence of antibodies to CDV only in adult animals, and lack of evidence of active CD in any animal during the carnivore survey suggests the epizootic did not recur in 1986.

Another source of the disease could have been humans acting as fomites during sylvatic plague control measures. This seems to be an unlikely source due to the fragility of the virus in the environment (Gorham, 1966) and the remote possibility that black-footed ferrets or other susceptible species would have come into direct contact with people or their equipment. All personnel involved with the ferret project were advised not to handle dogs for 24 hr prior to work at Meeteetse or to transport dogs to the site (Thorne et al., 1985a), although it is possible that ranch hands or oilfield workers transported dogs into the area or that feral dogs were present. Extensive precautions were taken by all biologists to avoid introduction of disease when trapping and handling black-footed ferrets for research purposes (Thorne et al., 1985a).

The dynamics of distemper in the colony are not clear. The survey for black-footed ferret litters in July and August 1985 indicated a reduction of approximately 50% compared to the same time in 1984 (Forrest et al., 1988). Estimates of ferret numbers dropped to approximately 16 animals by early October 1985. By late October and early November 1985, only six black-footed ferrets could be found. These were captured in an attempt to obtain animals for captive propagation and to interrupt transmission of disease to remaining black-footed ferrets believed to live in more remote, outlying prairie dog colonies (Thorne, 1987; Thorne, 1988). The presence of a small number of untagged black-

footed ferrets in 1986 in areas known to have been severely affected by CD and where most black-footed ferrets were ear tagged in 1984 and 1985 (Thorne, 1987; Forrest et al., 1988) suggests this was successful. It is possible the black-footed ferrets alive in 1986 occupied outlying prairie dog towns in 1985 and survived the CD epizootic by not being exposed to the virus.

The presence of sylvatic plague in prairie dogs complicated interpretation of black-footed ferret numbers obtained during the summer of 1985. It has been suggested that reduction of the food base due to plague may have reduced the resistance of the black-footed ferrets to CD (May, 1986). However, no ferrets were known to have died directly or indirectly due to the effects of sylvatic plague (Thorne, 1987; Forrest et al., 1988). As prairie dog towns became less active, it is likely that black-footed ferrets moved to adjacent, more active prairie dog towns, rather than stay where prey was less abundant. Nutritional status probably has little influence on the 100% fatality rate of CD in black-footed or domestic ferrets, no more than 20% of the occupied prairie dogs habitat was lost to plague (Forrest et al., 1988), and expansion of prairie dogs into new areas (Belitsky, 1988) may have partially compensated for that loss.

Canine distemper had a severe impact on the captive and wild populations of black-footed ferrets. The disease compromised breeding programs both times these animals were brought into captivity and it continues to be a significant threat to black-footed ferrets now in captivity. Use of the inactivated CD vaccine with adjuvant may provide some protection against the disease and strict isolation procedures may prevent introduction of CD into the captive colony. Once captive propagation of black-footed ferrets is successful, management of CD will be of major importance to reintroduction of the species into the wild.

The historic impact of CD on wild populations of black-footed ferrets is difficult

to assess. The dramatic decline of black-footed ferret numbers at Meeteetse in late summer and fall 1985 was probably due to CD. It seems likely that similar epizootics could have occurred in other free-ranging black-footed ferret colonies in the past. Loss of black-footed ferret habitat due to widespread prairie dog control programs is thought to be largely responsible for the near extinction of the black-footed ferret (Nowak and Paradiso, 1983). It also seems possible that CD has played a significant role in the demise of the black-footed ferret, considering the ubiquity of the virus in domestic and wild species and the extreme susceptibility of black-footed ferrets to the disease.

Continuing attention to preventing and controlling diseases in captive and reintroduced black-footed ferret populations will be necessary to insure survival of the species. The diseases of major concern to managers of black-footed ferrets have been reviewed (Carpenter and Hillman, 1979; Thorne, 1985a) and in addition to CD, include human influenza, Aleutian disease, rabies, and a variety of bacterial and parasitic diseases. An understanding of the diseases of prairie dogs also will be necessary because of the dependency of black-footed ferrets on prairie dogs. Management of disease is of critical importance when populations of animals become small (Dobson and May, 1986) and will continue to be of concern during the recovery of this and other endangered species.

ACKNOWLEDGMENTS

This report was funded in part by the U.S. Fish and Wildlife Service to the Wyoming Game and Fish Department under authority of Section VI of the Endangered Species Act of 1973 and Federal Aid to Wildlife Restoration, Wyoming, Pittman-Robertson Project FW-17-P; the U.S. Fish and Wildlife Service, National Ecology Center, Fort Collins, Colorado; and the Department of Veterinary Sciences, University of Wyoming. We would like to thank N. Kingston and W. Jolley for assistance with parasitology, K. Mills for bacteriology, and J. Yost, I. Johnson, C. Nunamaker, and S. Anderson for technical

assistance. We appreciate also the trapping efforts of J. Hanna and A. McKinney. Fort Dodge Laboratories kindly provided the adjuvant.

LITERATURE CITED

- ANDERSON, S. H., AND D. B. INKLEY. 1985. Black-footed ferret workshop proceedings. Wyoming Game and Fish Department, Cheyenne, Wyoming, 260 pp.
- APPEL, M. J. G., E. P. J. GIBBS, S. J. MARTIN, V. TER MEULEN, B. K. RIMA, J. R. STEPHENSON, AND W. P. TAYLOR. 1981. Morbillivirus diseases of animals and man. In *Comparative diagnosis of viral diseases*, Vol. IV. Vertebrate animal and related viruses, Part B—RNA viruses, E. Kurstak and C. Kurstak (eds.). Academic Press, New York, New York, pp. 259–273.
- , AND J. H. GILLESPIE. 1972. Canine distemper virus. *Virology Monographs* 11: 1–96.
- , AND O. R. JONES. 1967. Use of alveolar macrophages for cultivation of canine distemper virus. *Proceedings of the Society for Experimental Biology and Medicine* 126: 571–574.
- , AND D. S. ROBSON. 1973. A microneutralization test for canine distemper virus. *American Journal of Veterinary Research* 34: 1459–1463.
- ARMSTRONG, W. H. 1942. Canine distemper in the American badger. *Cornell Veterinarian* 32: 447–448.
- BELITSKI, D. W. 1988. Status of free ranging black-footed ferrets at Meeteetse in 1986. In *Conservation biology and the black-footed ferret*, U.S. Seal, E. T. Thorne, M. Bogan and S. H., Anderson (eds.). Yale University Press, New Haven, Connecticut, In press.
- BERNARD S. L., J. R. GORHAM, AND L. M. RYLAND. 1984. Biology and diseases of ferrets. In *Laboratory animal medicine*, J. G. Fox, B. J. Cohen and F. M. Loew (eds.). Academic Press, New York, New York, pp. 385–397.
- BUDD, J. 1981. Distemper. In *Infectious disease of wild mammals*, 2nd ed., J. W. Davis, L. H. Karstad and D. O. Trainer (eds.). The Iowa State University Press, Ames, Iowa, pp. 31–44.
- CARPENTER, J. W., M. J. G. APPEL, R. C. ERICKSON, AND M. N. NOVILLA. 1976. Fatal vaccine-induced canine distemper virus infection in black-footed ferrets. *Journal of the American Veterinary Medical Association* 169: 961–964.
- , AND C. N. HILLMAN. 1979. Husbandry, reproduction, and veterinary care of captive ferrets. 1978 Proceedings of the Annual Meeting of the American Association of Zoo Veterinarians, American Association of Zoo Veterinarians, Washington, D.C., pp. 36–47.
- DAVIDSON, M. 1986. Canine distemper virus infection in the domestic ferret. *Compendium on Continuing Education for the Practicing Veterinarian* 8: 448–453.
- DITERS, R. W., AND S. W. NIELSEN. 1978. Toxoplasmosis, distemper, and herpesvirus infection in a skunk (*Mephitis mephitis*). *Journal of Wildlife Diseases* 14: 132–136.
- DOBSON, A. P., AND R. M. MAY. 1986. Disease and conservation. In *Conservation biology*, M. E. Soule (ed.). Sinauer Associates, Inc. Publishers, Sunderland, Massachusetts, pp. 343–365.
- FARRELL, R. K. 1957. The susceptibility of the American badger to the Green's distemperoid vaccine. *Western Veterinarian* 4: 61.
- FORREST, S. C., D. E. BIGGINS, L. RICHARDSON, T. W. CLARK, T. M. CAMPBELL III, K. A. FAGERSTONE, AND E. T. THORNE. 1988. Population attributes for the black-footed ferret *Mustela nigripes* at Meeteetse, Wyoming, 1981–1985. *Journal of Mammalogy* 69: In press.
- GORHAM, J. R. 1966. The epizootiology of distemper. *Journal of the American Veterinary Medical Association* 149: 610–622.
- HILLMAN, C. N. 1972. A trap for capturing black-footed ferrets. *American Midland Naturalist* 88: 461–462.
- HOARE, C. A. 1927. On the coccidia of the ferret. *Annals of Tropical Medicine and Parasitology* 21: 313–320.
- . 1935. The endogenous development of the coccidia of the ferret, and the histopathological reaction of the infected intestinal villi. *Annals of Tropical Medicine and Parasitology* 29: 111–122.
- JUBB, K. V. F., P. C. KENNEDY, AND N. PALMER. 1985. *Pathology of domestic animals*, 3rd ed., Vol. 2. Academic Press, New York, New York, pp. 198, 476–481.
- KAUFFMAN, C. A., A. G. BERGMAN, AND R. P. O'CONNOR. 1982. Distemper virus infection in ferrets: An animal model of measles-induced immunosuppression. *Clinical and Experimental Immunology* 47: 617–625.
- MAY, R. M. 1986. The cautionary tale of the black-footed ferret. *Nature (London)* 320: 13–14.
- MOLLER, T., AND S. W. NIELSEN. 1964. Toxoplasmosis in distemper-susceptible carnivora. *Pathologia Veterinaria* 1: 189–203.
- MONTALI, R. J., C. R. BARTZ, J. A. TEARE, J. T. ALLEN, M. J. G. APPEL, AND M. BUSH. 1983. Clinical trials with canine distemper vaccines in exotic carnivores. *Journal of the American Veterinary Medical Association* 183: 1163–1167.
- NOWAK, R. M., AND J. L. PARADISO. 1983. *Walker's mammals of the world*, 4th ed., Vol. II. The Johns Hopkins University Press, Baltimore, Maryland, pp. 993–994.
- NUNAMAKER, C. E., AND E. S. WILLIAMS. 1986. TEM as an aid in the rapid diagnosis of canine distemper in wildlife. *Proceedings of the Electron Microscopy Society of America*, Albuquerque, New Mexico, pp. 302–303.
- RYLAND, L. M., AND J. R. GORHAM. 1978. The

- ferret and its diseases. *Journal of the American Veterinary Medical Association* 173: 1154-1158.
- SHEETS, R. G., R. L. LINDER, AND R. B. DAHLGREN. 1972. Food habits of two litters of black-footed ferrets in South Dakota. *American Midland Naturalist* 87: 249-251.
- THORNE, E. T. 1987. Captive propagation of the black-footed ferret in Wyoming. *American Association of Zoological Parks and Aquariums, Regional Conference Proceedings, American Association of Zoological Parks and Aquariums, Colorado Springs, Colorado*, pp. 419-425.
- . 1988. Captive propagation of black-footed ferrets in Wyoming. *In Conservation biology and the black-footed ferret*, U.S. Seal, E. T. Thorne, M. Bogan and S. H. Anderson (eds.). Yale University Press, New Haven, Connecticut, In press.
- , M. H. SCHROEDER, S. C. FORREST, T. M. CAMPBELL III, L. RICHARDSON, D. BIGGINS, L. R. H. HANEURY, D. BELITSKY, AND E. S. WILLIAMS. 1985a. Capture, immobilization and care of black-footed ferrets for research. *In Black-footed ferret workshop proceedings*, S. H. Anderson and D. B. Inkley (eds.). Wyoming Game and Fish Department, Cheyenne, Wyoming, pp. 9.1-9.8.
- , E. S. WILLIAMS, S. L. ANDERSON, AND D. LOCKMAN. 1985b. Diagnosis of diseases in wildlife. Pittman-Robertson Job Completion Report, Project FW-3-R, Work Plan No. 1, Job No. 1W, Wyoming Game and Fish Department, Cheyenne, Wyoming, pp. 1-42.
- UBICO, S. R., G. O. MAUPIN, K. A. FAGERSTONE, AND R. G. MCLEAN. 1988. A plague outbreak in the white-tailed prairie dogs (*Cynomys leucurus*) of Meeteetse, Wyoming. *Journal of Wildlife Diseases* 24: 399-406.
- WALLACH, J. D., AND W. J. BOEVER. 1983. Diseases of exotic animals. W. B. Saunders Company, Philadelphia, Pennsylvania, pp. 522-523.
- WILLIAMS, E. S. 1982. Canine distemper. *In Diseases of wildlife in Wyoming*, 2nd ed., E. T. Thorne, N. Kingston, W. R. Jolley and R. C. Bergstrom (eds.). Wyoming Game and Fish Department, Cheyenne, Wyoming, pp. 10-13.
- WYOMING GAME AND FISH DEPARTMENT. 1987. Strategic plan for the management of black-footed ferrets in Wyoming. Wyoming Game and Fish Department, Cheyenne, Wyoming, 67 pp.

Received for publication 6 January 1987.